

A case series of three cases of Japanese Encephalitis in Aligarh Region: Has the disease taken its tour from east to west UP

Hiba Sami¹, Sadia Hassaan¹, Syed Ghazanfar Ali¹, Adil Raza¹, Islam Ahmad¹, Zeeshan Mustafa¹, Mohd Kashif Ali², Zeeba Zaka-Ur-Rab², Nazish Fatima¹, Haris M Khan¹

¹Viral Research and Diagnostic Laboratory, Department of Microbiology,

²Department of Paediatrics,
Jawaharlal Nehru Medical College,
Aligarh

Correspondence:

Dr. Syed Ghazanfar Ali, Microbiologist, VRDL Lab, JNMCH, AMU
syedmicro72@gmail.com

Abstract

Objective: Japanese encephalitis (JE) virus is a flavivirus that is widespread in Asia and is spread via Culex mosquitoes. It is a member of the Flaviviridae family and is one of the most common viral causes of acute encephalitis syndrome (AES) among known etiological viral encephalitis agents, and it has been linked to significant morbidity, death, and disability. We present three cases of acute encephalitis syndrome brought on by the Japanese Encephalitis virus from an area of India that is typically underreported.

Material and Methods: Three infants presenting with symptoms of AES were included in the study. Diagnosis of Japanese Encephalitis was made using commercial IgM ELISA kit for JE. HSV I & II was also tested by commercial ELISA kits (Calbiotech).

Results: All the three cases presented with abnormal movements and seizures and they all belonged to paediatric age group. They did not have any recent travel history to endemic areas. They were started with empirical and supportive treatment. All the three cases had a unfortunate outcome with mortality on 7th and 9th day of admission.

Conclusion: Given the diverse clinical symptoms of the Japanese encephalitis virus, significant effort should be made to pinpoint the specific causal agent that initiates AES. Despite having little effect on management, vector control and vaccination can stop the spread of the disease to healthy contacts and the general public.

Keywords: JE, Acute Encephalitis Syndrome, Flavivirus.

Introduction

Japanese Encephalitis (JE) is an arbovirus and belong to a family Flaviviridae (1). It is most common cause of epidemic encephalitis in India (2). The vector for this virus is Culex Tritaeniorhynchus and Culex Vishnui and there are various animal host as well. Pigs act as amplifier host, cattle act as mosquito attractants, birds and pigs are reservoir and horse are the only animal which shows the symptoms (3). JE virus was so named because, it was first seen in Japan in 1871 as summer encephalitis epidemics. Man is the dead-end host as there is no man-to-man transmission. It mainly affects children in the age group of less than 15 years and is mostly asymptomatic. It usually resolves within weeks if symptomatic and support for ventilator is not generally needed. Hospitalization is primarily due to neurological symptoms. In India, JE is endemic in 15 states and Gorakhpur district of Uttar Pradesh accounts for largest burden of the disease in the past (4). Between 2010 to 2019, a total of 14,933 cases and 2,230 deaths have been reported (4). The incubation period of the disease is between 5-15 days. No trials on Japanese encephalitis have led to advancements in treatment as of yet though numerous trials on its treatment research are going on (5). We report three JE cases that occurred in 2022 among paediatric patients presenting with abnormal movements and seizures.

CASE REPORT 1

A 9-year-old boy presented with fever for 2 days accompanied by altered sensorium and uncoordinated movement in form of tonic-clonic seizure of all four limbs for which he was brought to the hospital. He did not have any recent travel history. On admission he was febrile with a temperature of 98.9 °C, pulse 100/min, BP 116/74 mmHg and respiratory rate of 20/min. The patient was started on empirical antibiotics and routine blood culture was sent to the bacteriology lab which came out to be negative. The patient did not show any signs of improvement on empirical therapy after 4 days of admission. On 4th day of admission, the patient had 2 episodes of tonic-clonic seizure. His GCS was E1V3M6 (10/15) with bilateral pupil reacting to light. The patient also showed features of raised intra-cranial tension and bilateral papilledema. CECT head was done which was normal. EEG showed evidence of focal epileptiform discharge. His blood sample was sent for HSV and JE ELISA. HSV I & II by ELISA were negative. Serum sample for IgM antibody to JE virus was positive. The patient expired on day 9 of admission.

CASE REPORT 2

A 7-year-old girl presented with complaints of pain abdomen and fever for 8 days. After 6 days she also developed abnormal movement and altered sensorium for which she was brought to the emergency department of our hospital. There was no recent travel history. Patient showed abnormal movements which were tonic-clonic involving all the 4 limbs associated with frothing from mouth, up rolling of eyeballs. On admission she was febrile with a temperature of 101⁰C, pulse 167/min, BP 98/58, RR 30/min. her GCS was E4V1M4 (9/15), pupil mid dilated, sluggishly reactive to light. The patient was shifted to PICU and empirical antibiotics were started. Routine blood culture was sent to the bacteriology laboratory which came out to be negative. Blood samples were also sent for HSV and JE-ELISA. HSV I & II by ELISA on serum sample were negative. Serum sample for IgM antibody to JE virus came out to be positive. The patient did not show any sign of improvement on empirical therapy after 3 days of admission. On 4th day her GCS dropped to E1V1M4 and bilateral pupils were sluggishly reactive to light. Patient developed altered breathing pattern and had to be intubated. The patient showed signs of increased intracranial tension. CECT head was done which showed the following findings: 1. Diffuse effacement of cortical sulci of bilateral cerebral hemisphere, bilateral lateral ventricle and third ventricle shows diffuse cerebral edema. 2. Acute to subacute infarct involving left occipital lobe. 3. Mild leptomeningeal enhancement with mild fuzziness noted along bilateral MCA. The patient expired after 9 days of admission.

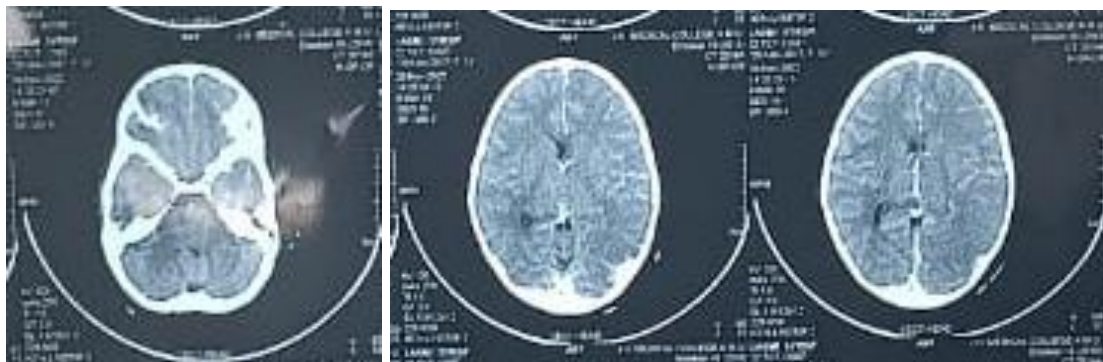


Figure 1: CTCT of Case 2 revealed diffuse effacement of cortical sulci of b/l cerebral hemisphere, b/l lateral ventricle and third ventricle shows diffuse cerebral edema. Mild leptomeningeal enhancement with mild fuzziness noted along b/l MCA

CASE REPORT 3

A 9 months old boy presented to the emergency department with fever, irritability and altered sensorium for last 5 days associated with new onset tonic clonic seizure from last 2 days. There is no recent travel history. On admission he was febrile. The temperature was 102.9⁰F, PR:170/min, BP 105/58 mmHg. Patient was started on empirical antibiotics and routine blood culture was sent to bacteriology lab, which turned out to be negative. The patient did not show any signs of improvement after two days of empirical therapy. On second day of admission, patient has one episode of tonic clonic seizure with respiratory distress. His GCS was E1V3M5 (09/15) and bilateral pupils were reactive to light. Therefore, patient was intubated and shifted to ICU. Serum samples for Herpes Simplex Virus I & II, Dengue IgM antibody and Japanese encephalitis IgM antibody were sent to VRDL laboratory for analysis and IgM antibody to JE virus came out to be positive. The patient was treated conservatively with IV fluid, anti-convulsant and supportive care. On day 7 of admission, the patient expired.

Discussion

JE is a viral zoonotic disease caused by flavivirus, which is an enveloped virus containing ssRNA. Culex mosquito act as vector. Five genotype of the virus have been identified which mainly affect the CNS (6). The transmission cycle is: Aried bird/Pigs → Culex → Aried Bird/Pigs → culex and man is the dead-end host. There is no man → Mosquito cycle (7). About 85% of cases occur in child below 15 years and above 10% cases are seen in elderly population. Infection is more common in rainy season. This may be due to greater breeding of the vectors. Living near paddy fields is also a risk factor for disease transmission (8). In this study we report three cases of Japanese Encephalitis. All our three cases belong to the pediatric age group and they presented in between August to November which is rainy and post rainy season. JE although a big public health burden in eastern Uttar Pradesh has not made any in roads into our western UP area until 2020 when two cases were reported from the same area (9). Majority of cases are asymptomatic in JE and these 3 cases may represent only the tip of the iceberg. The criteria for lab evidence of JE are

positive IgM antibody in a single sample of serum or CSF according to WHO (7). All 3 of our cases had positive IgM antibody in serum for JE. In one of the patients CECT head shows lesions involving cortical sulci, lateral ventricle and occipital lobe. All the three cases presented with fever and seizure which is a common manifestation of the disease (10). As there is no specific antiviral medicine available against JE virus so prevention is best option for the patients (2). Preventive measures include vaccination against JE virus and strict vector control measures. Vaccine for JE started in 2006 in India for age group of 1 – 15 years. Three types of vaccines are available: Cell culture derived inactivated vaccine; Mouse brain derived vaccine; Cell culture live attenuated vaccine (11). The most common strain of JE virus vaccine is formalin inactivated JE strain SA14-14-2 adsorbed to an aluminum hydroxide (0.1%) adjuvant. Two doses of JE vaccine are recommended on day 0 and day 28, with dose: 6 mcg (in 0.5ml), intramuscular route at deltoid region. Adverse complications of JE infection include permanent neurological damage due to the neuro-tropical nature of the virus. Mortality rate is high in case of JE infection, according to global estimates, the mortality burden of JE was 20 thousand deaths in 2011 and 25 thousand in 2015 (12–14). We also report a high mortality rate as all three patients expired in spite of the best efforts from physicians.

Conclusion

Given the diverse clinical symptoms of the Japanese encephalitis virus, significant effort should be made to pinpoint the specific causal agent that initiates AES. Despite having little effect on management, vector control and vaccination can stop the spread of the disease to healthy contacts and the general public.

Acknowledgement

We acknowledge the support of DHR, ICMR in Funding our VRDL. We acknowledge the support of our staff Mrs Shibli Javed, Mr Sanaullah, Mr Samran and Mr Rizwan.

References

1. Lindenbach BD, Rice CM. Molecular biology of flaviviruses. *Adv Virus Res.* 2003;59:23–61.
2. Kulkarni R, Sapkal GN, Kaushal H, Mourya DT. Japanese Encephalitis: A Brief Review on Indian Perspectives. *Open Virol J.* 2018 Aug 31;12:121–30.

3. Walsh MG, Pattanaik A, Vyas N, Saxena D, Webb C, Sawleshwarkar S, et al. High-risk landscapes of Japanese encephalitis virus outbreaks in India converge on wetlands, rain-fed agriculture, wild Ardeidae, and domestic pigs and chickens. *Int J Epidemiol*. 2022 Oct 1;51(5):1408–18.
4. Singh AK, Kharya P, Agarwal V, Singh S, Singh NP, Jain PK, et al. Japanese encephalitis in Uttar Pradesh, India: A situational analysis. *J Fam Med Prim Care*. 2020 Jul;9(7):3716.
5. Ajibowo AO, Ortiz JF, Alli A, Halan T, Kolawole OA. Management of Japanese Encephalitis: A Current Update. *Cureus*. 13(4):e14579.
6. Mackenzie JS, Williams DT, van den Hurk AF, Smith DW, Currie BJ. Japanese Encephalitis Virus: The Emergence of Genotype IV in Australia and Its Potential Endemicity. *Viruses*. 2022 Nov;14(11):2480.
7. Japanese encephalitis [Internet]. [cited 2022 Dec 27]. Available from: <https://www.who.int/news-room/fact-sheets/detail/japanese-encephalitis>
8. Solomon T, Dung NM, Kneen R, Gainsborough M, Vaughn DW, Khanh VT. Japanese encephalitis. *J Neurol Neurosurg Psychiatry*. 2000 Apr 1;68(4):405–15.
9. Sami H, Khan S, Hassan F, Mustafa Z, Ahmad I, Afzal K., et al. Case Reports of Japanese Encephalitis: An Underdiagnosed Entity in An Endemic Region Of Uttar Pradesh, India. *Int J Adv Res*. 2021 Jan 31;9(01):533–6.
10. Turtle L, Solomon T. Japanese encephalitis — the prospects for new treatments. *Nat Rev Neurol*. 2018 May;14(5):298–313.
11. Satchidanandam V. Japanese Encephalitis Vaccines. *Curr Treat Options Infect Dis*. 2020;12(4):375–86.
12. Cheng Y, Tran Minh N, Tran Minh Q, Khandelwal S, Clapham HE. Estimates of Japanese Encephalitis mortality and morbidity: A systematic review and modeling analysis. *PLoS Negl Trop Dis*. 2022 May 25;16(5):e0010361.
13. Campbell GL, Hills SL, Fischer M, Jacobson JA, Hoke CH, Hombach JM, et al. Estimated global incidence of Japanese encephalitis: a systematic review. *Bull World Health Organ*. 2011 Oct 1;89(10):766–74, 774A-774E.
14. Quan TM, Thao TTN, Duy NM, Nhat TM, Clapham H. Estimates of the global burden of Japanese encephalitis and the impact of vaccination from 2000-2015. *eLife*. 2020 May 26;9:e51027.