

## Original Article

# Morpho-histological characteristics of gonads and reproductive index in an endemic fish species, *Oxynoemacheilus persa* (Heckel, 1847) (Teleostei: Nemacheilidae) from Kor River basin, Iran

Soroor Mirghiyasi, Hamid Reza Esmaeili\*, Mohsen Nokhbatolfoghahai

Ichthyology and Developmental Systematics Lab., Department of Biology, College of Sciences, Shiraz University, Shiraz, Iran.

**Abstract:** This study presents the first details on morphological and histological characteristics of gonads, gonadal development stages and reproductive index of the Persian loach, *Oxynoemacheilus persa* (Heckel, 1847), an Iranian endemic species. Sampling was done from April 2010 to April 2011 using electrofishing device and a total of 196 individuals were collected. The gonads of specimens were removed, their sexes determined and then were fixed in 10% formalin solution after checking their morphology and measuring their weights, lengths and widths. Based on the size, shape and weight of the gonads, degree of occupation of the body cavity, presence or absence of ripe oocytes or milt, diameter of the oocytes in the ovary, and histological observations, five stages of sexual maturation in females and four stages in males were determined by macroscopic and microscopic criteria. The results of the gonadal stages showed that the *O. persa* spawns in the middle of spring and these stages were correlated to the gonado-somatic index (GSI).

*Article history:*

Received 8 November 2015

Accepted 19 January 2016

Available online 25 February 2016

*Keywords:*

Reproduction

Gonad morphology

Gonad histology

Sexual maturation

Gonado-somatic index

## Introduction

The order Cypriniformes with 11 family and 4298 species is one of the large order of fishes (Eschmeyer and Fong, 2016). The family Nemacheilidae comprises about 659 species which is the second largest family in the order Cypriniformes (Eschmeyer and Fong, 2016). The nemacheilid fishes are found throughout Eurasia and northeast Africa (Berra, 2001; Nelson, 2006). They are small fishes, live in fast flow hill streams with quite secretive life hiding under stones or in mud. The genus *Oxynoemacheilus* with about 47 species, is a species-rich genus of nemacheilids known from Albania eastwards to Central Iran (Golzaripour et al., 2011; Erk'akan, 2012; Kottelat, 2012; Kamangar et al., 2014; Mafakheri et al., 2015).

The Persian loach, *Oxynoemacheilus persa* (Heckel, 1847) which is generally known as Persian sag mahi (= dog fish), louch (= louch) or mar mahi parsi (= snake fish) in Farsi, is an endemic poorly known loach distributed in endorheic Kor and

exorheic Persis basins in southern Iran (Esmaeili et al., 2010, 2015) and information about different aspects of its biology and ecology including its reproduction is scarce.

Reproductive studies of fishes, such as assessment of size at maturity, duration of the spawning season and fecundity, require knowledge of the state of gonad development and a large number of macroscopic maturity scales in individual fish (Carrasson and Bau, 2003). Although macroscopic staging can enable detailed recording of the seasonal occurrence of different reproductive stages, histological analysis of the gonads can provide a more precise determination. Cellular substructures can be recognized in the growing follicles and ovarian tissue and allow for unambiguous grading and interpretation of reproductive status. Description of the general pattern of histology and development of teleost are given by Wallace and Selman (1981), Tyler and Sumpter (1996), and Tomkiewicz et al. (2003). Since

\* Corresponding author: Hamid Reza Esmaeili  
E-mail address: hresmaeili@shirazu.ac.ir



Figure 1. *Oxynoemacheilus persa*, from Kor River basin, Fars Province.

there is no data available regarding the gonadal morphology and histology of *Oxynoemacheilus persa*, therefore, this study was conducted to presents a detailed description of gonad morpho-histology of this species.

#### Materials and Methods

A total of 196 specimens of *O. persa* (Fig. 1) (81 males and 111 females) were collected monthly from Kor River basin, Fars Province (30°36'16.9" N; 52°56'40.1" E) from April 2010 to April 2011 using electrofishing device. After anesthesia, fish were fixed into 10% formalin in the field, then labeled individually and deposited in the Zoological Museum, Collection of Biology Department, Shiraz University (ZM-CBSU). Some morphological measurements were made using a digital caliper to the nearest 0.01 mm and body weights were determined by a digital balance to the nearest 0.001 g. For histological studies, the specimens were dissected and their ovary or testis were removed. The sexes and stages of sexual maturation were determined as possible as by naked eye examination and under a compound microscope (Olympus). The chi-square test was used to assess deviation from 50:50 sex ratio based on Robards et al. (1999). Weight, length, width, color, and shape of each gonad were recorded and the maturity stage of them was recognized macroscopically based on Nikolsky (1963). The histological sections of ovary or testis of each maturing stages were prepared by routine

histology method (Bancroft and Stevens, 1991; Eagderi et al., 2013) as follow: they dehydrated in alcohol, cleared in xylene, imbedded in paraffin wax at 56°C melting point, sectioned at 5-7  $\mu$ m thickness, and then the sections were stained by Hemotoxylin and Eosin (H&E) staining method. The histological slides were studied under a light compound microscopy and their pictures were taken by a compound microscope equipped to a digital camera.

The gonado-somatic index (GSI) was calculated by dividing the gonads weight by the whole body weight and multiply by 100 (Nikolsky, 1963) to examine the seasonal changes in the gonads for estimating spawning season.

#### Results

**Size range:** A total of 196 individuals of *O. persa* were collected ranging 25.19-78.24 mm (S.D: 12.48) in total length, 24.29-74.22 mm (S.D: 12.02) in fork length, 21.34-66.01 (S.D: 10.55) in standard length and 0.085 to 4.50 g (S.D: 0.90) in total weight.

**Sex ratio:** The collected 81 male and 111 female specimens giving an overall sex ratio of 1M: 1.37F. It was significantly female biased (Chi square =12.629,  $P<0.001$ ).

**Gonado-somatic index:** The results showed that female invest more in gonads than males (ANOVA,  $P<0.001$ ). A significant differences were observed between female and male's gonado-somatic index (ANOVA,  $P<0.05$ ). Both female and male gonado-somatic indices peaked in April showing that

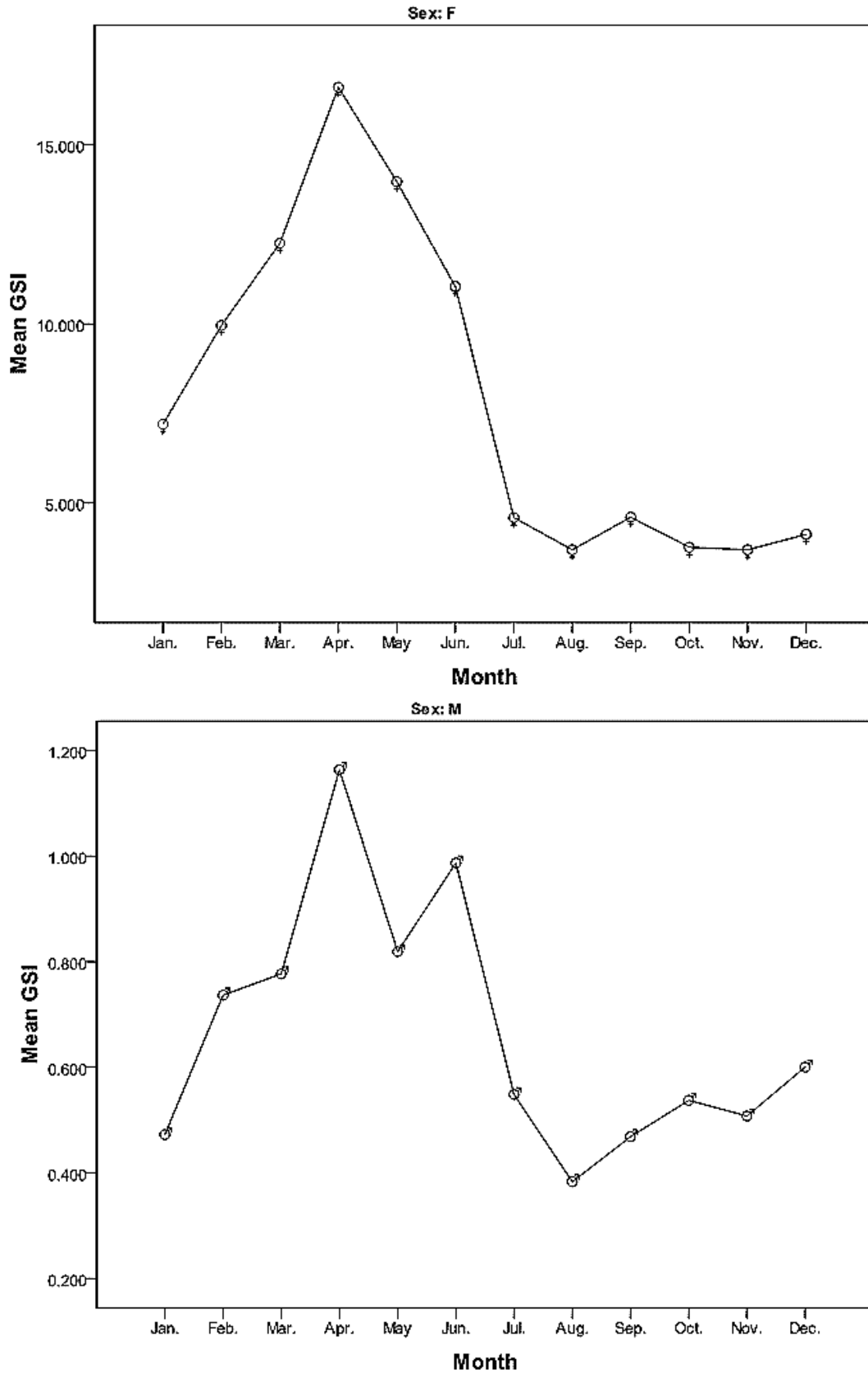


Figure 2. Monthly variation of mean GSI in female and male specimens of *Oxynoemacheilus persa*.

Table 1. Descriptive statistics of gonad measurements in *Oxyneomacheilus persa* (female) from Kor River basin, Fars Province.

Stage	Measurements	N	Minimum	Maximum	Mean	Std. Deviation
2 early	Gonad Weight (g)	19	0.002	0.013	0.00532	0.002868
	Gonad length (mm)	19	5.010	9.600	6.87211	1.150447
	Gonad Width (mm)	19	1.273	2.543	1.74737	0.297476
	GL.ACL (%)	19	44.97	76.49	57.8247	7.54236
2 late	Gonad Weight (g)	39	0.030	0.188	0.06713	0.025999
	Gonad length (mm)	39	10.050	19.380	14.04615	1.932407
	Gonad Width (mm)	39	2.257	5.237	3.18667	.472447
	GL.ACL (%)	39	51.65	78.38	68.9231	5.69150
3	Gonad Weight (g)	14	0.017	0.202	0.10521	0.054044
	Gonad length (mm)	14	10.050	20.170	15.40643	2.931255
	Gonad Width (mm)	14	2.033	4.597	3.67643	.847645
	GL.ACL (%)	14	48.41	96.72	74.6653	13.82134
4	Gonad Weight (g)	18	0.144	0.423	0.24367	0.073964
	Gonad length (mm)	18	13.690	20.880	18.14833	1.783800
	Gonad Width (mm)	18	4.493	6.093	5.14926	.426514
	GL.ACL (%)	18	63.26	99.06	89.9383	9.06568
5	Gonad Weight (g)	21	0.234	0.795	0.42562	0.131349
	Gonad length (mm)	21	18.140	29.190	20.60238	2.261541
	Gonad Width (mm)	21	4.907	10.367	6.70921	1.133205
	GL.ACL (%)	21	79.94	99.43	91.7612	5.21365

GL.ACL: The ratio of gonad length to abdominal cavity length.

*O. persa* spawns in the middle of spring (Fig. 2).

#### **Macroscopic and microscopic characteristics of ovaries:**

The left and right ovaries of *O. persa* were stuck to each other and made an integrated ovary extending along the body cavity in dorsal position above the gut. Based on the size and weight of the ovary, degree of occupation of the body cavity, presence or absence of ripe oocytes, diameter of the oocytes in the ovary, and histological observations, we described 5 maturation stages in the ovary. The stages were classified as immature (Stage I), immature and developing (Stage II, early and late), maturing (Stage III), ripe (Stage IV), spawning (stage V). No specimens of Immature stage were observed and the stage II was divided into two stages: early and late. Gonad measurements of *O. persa* have shown in Tables 1 and 2.

**Ovary maturation stages:** No specimens of Immature stage (I) were observed. In the stage II, early immature, the ovary was small and cream in color.

Oocytes were not visible to the naked eye. The mean diameter of oocytes was 0.073 mm (Fig. 3a). In histological sections of the ovary, small and round oocytes with a large nucleus and abundant nucleoli around the nucleoplasm were observed. No lipid droplets were found in this stage. The oocytes had basophilic cytoplasm and an acidophilic nucleus. The ratio of nucleus to cytoplasm volume was high (Fig. 4a, b). In the developing stage (II, late), the ovary was larger and the oocytes were not visible by naked eye. The mean diameter of oocytes was 0.131 mm (Fig. 3b). In histological observations, the oocyte size increased and the ratio of nucleus to cytoplasm decreased. In larger oocytes, the lipid droplets were formed in the cytoplasm and follicular and theca layers covered each oocyte. In addition, a very thin zona radiata appeared between oolema and follicular layer. The zona radiata was distinguished in two parts: One part as finger-like projections which is placed under the follicular cells and another

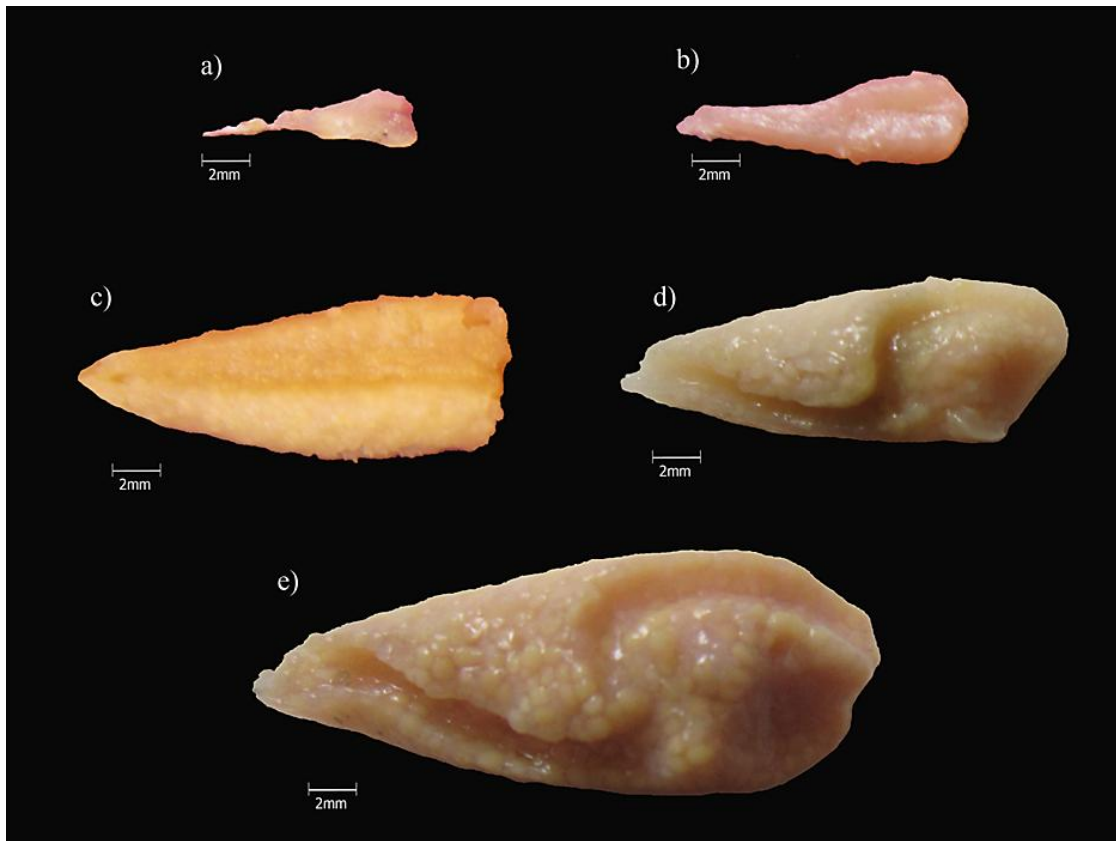


Figure 3. Morphology of ovary of *Oxynoemacheilus persa* in different stages. (a) Immature stage (II, early), (b) Developing stage (II, late), (c) Maturation stage (III), (d) Ripe stage (IV), and (e) Spawning stage (V).

Table 2. Descriptive statistics of gonad measurements in *Oxynoemacheilus persa* (male) from Kor River basin, Fars Province.

Stage	Measurements	N	Minimum	Maximum	Mean	Std. Deviation
1	Gonad Weight (g)	24	0.001	0.002	0.00113	0.000338
	Gonad length (mm)	24	4.28	11.20	6.2642	1.61155
	Gonad Width (mm)	24	0.060	0.302	0.16389	0.055755
	GL.ACL (%)	24	0.92	4.29	2.1816	0.77465
2	Gonad Weight (g)	19	0.001	0.021	0.01011	0.004665
	Gonad length (mm)	19	3.62	11.19	7.3453	2.02354
	Gonad Width (mm)	19	0.413	1.175	0.61404	0.176038
	GL.ACL (%)	18	3.07	9.25	4.4624	1.51573
3	Gonad Weight (g)	18	0.010	0.028	0.01689	0.005075
	Gonad length (mm)	18	6.16	11.85	8.2925	1.32283
	Gonad Width (mm)	18	0.492	0.912	0.65546	0.123627
	GL.ACL (%)	18	3.22	6.45	4.5645	0.89245
4	Gonad Weight (g)	19	0.016	0.070	0.03642	0.014261
	Gonad length (mm)	19	7.73	16.48	11.1745	2.25921
	Gonad Width (mm)	19	0.613	1.158	0.90167	0.168485
	GL.ACL (%)	19	4.08	7.25	5.8294	.96958

GL.ACL: The ratio of gonad length to abdominal cavity length.

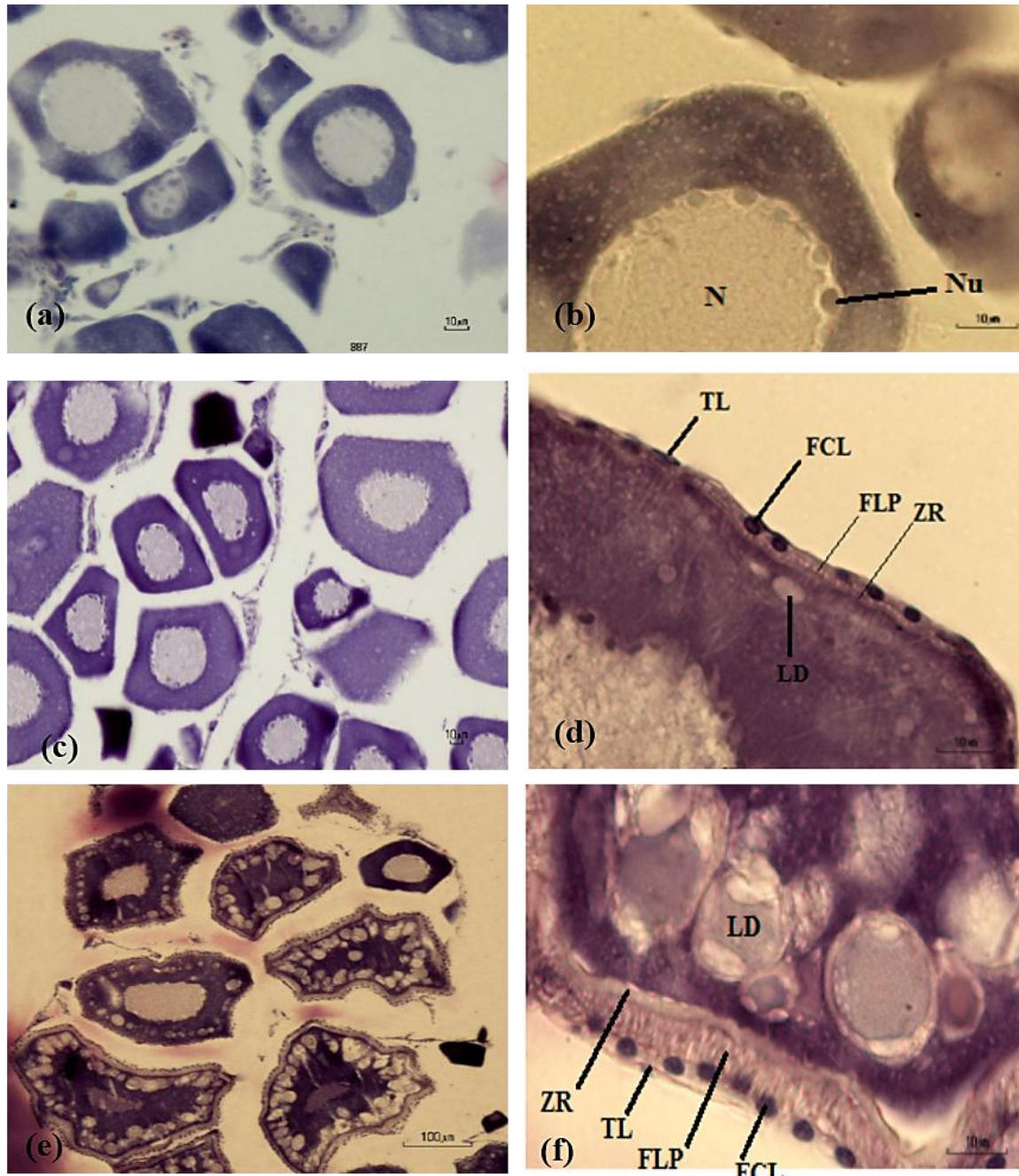


Figure 4. Microphotographs of ovaries of *Oxyoemacheilus persa* in different stages. (a-b) Immature stage (II, early), (c-d) Developing stage (II, late), (e-f) Maturation stage (III), (g-h) Ripe stage (IV), and (i-j) Spawning stage (V). N: Nucleus, Nu: Nucleoli, LD: Lipid Droplets, TL: Theca Layer, FCL: Follicular cell Layer, FLP: Finger-Like Projections, and ZR: Zona Radiata.

uniform thin part on the oocyte membrane. This stage is called returning stage, because after spawning, the ovaries, return to this stage to start oogenesis (Fig. 4c, d). In the third stage i.e. maturing stage, the ovary size was clearly larger than the previous stage and its color changed from cream to light yellow due to accumulation of the yolk materials in the oocytes. Yellow oocytes with an

average diameter of 0.237 mm were visible to the naked eye in this stage (Fig. 3c). The growing oocytes were characterized by small acidophilic yolk granules and many clear lipid droplets that had entirely filled the cytoplasm and also thickened two parts of zona radiata. The finger-like projections were significantly elongated (Fig. 4e, f).

In the ripe stage (IV), the size and weight of

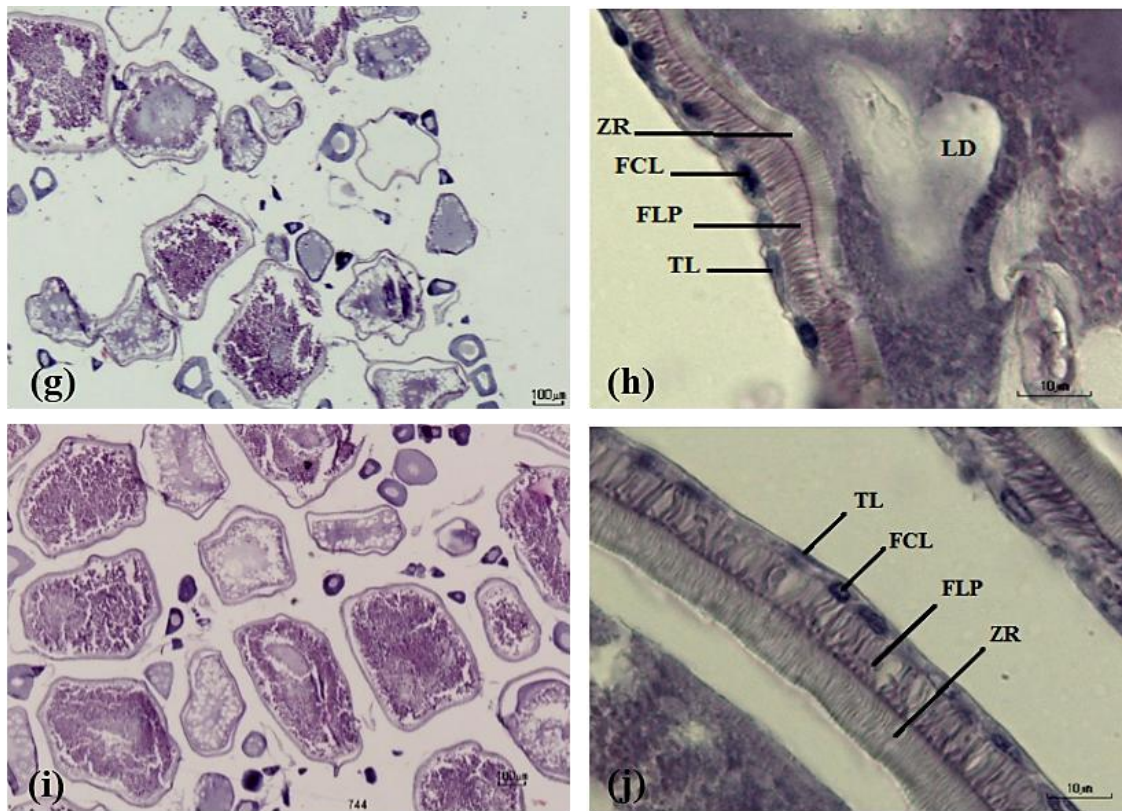


Figure 4. Continued.

gonads increased but had not achieved their maximum size. Their color was yellow, and also they wrinkled a little. The mean of ova diameter was 0.442 mm (Fig. 3d). In this stage, the oocytes are known as follicles. Their size increased and the ratio of nucleus to cytoplasm decreased. The large follicles were full of lipid droplets more than previous stages. Furthermore in this stage, a coalescence of lipids and yolk granules were occurred. The nuclear envelope broke down and the thickness of the zona radiata was higher than previous stages (Fig. 4g, h). In the spawning stage (V), the ovary was yellow and occupied most of the body cavity. It achieved its maximum weight. Large and yellow oocytes, full of yolk with an average diameter of 0.518 mm were distinguishable in this stage (Fig. 3e). Cohesion between oocytes decreased and some of them were observed separately in the body cavity. Oocytes were characterized by large mass of yolk and numerous large lipid droplets. The zona radiata was completely thick in this stage (Fig. 4i, j).

**Testes maturation stages:** Based on macroscopic and

microscopic observations, 4 stages of maturation were distinguished for males of *O. persa*, as follow:  
**Immature stage (I):** The testes were very thin, thread-like and grey in color (Fig. 5a). Spermatogonia were the dominant cells. These cells were the largest spermatogenic cells, with clear cytoplasm and large nucleus. Some primary spermatocytes were also observed (Fig. 6a).

**Developing stage (II):** The size of testes increased (Fig. 5b). Spermatogonia, primary and secondary spermatocytes were more remarkable in the histological sections. Secondary spermatocytes were similar to the primary spermatocytes but smaller (Fig. 6b).

**Maturing stage (III):** The testes were more elongated, flat and milky (Fig. 5c). The number of spermatogonia were significantly reduced. Primary and secondary spermatocytes, and spermatids were observed in the tubules. These cells were located in clusters. Spermatids were smaller than the secondary spermatocytes (Fig. 6c).

**Ripe stage (IV):** Testes were quite milky and massive (Figure 5d). Tubules were characterized by

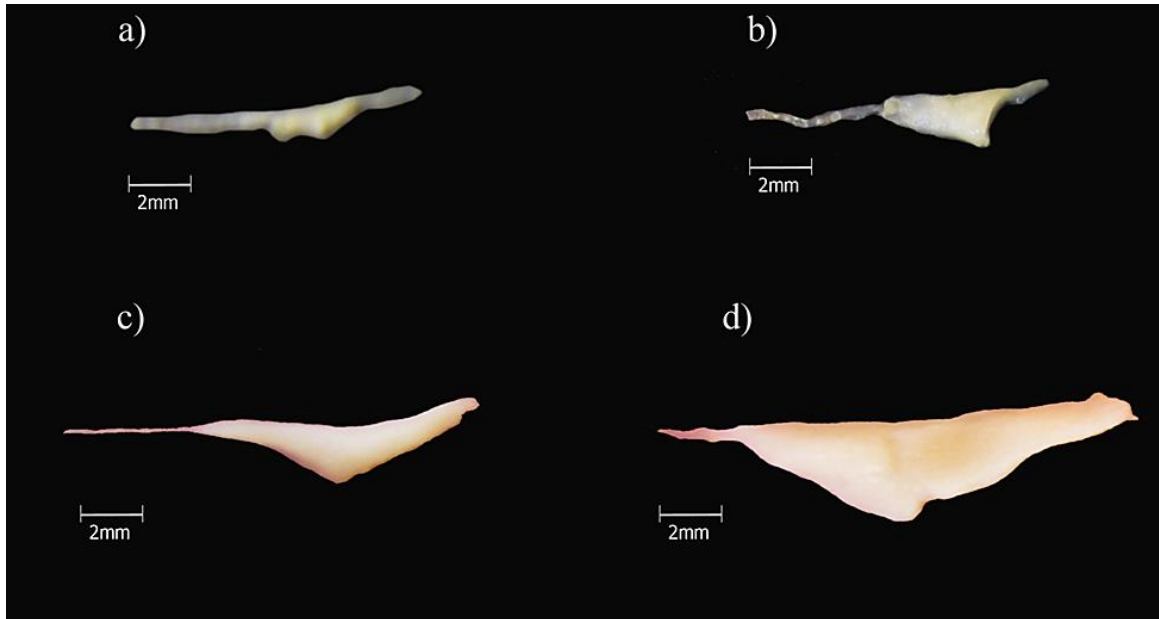


Figure 5. Morphology of testes of *Oxynoemacheilus persa* in different stages. (a) Immature stage (I), (b) Developing stage (II), (c) Maturation stage (III), and (d) Ripe stage (IV).

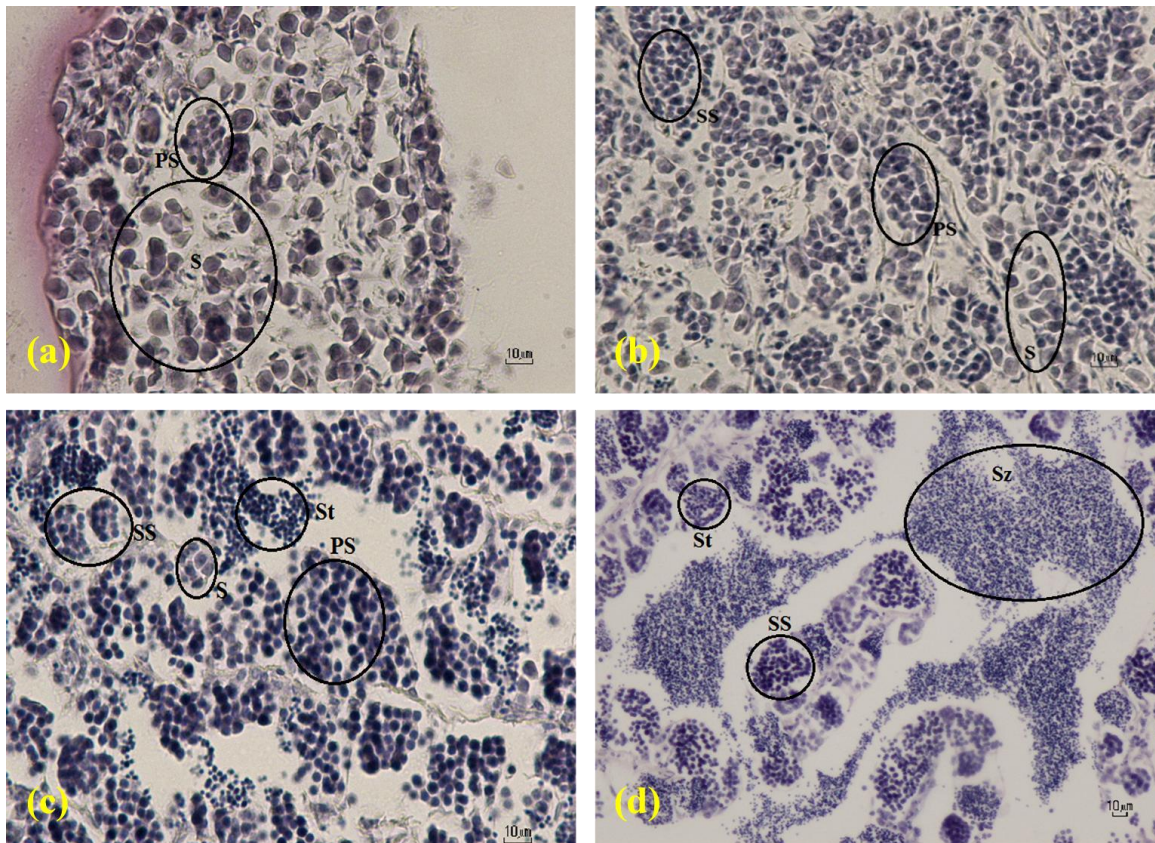


Figure 6. Microphotographs of testes of *Oxynoemacheilus persa* in different stages. (a) Immature stage (I), (b) Developing stage (II), (c) Maturation stage (III), and (d) Ripe stage (IV). S: Spermatogonia, PS: Primary Spermatocytes, SS: Secondary Spermatocytes, St: Spermatids, and Sz: Spermatozoa.

having secondary spermatocytes, large numbers of spermatids and spermatozoa. The predominant cells

were spermatozoa with a dark blue stain related to their nucleus. They were the smallest spermatogenic



cells (Fig. 6d).

### Discussion

This study provided the details on gonad morphology and histology of *O. persa*, an endemic loach species of Iran. *Oxynoemacheilus persa* does not exhibit a clear external sexual dimorphism as found in the cyprinodontid and poeciliid fishes. However, Banarescu and Nalbant (1964) report that pectoral fin rays 2-5 are widened and thickened in males of Persian loach. Also according to Coad (2016), the males have numerous fine tubercles on the dorsal surface of their pectoral fin rays in bands similar to our observations. An unequal sex ratio was observed, which may reflect different survival rates for males and females. It appears that the strategy of this species, in terms of the sex ratio, is the "investment" in females. This is brought about through the selective predation of males or the higher survival rate and greater longevity of females, or the greater endurance of females to environmental stress which is reported in other fish species (see Esmaeili and Shiva, 2006).

The results of the present study showed that *O. persa* spawns in the middle of spring. The mean values of gonado-Somatic index, percentage of late gonad maturation stages (IV, V) and high frequency of large oocytes confirmed the spawning season. The season of spring reported as the spawning season for some other loaches. For example, the gonado-somatic index of *Paracobitis malapterura* indicated that reproduction of this species occurred in April–May (Pattimar et al., 2009). Mousavi-Sabet et al. (2011) also reported the spawning of *Cobitis keyvani* from Talar River occurs from May to late July. The reproductive index of females was higher than males. This matter is justified according to more volume of female's gonad (Mahomoud et al., 2011). This index has been widely used as indicator of the fish spawning season, but its use in reproductive biology studies is more suitable when it is associated with other reproduction indicators such as macroscopic and histological techniques (Ghasemian et al., 2015).

In the present study, based on the size, shape and weight of the gonads, degree of occupation of the body cavity, presence or absence of ripe oocytes or milt, diameter of the oocytes in the ovary, oocyte shape, vitellogenesis, size of oil droplets and yolk vesicles, five stages of ovary development and four stages of testis development were observed. Many studies have been performed on histological and morphological changes of ovary in fishes (Biswas, 1993). Generally, the process of teleost oogenesis may be divided into 5-8 stages (West, 1990; Fishelson et al., 1996; Ünver and Ünver-Saraydin, 2004). The results of the histological study of gonad development in *O. persa* is basically similar to other teleost. The process of oogenesis has been divided into 5 stages which resemble many species such as *Aphanius farsicus* (Monsefi et al., 2007). The testes development process of *O. persa* revealed 4 sexual stages corresponding to *A. farsicus* and *Cyprinus carpio*.

The oocyte reaches maximum size of 1.11 mm in *O. persa*, this is directly found that the nutritional state of the fish affects the vitellogenic and maturation of oocyte because there is a close relationship between the vitellogenesis and oocyte size (Wallace and Selman, 1978). The ecological factors, such as temperature, photoperiod and nutrition are important environmental factors for regulations of reproductive pattern in most teleost (De Vlaming, 1972).

As conclusion, the Persian loach, *O. persa* demonstrates some reproductive strategies, including significantly female biased sex ratio, little sexual dimorphism and spring spawning in response to its habitat. The small body size is another significant factor in the life history of *O. persa* which allows this loach to colonise and exploit microenvironments. However, the limited distribution makes the species highly vulnerable and could result in significant loss if habitats are disturbed or destroyed. The provided information in this study on the sex ratio, reproductive index and maturation process of Persian loach contribute baseline data towards management ecology,

conservation and biological studies of this fish.

### Acknowledgments

We are thankful to S. Ghasemian, S. Babai and R. Zamaniannejad for their kind help in fish collection and Shiraz University for financial support.

### References

- Banarescu P., Nalbant T. (1964). Süßwasserfische der Türkei. 2. Teil Cobitidae. Mitteilun genau demham burgischen Zoologischen Museum und Institut, 61: 159-201.
- Bancroft J.D., Stevens A. (1990). Theory and practice of histological techniques. Churchill Living stone, New York. 800 p.
- Berra T.M. (2001). Freshwater fish distribution. Academic Press, Santiago, San Francisco, New York, Boston, London, Sydney, Tokyo. 604 p.
- Biswass S.P. (1993). Manual of methods in fish biology. International book Co. Absecon Highlands, Delhi, India. 666 p.
- Carrasson M., Bau M. (2003). Reproduction and gonad histology of *Aidablennius sphyinx* (Pisces: Blenniidae) of the Catalan Sea (Northwestern Mediterranean). Scientia Marina, 67: 461-469.
- Coad B.W., (2016). Freshwater Fishes of Iran. ([www.briancoad.com](http://www.briancoad.com)). Retrieve 1 December 2015.
- De Vlaming V.L. (1972). Environmental control of teleost reproductive cycles: A brief review. Journal of Fish Biology, 4: 131-140.
- Eagderi S., Mojazi Amiri B., Adriaens D. (2013). Description of the ovarian follicle maturation of the migratory adult female bulatmai barbel (*Luciobarbus capito*, Gldenstdt 1772) in captivity. Iranian Journal of Fisheries Sciences, 12(3): 550-560
- Erk'akan F. (2012). Two new *Oxynoemacheilus* (Teleostei: Nemacheilidae) species from Western Turkey. Research Journal of Biological Sciences, 7 (2): 97-101.
- Eschmeyer W.N., Fong J.D. (2016). Species by family/subfamily. (<http://researcharchive.calacademy.org/research/ichthyology/catalog/SpeciesByFamily.asp>). Electronic version accessed 07 March 2016.
- Esmaeili H.R., Shiva A.H. (2006). Reproductive biology of Persian tooth-carp, *Aphanius persicus* (Jenkins, 1910) (Actinopterygii: Cyprinodontidae) in South of Iran. Zoology in the Middle East, 37: 39-46.
- Esmaeili H.R., Coad B.W., Gholamifard A., Nazari N., Teimory A. (2010). An notated checklist of the freshwater fishes of Iran. Zoosystematica Rossica, 19(2): 361-386.
- Esmaeili H.R., Babai S., Gholamifard A., Pazira A., Gholamhosseini A., Coad B.W. (2015). Fishes of the Persis region of Iran: an updated checklist and ichthyogeography. Iranian Journal Ichthyology, 2(3): 201-223.
- Ghasemian S., Esmaeili H.R., Nokhbatolfoghahai M., Pazira A. (2015). A histo-morphological characteristics of gonads in Mudskipper, *Periophthalmus waltoni* Koumans, 1941 from Helleh estuary, Southwestern Iran. International Journal of Aquatic Biology, 2(6): 379-389.
- Golzarianpour K., Abdoli, A., Freyhof J. (2011). *Oxynoemacheilus kiabii*, a new loach from Karkheh River drainage, Iran (Teleostei: Nemacheilidae). Ichthyological Exploration of Freshwaters, 22 (3): 201-208.
- Kamangar B.B., Prokofiev A.M., Ghaderi E., Nalbant T.T. (2014). Stone loaches of Choman River system, Kurdistan, Iran (Teleostei: Cypriniformes: Nemacheilidae). Zootaxa, 3755(1): 33-61.
- Kottelat M. (2012). Conspectus cobitidum: an inventory of the loaches of the world (Teleostei: Cypriniformes: Cobitoidei). The Raffles Bulletin of Zoology, 26: 1-199.
- Mafakheri P., Eagderi S., Farahmand H., Mousavi-Sabet H. (2015). Osteological structure of Kiabi loach, *Oxynoemacheilus kiabii* (Actinopterygii: Nemacheilidae). Iranian Journal of Ichthyology, 1(3), 197-205
- Monsefi M., Shiva A.H., Esmaeili H.R. (2007). Gonad Histology of the Persian Tooth-carp *Aphanius persicus* (Jenkins, 1910) (Cyprinodontidae) in Southern Iran. Turkish Journal of Zoology, 33: 27-33
- Mousavi-Sabet H., Kamali A., Soltani M., Bani A., Esmaeili H.R., Khoshbavar Rostami H., Vatandoust S., Moradkhani Z. (2011). Reproductive biology of *Cobitis keyvani* (Cobitidae) from the Talar River in the southern Caspian Sea basin. Iranian Journal of Fisheries Sciences, 11(2): 383-393.
- Nelson J.S. (2006). Fishes of the World. New York: John Wiley and Sons. 624 p.
- Nikolsky G.V. (1963). The Ecology of Fishes, Academic Press, New York. 352 p.
- Patimar R., Adineh H., Mahdavi M.J. (2009). Life history

- of the Western Crested Loach *Paracobitis malapterura* in the Zarrin-Gol River, East of the Elburz Mountains (Northern Iran). *Biologia*, 64(2): 350-355.
- Robards M.D, Piatt J.F, Rose G.A (1999). Maturation, fecundity and intertidal spawning of pacific and lance in the northern gulf of Alaska. *Journal of Fish Biology*, 54: 1050-1068
- Tomkiewicz J., Tybjerg L., Jespersen A. (2003). Micro and macroscopic characteristics to stage gonadal maturation of female Baltic Cod. *Journal of Fish Biology*, 62: 253-275.
- Tyler C.R., Sumpter J.P., (1996). Oocyte growth and development in teleosts. *Reviews in Fish Biology and Fisheries*, 6: 287-318.
- Unver B., Unver-Saraydin S. (2004). Histological examination of ovarium development of shemaya *Chalcalburnus chalcoides* living in Lake Tödürge (Sivas/Turkey). *Folia Zoology*, 53(1): 99-106.
- Wallace R.A., Selman K. (1978). Oogenesis in *Fundulus sheteroclitus* I. Preliminary observations on oocyte maturation in vivo and in vitro. *Developmental Biology*, 62: 354-369.
- Wallace R.A., Selman K. (1981). Cellular and dynamic aspects of oocyte growth in teleosts. *American Zoologist*, 21: 325-343.
- West G. (1990). Methods of assessing ovarian development in fishes: a Review. *Australian Journal of Marine and Freshwater Research*, 41: 199-222.

## چکیده فارسی

### ویژگی‌های ریختی-بافتی گنادها و نمایه تولیدمثلی در لوچ ماهی پارسی *Oxynoemacheilus persa* (Heckel, 1847)، (ماهیان استخوانی عالی: لوچ ماهیان جویباری بدون خار) از حوضه رودخانه کر، ایران

سرور میرغیاثی، حمیدرضا اسماعیلی\*، محسن نخبه الفقهایی

آزمایشگاه ماهی‌شناسی و سیستماتیک تکوینی، بخش زیست‌شناسی، دانشکده علوم، دانشگاه شیراز، شیراز، ایران.

#### چکیده:

در این مطالعه، ویژگی‌های ریختی-بافتی، نمایه تولیدمثلی و مراحل بلوغ جنسی گنادهای نر و ماده لوچ ماهی پارسی *Oxynoemacheilus persa* (Heckel, 1847)، یک گونه بومزاد ایران، ارائه گردیده است. نمونه‌برداری از ماه آوریل ۲۰۱۰ تا آوریل ۲۰۱۱، به وسیله صید الکتریکی انجام و در کل تعداد ۱۹۶ قطعه ماهی جمع‌آوری گردید. گنادها از بدن خارج، تعیین جنسیت گردیده و پس از بررسی ریختی، اندازه‌گیری وزن، طول و عرض آن‌ها، در محلول فرمالین ۱۰ درصد تثبیت و با استفاده از روش معمول رنگ‌آمیزی هماتوکسیلین و ائوزین، مقاطع بافت‌شناسی آماده گردید. بر اساس اندازه، شکل و وزن گنادها، اندازه گناد نسبت به طول حفره شکمی، وجود و یا عدم وجود تخمک در گناد ماده و یا مایع شیری رنگ میل‌ت در گناد نر، قطر تخمک در تخمدان و مشاهدات بافت‌شناسی، ۵ مرحله بلوغ جنسی برای ماده‌ها و ۴ مرحله برای نرها منظور گردید. نتایج بررسی مراحل بلوغ جنسی گنادهای نر و ماده لوچ ماهی پارسی نشان داد که این ماهی در میانه بهار تخم‌ریزی نموده و مراحل بلوغ جنسی با میزان میانه گنادی-بدنی مرتبط است.

**کلمات کلیدی:** تولیدمثلی، ریخت‌شناسی گناد، بافت‌شناسی گناد، بلوغ جنسی، نمایه گنادی-بدنی.