



eISSN 2282-2054

<https://www.pagepressjournals.org/index.php/ecj/index>

**Publisher's Disclaimer.** E-publishing ahead of print is increasingly important for the rapid dissemination of science. The **Early Access** service lets users access peer-reviewed articles well before print / regular issue publication, significantly reducing the time it takes for critical findings to reach the research community.

These articles are searchable and citable by their DOI (Digital Object Identifier).

The **Emergency Care Journal** is, therefore, e-publishing PDF files of an early version of manuscripts that undergone a regular peer review and have been accepted for publication, but have not been through the typesetting, pagination and proofreading processes, which may lead to differences between this version and the final one.

The final version of the manuscript will then appear on a regular issue of the journal.

E-publishing of this PDF file has been approved by the authors.

Emerg care J 2023 [Online ahead of print]

*To cite this Article:*

Triggia I, Poggiali E. **What lies beneath a maggot infestation of an ulcerated foot wound?**. *Emerg Care J* doi: 10.4081/ecj.2023.10353

 ©The Author(s), 2023

Licensee [PAGEPress](#), Italy

Note: The publisher is not responsible for the content or functionality of any supporting information supplied by the authors. Any queries should be directed to the corresponding author for the article.

All claims expressed in this article are solely those of the authors and do not necessarily represent those of their affiliated organizations, or those of the publisher, the editors and the reviewers. Any product that may be evaluated in this article or claim that may be made by its manufacturer is not guaranteed or endorsed by the publisher.

## **What lies beneath a maggot infestation of an ulcerated foot wound?**

Irene Triggia, Erika Poggiali

Emergency Department, Guglielmo da Saliceto Hospital, Piacenza, Italy

**Correspondence:** Erika Poggiali, Emergency Department, “Guglielmo da Saliceto” Hospital, Via Giuseppe Taverna 49, Piacenza, Italy.

Tel.: +39.0523.303044

E-mail: [poggiali.erika@gmail.com](mailto:poggiali.erika@gmail.com)

**Key words:** skin lesions, neoplastic ulcer, squamous cell carcinoma, foot lesions, myiasis.

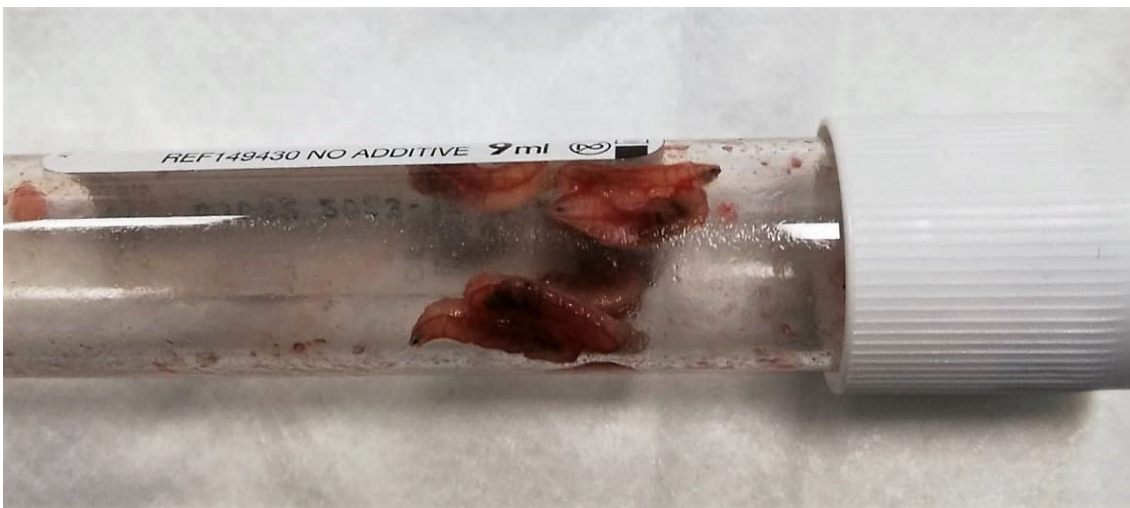
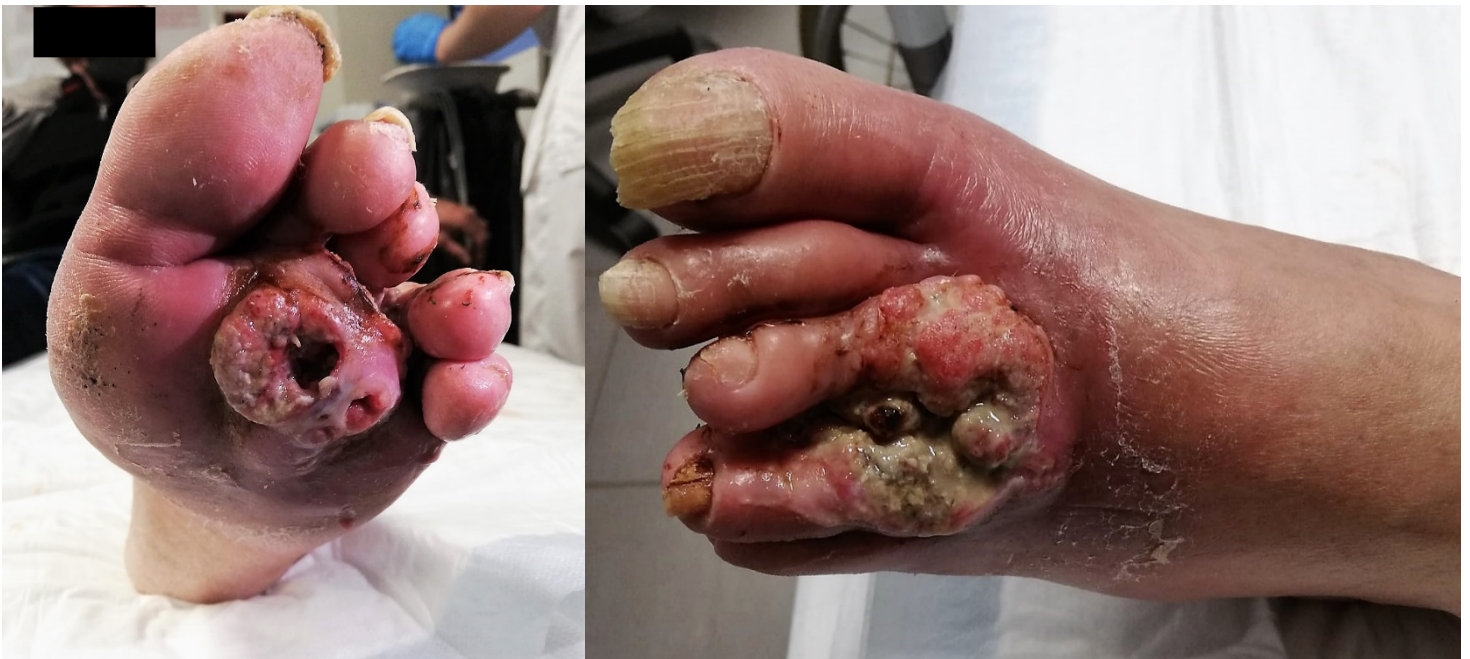**Contributions:** Both the authors cared for the patient, collected details of the case, drafted the manuscript, approved the final version and stated the integrity of the whole work.

**Conflicts of interest:** EP is member of the editorial board of Emergency Care Journal. The other author declares no potential conflict of interest, and all authors confirm accuracy.

**Availability of data and materials:** All data underlying the findings are fully available upon reasonable request to Erika Poggiali, [E.Poggiali@ausl.pc.it](mailto:E.Poggiali@ausl.pc.it).

**Ethics approval and consent to participate:** As this was a descriptive case report and data was collected without patient identifiers, ethics approval was not required under our hospital's Institutional Review Board guidelines.

**Informed consent:** The patient provided consent for the access to medical records at the time of admission.



## **Descriptive legend**

We present here the case of a 55-year-old male patient with a past medical history of HIV infection on appropriate antiretroviral therapy (Bictegravir/Emtricitabine/Tenofovir Alafenamide), previously treated for hepatitis C with sustained viral response, who was diagnosed with squamous cell cancer of his right hand 2 years before, and treated with carboplatin and taxol, and surgery (partial amputation) for cancer progression and recurrent infections. He presented to our emergency department for worsening pain (NRS 10/10) of a suppurative and foul-smelling interdigital ulcerated lesion of his left foot, that had been present for 3 months. He reported 100% adherence to his HIV therapy and denied fever or chills. Initial work-up showed 10,690/mm<sup>3</sup> leukocytes (8,240/mm<sup>3</sup> neutrophils, 1,560/mm<sup>3</sup> lymphocytes), and a C-reactive protein of 2.89 mg/dL (normal value 0-0.5). CD4 count on presentation was 225 cells/ $\mu$ L. The patient was immediately treated with morphine (10 mg iv) and piperacillin/tazobactam (4.5 gr iv). The lesion presented erythematous ulcerated bleeding surface with serous and fetid secretion on which mobile larvae were found inside (as showed in the video). We removed about 20 maggots with blunt pliers, identified as larvae of *Musca domestica* (housefly).

**Question:** Given the patient's history, what is the most likely diagnosis?

1. Marjolin's ulcer
2. Diabetic foot ulcer
3. Infected neoplastic ulcer
4. Kaposi sarcoma

## Answer

The patient was admitted to the Infectious Disease Unit and was treated with ivermectin 12 mg was given orally in a single dose with complete cure of the myiasis. A broad-spectrum intravenous antibiotics, which included Linezolid, ciprofloxacin and metronidazole, were infused for a total of 3 weeks, without improvement. A skin biopsy was done, and it revealed well-differentiated squamous cell carcinoma (SCC). After a combined oncological and orthopaedic consultation, he underwent surgical amputation of the foot. The final diagnosis was skin myiasis in ulcerated SCC of the left foot.

Myiasis is an ectoparasitic infestation by *Diptera larvae* of higher flies of the genus Dermatobia. It can be a complication of malignant lesions, particularly those affecting the head and neck;<sup>1,2</sup> of these, epidermoid carcinoma is one of the most frequently associated with this complication, particularly in patients with large, ulcerated, and necrotic SCC.<sup>3,5</sup> Female flies have a strong visual and olfactory attraction to blood and decaying tissue, particularly tumour cell metabolites, which may explain the propensity of ulcerated malignant tumours to be parasitized. The goal of treatment is to mechanically remove with forceps all larvae to avoid deep invasion and bleeding. To date, no treatment guidelines for wound myiasis exist. Patel *et al.* recommend using ivermectin, albendazole, and clindamycin to eradicate the infestation.<sup>6</sup> Large, ulcerated, necrotic, myiasis-burdened SCC lesions in the head and neck area still remain a challenge for treatment, particularly in patients with aggressive malignancies in the hospice and palliative medicine settings.<sup>7</sup> Grinblat *et al.* proposed a four-pillar protocol to rapidly improve wound condition through disinfection, pain relief, and malodour and discharge eradication as a bridge to surgery.<sup>8</sup>

## References

1. Villwock JA, Harris TM. Head and neck myiasis, cutaneous malignancy, and infection: A case series and review of the literature. *J Emerg Med* 2014;47:e37–41.
2. Kondoh A, Ota M, Tokuyama M, et al. Case of Wound Myiasis in a Squamous Cell Carcinoma Lesion of the Scalp. *Tokai J Exp Clin Med* 2022;47:44-6.
3. Fukaura R, Terashima-Murase C, Mori S, et al. Myiasis on a spindle cell squamous cell carcinoma: A scanning electron microscope observation of *Lucilia sericata* larvae [online ahead of print]. *J Dermatol* 2023;10.1111/1346-8138.16833.
4. Gonçalves KKN, de Araújo ESM, Barbirato DS, et al. Head and neck cancer associated with myiasis. *Int J Oral Maxillofac Surg* 2022;51:847-53.
5. Jain A. Myiasis in patients with oral squamous cell carcinoma-a systematic review and protocol for management. *Oral Maxillofac Surg* 2019;23:265-9.
6. Patel BC, Ostwal S, Sanghavi PR, et al. Management of Malignant Wound Myiasis with Ivermectin, Albendazole, and Clindamycin (Triple Therapy) in Advanced Head-and-Neck Cancer Patients: A Prospective Observational Study. *Indian J Palliat Care* 2018;24:459-64.
7. Waidyaratne G, Zhou S, O'Neil T, Marks A. Management of Wound Myiasis in the Hospice and Palliative Medicine Setting. *J Palliat Med* 2021;24:797-800.
8. Grinblat G, Frenkel Y, Shochat I, et al. Myiasis in Neglected Cutaneous Squamous Cell Carcinoma of the Head and Neck: Review of Management and Current Protocol Recommendations. *Adv Skin Wound Care* 2021;34:372-8.

Submitted: 02-06-2023

Accepted: 20-06-2023

Early access publication: 11-06-2023