



## RESEARCH ARTICLE

# Green Synthesis of Gold Nanoparticles Using *Zingiber Officinale* Rhizomes Aqueous Extract and its Gastroprotective Activity against Ethanol-Produced Stomach Ulcer in Rats

Suhayla H. Shareef<sup>1,2</sup>, Ismail N. Mahdi<sup>3</sup>, Mustafa A. Badeea<sup>3</sup>, Mahmood A. Abdulla<sup>3</sup>

<sup>1</sup>Department of Biology, College of Education, Salahaddin University, Erbil 44001, Kurdistan Region, Iraq, <sup>2</sup>Department of Medical Biochemical Analysis, College of Health Technology, Cihan University, Erbil, Kurdistan Region, Iraq, <sup>3</sup>Department of Medical Microbiology, College of Science, Cihan University, Erbil, Kurdistan Region, Iraq

## ABSTRACT

Synthesis of gold nanoparticles exhibition wide range of bioactivities and was conventionally used for the remedy of numerous disorders. Our study aims to measure the gastroprotective effect of synthesized gold nanoparticles on absolute ethanol-induced stomach ulceration in rats. The rats were noticeably administered with two doses of gold nanoparticles (175 ppm and 350 ppm) with absolute alcohol and showed a significant improvement in the adverse effect of ethanol-produced stomach damage as confirmed by decreasing ulcer index and raising % of ulcer prevention. Increased mucus pH of stomach content reduced ulcerated portion, condensed or nonappearance of edema, and white blood cells permeation subcutaneous layer. In gastric tissue homogenate, synthesized gold nanoparticles presented a substantial increase in superoxide dismutase (SOD), catalase (CAT) actions, and a substantial lessening of malondialdehyde (MDA) amount. Besides, gold nanoparticle increases the intensity of periodic acid Schiff stained (PAS) of the gastric epithelium of the stomach. Gold nanoparticles confirmed gastro-protective effects which might be qualified to its antioxidant, increase mucus secretion, increase endogenous enzymes (SOD and CAT), and reduce MDA quantity.

**Keywords:** Synthesized *Zingiber officinale*, gold nanoparticle, gastric ulcer, histology, PAS

## INTRODUCTION

Peptic ulcer is the most communal gastrointestinal tract ailment that is moving a huge number of individuals universally and has therapeutic and worldwide financial attention. Several factors are included in the progress of stomach ulceration, for instance, stress, smoking, malnutrition, administration of nonsteroidal anti-inflammatory medications, genetic tendency, and contagion by *H. pylori*.<sup>[1]</sup> Even though there are, countless medications presently used in the scientific arena to achieve stomach ulcer illness, the mainstream of them displays numerous adversative responses. Therefore, there is necessary to notice additional active and fewer poisonous antiulcer mediators.<sup>[2]</sup> The great attention to herbal medications and the pharmacologic actions of their bioactive composites has given rise to the detection of abundant usual medicines or herbal excerpts.<sup>[3]</sup> In specific, a huge quantity of therapeutic plants established anti-ulcer possessions,<sup>[4]</sup> with fairly a smaller amount cost and an extensive variety of protection boundaries.<sup>[5]</sup>

Zingiberaceae plant family furthermost plentiful in Southeast Asia, extensively utilized outdated remedies.<sup>[6]</sup> *Zingiber officinale* is one of the Zingiberaceae species, categorized

by its important financial consequence; meanwhile, it is used as a flavor and as a traditional medication.<sup>[7]</sup> The rhizomes are prevalent in numerous humid nations. The rhizomes have been exhaustively deliberate and found to display an extensive variety of pharmacologic actions for instance febrifuge, painkilling belongings, anti-inflammatory, chemo-preventive actions,<sup>[8]</sup> antinociceptive, antioxidant, antineoplastic, antimicrobial, antihyperglycemic, antiallergic, and antiplatelet actions.<sup>[9]</sup> The purpose of the current study is to make stable gold nanoparticles and to observe their gastroprotective significance in ethanol-produced stomach ulceration in rats.

### Corresponding Author:

Suhayla H. Shareef, Department of Medical Biochemical Analysis, College of Health Technology, Cihan University- Erbil, Kurdistan Region, Iraq.  
E-mail: suhayla.shareef@cihanuniversity.edu.iq

**Received:** June 19, 2022

**Accepted:** July 30, 2022

**Published:** August 22, 2022

**DOI:** 10.24086/cuesj.v6n2y2022.pp68-75

Copyright © 2022 Suhayla H. Shareef, Ismail N. Mahdi, Mustafa A. Badeea, Mahmood A. Abdulla. This is an open-access article distributed under the Creative Commons Attribution License (CC BY-NC-ND 4.0)

## MATERIALS AND METHODS

UV-Vis's fascination ranges were established on UV-VIS Spectroscopic analysis, whereas the size and shape of elements were quantified on Scanning Electron Microscope (SEM), and Atomic Force Microscopic (AFM). Reliability elements recognized by Zeta Analyzer. Crystallography construction decided samples regulate utilizing high-resolution X-ray diffractometric system JDX-3532 utilizing one-color Cu-K $\alpha$  radiation wavelength 1.5418  $\text{\AA}$ .

### Chemicals and Reagents

Reagents and chemicals were of the analytical score. Gold nitrate crystal was purchased from Merck in Germany; *Zingiber officinale* rhizome and Arabic gum were obtained from the local market. Omeprazole was purchased from a dispensary dissolved in 10% Tween 20 forced feeding by mouth to rats at a dosage of 20 mg/kg (5 mL/kg), as recommended by several investigators.<sup>[10-12]</sup> Omeprazole was purchased from the pharmacy, ketamine, and xylazine and was purchased from a veterinary clinic.

### Preparation of Rhizome Extract

Fresh *Zingiber officinale* rhizomes were gathered and documented by the Herbarium of Biology Department, University of Salahaddin-Erbil (No ERB 8513. The rhizomes were cleaned carefully with distilled water many times to remove the dirt, cut into small pieces, and desiccated under shadow at room temperature for 2 weeks.<sup>[13]</sup> Dry rhizomes make well as ash using an electrical mixer. The ash saturated distilled water (200 g/1000 mL) for 5 days and mixed every 3 h and was filtered using sieve paper and rotating evaporator. Finally, prepared aqueous extract solution stored at  $-20^{\circ}\text{C}$ . Arabic gum (0.15 g) additional to 50 mL purified water  $70^{\circ}\text{C}$  in 100 ml Pyrex mug. This solution supplementary aqueous excerpt *Zingiber officinale* rhizomes through rousing by a magnetic stirrer.

### Synthesis of Gold Nanoparticles

A mix of *Zingiber officinale* extracts besides Arabic gum is located in a 250 mL bottle fiery  $60-70^{\circ}\text{C}$ . pH mixture accustomed 7.5. After that, 50 mL of 1mM gold nitrate solution additional slowly with rousing. The color of the solution changed from a straight line to violet suggesting the progress of gold nanoparticles. The response was appropriated for 20 min, later, the hotplate detached solution persevered rousing till grasped  $25^{\circ}\text{C}$ . Color violet no alteration later four months.

### Ethics Statement

This training was accessible official ethical assessment panel for endorsement, an agreement approved (Ethical number BIO/25/03/2021/MAA). Entirely *in vivo* investigational techniques were achieved in the sterilized state in the Tentative Animal Unit succeeding their strategies. Altogether rats acknowledged humane attention, conferring to the principles delineated "Director Care and Utilize Workroom Animals" ready Nationwide Conservatory Disciplines Available Countrywide Organization Healthiness.

### Initiation of Stomach Ulceration

Rats reserved individually distinct pens widespread net wire bottom evade coprophagia. Rodents fed normal pellets food permit allowed water admission. Investigational animals separate randomly into four collections of six animals correspondingly. Rats reserved in Animal house for 2 weeks for variation. Immediate animals nourished as follow:

Gathering 1 fed orally 0.5% CMC (w/v) (5 ml/kg)

Collection 2 gavage omeprazole 20 mg/kg in CMC (5 ml/kg) as the reference group.<sup>[14]</sup>

Assemblies 3 and 4 were nourished with gold nanoparticles (175 and 350 ppm/p.o), correspondingly.<sup>[15]</sup>

After 1 h, the entire collection is gavage by mouth absolute alcohol. Sixty minutes future, altogether rats were sacrificed under overdose ketamine and xylazine gastric eliminate promptly.<sup>[16,17]</sup>

### Gross Evaluations of Stomachs

Stomach respectively trial rat opened lengthwise greater curvature gastric rinsed cold buffered. Stomach epithelium was examined for any injury using a dissecting microscope. Stomach ulceration on the epithelium appears as long bands of red hemorrhagic damages. Ulcers typically seemed analogous to the long alliance of the stomach. The coldness (mm) and thickness (mm) of every crew were restrained by utilizing an integrator [(10 mm  $\times$  10 mm = ulcer portion) under strew microscopy (1.8 $\times$ )]. Ulcer zone of every laceration designed through count numeral small squares, 2 mm  $\times$  2 mm, cover dimension thickness of every hemorrhagic ulcerated band.<sup>[18]</sup>

The summary of the parts of complete abrasions for respective gastric practical cunning ulcerated part (UA)

The totality of small squares  $\times$  4  $\times$  1.8 = UA mm<sup>2</sup>.

Inhibition % (I %) was calculated by the following preparation

$$\text{Inhibition percentage (I\%)} = \frac{(\text{UA control} - \text{UA treated})}{\text{UA control}} \times 100^{[19]}$$

### Measurement of Stomach pH

Stomach content composed spined estimate pH of stomach's fluid supernatant through pH metrical titration through 0.1 N NaOH solutions utilizing numerical pH pattern and acidity restrained in mEq/L.<sup>[13,20]</sup>

### Quantity of Stomach Mucus Content

Stomachs rinsed with cold phosphate buffer saline. The stomach mucosa of respectively rat's stomach was slightly scrubbed off using a clean slid and mass of secretion quantity utilizing correct electric equilibrium.<sup>[16]</sup>

### Formulation of Gastric Tissue Homogenate

Small piece glandular gastric wall from the respective rat washed away prudently cold PBS. Utilizing homogenizer. A minor

portion of every gastric wall standardized cold PBS including a mammal protease inhibitor mixture. Gastric homogenates centrifuged 1000 g 10 min 4°C. Clean supernatant utilized measure amounts of superoxide dismutase (SOD), catalase (CAT), and malondialdehyde (MDA). These assessments were completed based on the consistent manufactural method (Cayman, USA).<sup>[21]</sup>

### Measurements of Endogenous Antioxidant Enzymes

SOD and CAT activities stomach homogenate measured utilizing lucrative usual kits. The manufacturer's trials were used to measure their amounts in homogenate supernatant.<sup>[22]</sup>

### Measurements of Lipid Peroxidation (MDA) Level of Stomach Homogenate

MDA level glandular stomach homogenate was quantified using merchantable kits consulting to manufactural technique (Cayman Chemical Co).<sup>[23]</sup>

### Histological Evaluation

Minor sections (1–2 cm), respectively, stomach was fixed instantly in 10% formalin overnight followed by tissue dehydrated with ethanol, permission with xylene, and permeation with paraffin using tissue processing apparatus. Respectively stomach tissue was entrenched in wax sections 5  $\mu$ m (Leica Rotation Microtome, Germany).<sup>[24]</sup>

#### Hematoxylin and eosin stain

Slides-stained monotonous hematoxylin and eosin (H & E stain) for histopathology examination using a light microscope.<sup>[25]</sup>

#### Periodic acid Schiff (PAS) stains

To measure mucus excretion of stomach's glandular portion, slices of 5  $\mu$ m width stains with PAS to imagine gastric mucus and differences in both acid and base glycoproteins following the construction exercise method.<sup>[26]</sup>

### Statistical Data Investigation

The statistical investigation was achieved using a one-way analysis of variance (ANOVA) method shadowed through a *post hoc* trial with Turkey's *post hoc* test. Normality testing was performed using the Kolmogorov–Smirnov test. Altogether morals are designed by way of mean  $\pm$  SEM. value of  $P < 0.5$  measured significant.

## RESULTS

### Influence of *Zingiber officinale* Gold Nanoparticle on Gross Assessment of Stomach

Rats fed with *Zingiber officinale* gold nanoparticles showed meaningful reductions in the ulceration portion of gastric comparison to the ulcerated gathering [Figure 1]. Flatten stomach epithelial surface decrease of mucosa damage also noticed macroscopical estimation of investigational rat's stomach nourished with *Zingiber officinale* gold nanoparticle in comparison with ulcerated control assemblage [Figure 1].

### Influence of *Zingiber Officinale* Gold Nanoparticle on Gastric Mucus Content

Experimental rats fed with *Zingiber officinale* gold nanoparticles presented a considerable upsurge in mucus excretion stomach comparison ulcerated cluster [Table 1].

### Effect of *Zingiber Officinale* Gold Nanoparticle on pH of the Stomach

Investigational rats nourished with *Zingiber officinale* gold nanoparticle preceding given of absolute alcohol suggestively augmented stomach pH likened to ulcerated control cluster [Table 1].

### Influence of *Zingiber Officinale* Gold Nanoparticle on the Histological Estimation of Absolute Ethanol-Induced Gastric Ulceration in Rats

#### H & E stain

Ulcer control collection obtainable widespread damage to stomach mucosa, and lacerations infiltrated intensely into the gastric epithelium with edema and white blood cell infiltration of subcutaneous coating. Rats in trial assemblages nourished with *Zingiber officinale* gold nanoparticle exhibited relatively enhanced defense stomach epithelium for instance showed through the lessening of ulcerated portion, lessening or nonappearance edema, provocative cell penetration sub-mucosal coating [Figure 1].

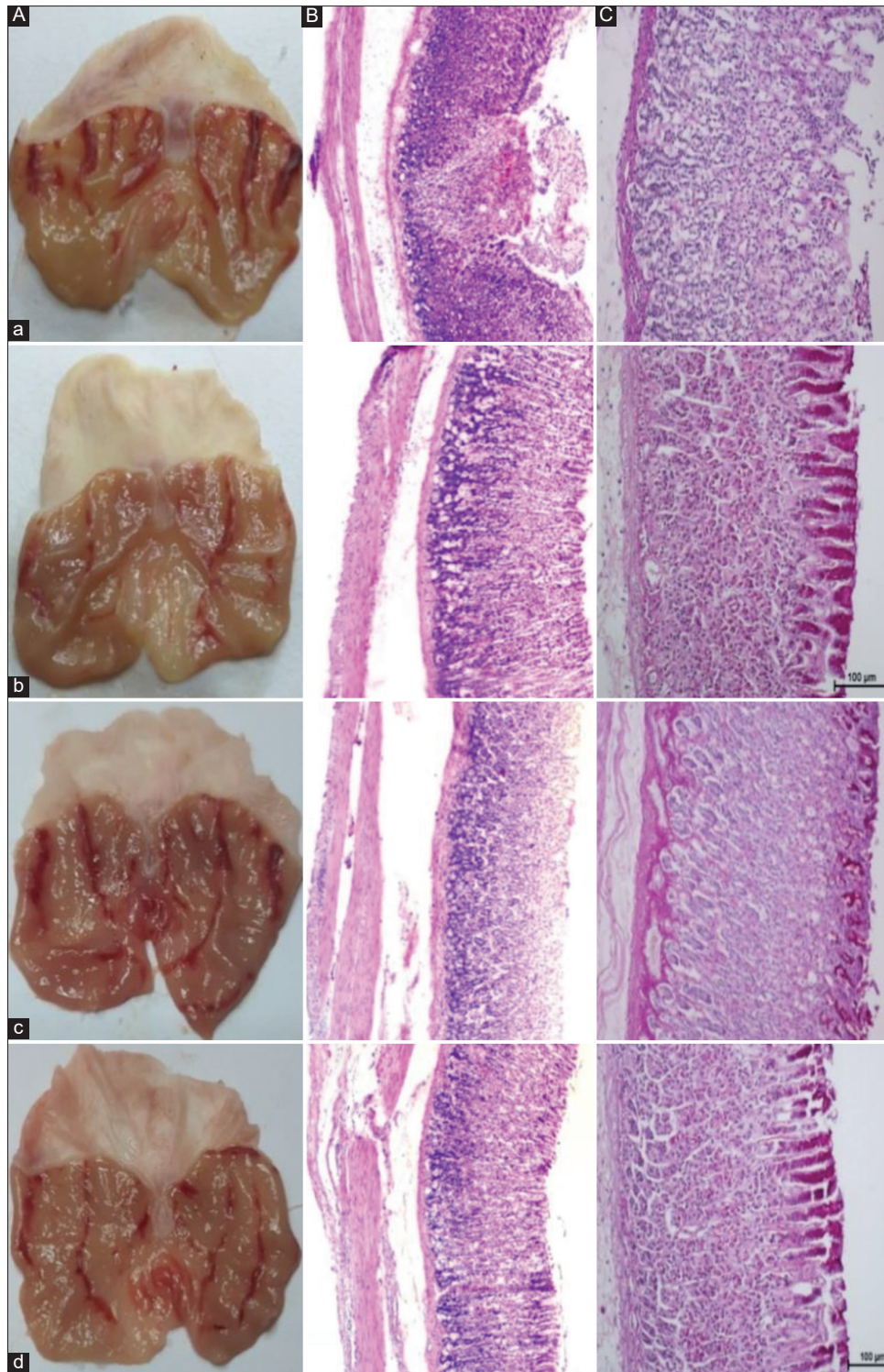
#### PAS stain

Trial rodents nourished with *Zingiber officinale* gold nanoparticles showed a moderately increased PAS staining intensity of glycoprotein of stomach glandular epithelial, in comparison with ulcerated control collection [Figure 1].

**Table 1:** Effect of the gold nanoparticle on mucus weight, pH of the stomach, ulcer area, and inhibition percent of ulcer area in rat's stomachs

Animal groups	Pre-feeding (5mL/kg)	Mucus weight (g)	pH	Ulcer area (mm) <sup>2</sup>	Inhibition (%)
G1 ulcer control	10% tween 20	0.676	2.88 $\pm$ 0.04	779.3 $\pm$ 3.50	-
G2 omeprazole	20 mg/kg omeprazole	1.907	5.81 $\pm$ 0.02	100.2 $\pm$ 1.93	100.2
G3 low dose	175 ppm gold nanoparticle	1.565	5.16 $\pm$ 0.02	153 $\pm$ 2.08	52.6
G4 high dose	350 ppm gold nanoparticle	1.773	5.35 $\pm$ 0.02	136.8 $\pm$ 0.79	36.5





**Figure 1:** Plate 1 (A): Influence of gold nanoparticles on the macroscopical appearance of absolute ethanol-produced gastric damage in rats. (a) Ulcer control cluster showed severe hemorrhagic lacerations of the stomach epithelium. (b) Omeprazole collection presented slight injuries to stomach mucosa. (c and d) Investigational assemblies showing a clear reduction in gastric mucosa. Plate 2 (B): Influence of gold nanoparticle on histology of gastric mucosa against ethanol-induced mucosal damages in rats. a. Ulcerated control cluster viewing severe mucosal injury together with necrosis, edema, and leukocytes penetration of sub-mucosal coating. b. Omeprazole assemblage observing small mucosal impairment. (c and d) Experimental rats exhibition reduction mucosal epithelium (H&E stain). Plate 3 (C): Influence of gold nanoparticle on periodic acid schiff (PAS) stains of stomach glycoproteins secretion on ethanol-produced stomach damages in rats. a. Ulcer control cluster revealed lessening or nonappearance of PAS stains of gastric epithelium with extensive mucosal injuries. (b) Omeprazole set demonstration strong PAS stain. (c and d) Trial groups exhibited dense up-take of PAS stains

## Effects of *Zingiber Officinale* Gold Nanoparticle on Endogenous Antioxidant Enzymes of Stomach Tissue Homogenate

Rats in ulcerated control assortment demonstrated expressively lesser SOD and CAT activities compared to the normal collection. Animals in experimental gatherings nourished *Zingiber officinale* gold nanoparticle offered meaningfully returned the reduction of SOD and CAT to normal range [Figure 2].

## Influences of *Zingiber Officinale* Gold Nanoparticle on Malondialdehyde (MDA) in Gastric Epithelium Homogenate

Animals in ulcerated control collection displayed a considerable increase in MDA level of stomach tissue homogenate compared to normal assemblage [Figure 2]. MDA of gastric homogenate dramatically condensed in rodents nourished with *Zingiber officinale* gold nanoparticles. MDA was used as an indicator for lipid peroxidation.

## DISCUSSION

Absolute alcohol necrotizing agent brings abundant adverse possessions on gastric tissue, for example, damages causing lessening plentiful protein concentration.<sup>[7,9,26,27]</sup> The mucous membrane is recognized chief line of defense organization in the stomach; consequently, absolute alcohol eliminates mucus, and changeable permanent damage predictable.<sup>[3,28]</sup>

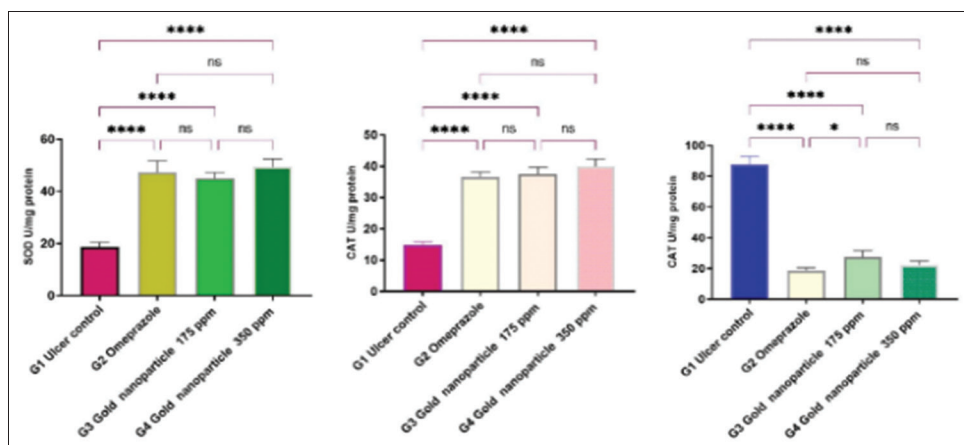
The stomach mucosa performance barrier does not allow disgrace enzymes, for instance, pepsin effusive stomach wall.<sup>[24,29,30]</sup> Chiefly, mucus owns real slight permeability large elements, perhaps pepsin, nonetheless closely subjects, alike tension, absolute alcohol increases permeability reason liberation of vasoactive crops, and finally vascular damage. Vascular damaging enhanced alcohol success in gastric tissue and consequence disproportions removal of bicarbonate and building mucus.<sup>[2,23,31]</sup> Likewise, proposed construction reactive oxygen species (ROS) influenced complete absolute alcohol

significant percentage ulceration development.<sup>[27,32-34]</sup> It is fine recognized that omeprazole drips additional majority acid intended gastric, omeprazole is effective in acid self-sufficient imitations, analogous ethanol ulceration, employment mucosal protection.<sup>[35,36]</sup> Consistently, expected antioxidants, include the ability of gastroprotection.<sup>[3,29,32,37]</sup> In the current study, rats pre-nourished with gold nanoparticle enhanced construction of stomach mucosa increase wide improvement protein concentration in gastric secretions.<sup>[38,39]</sup> Significances of the present exercise were similar with other amendments quantity gastroprotective and antiulcer achievement gold nanoparticle and herbal composites.<sup>[4,40,41]</sup> Pre-feeding with the gold nanoparticle, challengingly impassable gastric acid likewise takeover stomach injury in rats forced feeding ethanol, characteristic gastro-protective effect gold nanoparticle easy relatively protection of gastric wall.<sup>[42,43]</sup> Designated acute inflammation is attracted through ethanol neutrophils penetration the stomach partition.<sup>[1,44]</sup>

The current values recognized submucosal infusion proficiently congested through pre-feeding rodents by the gold nanoparticle. An extensive release of reactive oxygen species (ROS) and free radicals' reason metabolic lessening everlasting damage.<sup>[45]</sup> Pre-feeding rats with the gold nanoparticle, expressively increased the stomach mucus structure weakened acidity of gastric contented.<sup>[5,43]</sup>

Gastric mucosal protection, reduction of hemorrhagic mucosal area, decrease or nonappearance of edema, and provocative responses of sub-mucosal coating rats nourished gold nanoparticle compared to ulcerated control collection long-established by the valuation of the gastric histology.<sup>[8,46,47]</sup>

Periodic acid-Schiff (PAS) staining results displayed increased mucus creation in gastric of rodents pre-nourished gold nanoparticle indorses gastro-protective achievement of gold nanoparticle intensity since of defense of mucus release. These significances consistent abundant other exercises that obtainable substantial upsurge of stomach mucus concentration (PAS) stains nourished several compounds against ethanol produced gastric damages.<sup>[48-50]</sup> PAS stains



**Figure 2:** Effect of the gold nanoparticle using aqueous rhizomes extract of *Zingiber officinale* on antioxidant enzyme activities (SOD and CAT) and MDA level in the liver. Statistically significant differences were examined using one-way ANOVA and Tukey's *post hoc* multiple comparisons test. \*\*\*\* $P < 0.0001$ , \*\*\* $P < 0.001$ , \*\* $P < 0.005$ , \* $P < 0.05$  above columns specify significant differences from the normal control group and above lines for the differences between treated groups. ns  $P > 0.05$  denotes to non-significant differences



decrease in ethanol contrary augmented through gold nanoparticle feeding likewise formed increased glycoprotein content.<sup>[5,49]</sup> Superoxide radical anion is formed through polymorph nuclear neutrophils subsequent in reply by cellular lipids formation lipid peroxides. Supplementary actual indicators oxidative compression motives mucosal injury could be MDA principal metabolite of fat peroxidation.<sup>[1,51]</sup> Conferring to results of existing exercise, oral forced feeding of gold nanoparticles protects against gastric ulcer through upsurge SOD and CAT actions, and lessening MDA quantity consistent with consequences specified through plentiful investigators concerning SOD and CAT actions enhanced gold nanoparticle nourished clusters in comparison to absolute alcohol gavage rodents.<sup>[43,52]</sup> Furthermore, reduction in MDA quantities were specified rats forced feeding with many herbal and artificial composites.<sup>[50,53]</sup> ROS, for example, hydroxyl radicals, superoxide anions, and lipid peroxides damaging programs approved to worsen gastric ulcer development.<sup>[54]</sup> Antioxidants hunt free-radical formation exhibition principal portion in the protection of cellular damage. Rats fed gold nanoparticle enhanced antioxidant enzymes activities in contrast to ulcer collection evading free radical construction might happen through ulcered development. Comparable outcomes have been described through numerous academics.<sup>[28,38]</sup>

## CONCLUSIONS

According to the significance of the existing study, gold nanoparticles revealed significantly gastroprotective results in inhibition of ethanol-induced gastric ulcers in rats as accepted by macroscopic appearance, histology, and PAS stain. Gold nanoparticle intensely increases the serum concentration of CAT and SOD, while significant reduction of hepatic MDA. The gastroprotective significance of gold nanoparticles in ethanol-induced ulceration could be due to its measurements to discount oxidative stress, lipid peroxidation, and its antioxidant and free-radical scavenger possessions.

## Statement of Rival Interest

The authors announce that they have no acknowledged rival financial welfares or individual relations that could have seemed to affect the work stated in this manuscript.

## Writer Aids

Altogether novelists paid to train beginning and enterprise. S.H. S and M.A.A: Leading the trials, information gathering, and examination, document research. Students: Analysis and clarification of information, studied breezes of the script. Students subsidized reagents materials, understanding of statistics, and studied breezes of text.

## REFERENCES

1. F. A. Armah, I. T. Henneh, J. Alake, W. Ahlidja, B. Amoani, E. G. Ofori, B. Asante-Kyei, G. I. Temitayo, C. K. Adokoh. *Allanblackia floribunda* seed extract attenuates the ethanol-induced gastric ulcer in rats via the inhibition of TNF- $\alpha$  and INF- $\gamma$  levels and modulation in the expression of Ki67 protein. *BioMedical Research International*, vol. 2021, pp. 6694572, 2021.
2. D. Zhou, Q. Yang, T. Tian, Y. Chang, Y. Li, L. R. Duan, H. Li and S. W. Wang. Gastroprotective effect of gallic acid against ethanol-induced gastric ulcer in rats: Involvement of the Nrf2/HO-1 signaling and anti-apoptosis role. *Biomedicine & Pharmacotherapy*, vol. 126, pp. 110075, 2020.
3. A. M. Ahmad, K. Y. Ibrahim and A. M. Mohammad. Efficacy of extract from *Ononis spinosa* L. on ethanol-induced gastric ulcer in rats. *Journal of Traditional Chinese Medicine*, vol. 41, no. 2, pp. 270-275, 2021.
4. A. A. Naser, E. Younis, A. El-Feky, M. Elbatanony and M. Hamed. Management of *Citrus sinensis* peels for protection and treatment against gastric ulcer induced by ethanol in rats, *Biomarkers*, vol. 25, no. 4, pp. 349-359, 2020.
5. Z. Huang, Y. Shi, H. Wang, C. Chun, L. Chen, K. Wang, Z. Lu, Y. Zhao and X. Li. Protective Effects of chitosan-bilirubin nanoparticles against ethanol-induced gastric ulcers. *International Journal of Nanomedicine*, vol. 16, pp. 8235, 2021.
6. Z. B. Barka, M. Tlili, H. Alimi, H. B. Miled, K. B. Rhouma, M. Sakly, R. Ksouri, Y.J. Schneider and O. Tebourbi. Protective effects of edible *Rhus tripartita* (Ucria) stem extract against ethanol-induced gastric ulcer in rats. *Journal of Functional Foods*, vol. 30, pp. 260-269, 2017.
7. N. M. Fahmy, E. Al-Sayed, H. E. Michel, M. El-Shazly and A. N. B. Singab. Gastroprotective effects of *Erythrina speciosa* (Fabaceae) leaves cultivated in Egypt against ethanol-induced gastric ulcer in rats. *Journal of Ethnopharmacology*, vol. 248, pp. 112297, 2020.
8. P. Mathur, S. Jha, S. Ramteke and N. Jain. Pharmaceutical aspects of silver nanoparticles. *Artificial Cells Nanomedicine and Biotechnology*, vol. 46vol. sup1, pp. 115-126, 2018.
9. M. S. Shin, J. Lee, J. W. Lee, S. H. Park, I. K. Lee, J. A. Choi, J. S. Lee and K. S. Kang. Anti-inflammatory effect of *Artemisia argyi* on ethanol-induced gastric ulcer: Analytical, *in vitro* and *in vivo* studies for the identification of action mechanism and active compounds. *Plants (Basel)*, vol. 10, no.2, pp. 332, 2021.
10. A. Mahmood, K. Sidik, I. Salmah, K. Suzainur and K. Yusoff. Cytoprotective effects of honey and methanol extracts from *P. granatum* L. fruit peel and *N. sativa* L seeds on ethanol-induced gastric damage in rats. *Journal of Food Technology*, vol. 2, no. 3, pp. 136-141, 2004.
11. M. A. Abdulla, H. M. Ali, K. A. A. Ahmed, S. M. Noor and S. Ismail. Evaluation of the anti-ulcer activities of *Morus alba* extracts in experimentally-induced gastric ulcer in rats. *Biomedical Research*, vol. 20, no. 1, pp. 35-39, 2009.
12. N. Abdullah, D. M. V. Gopal and M. A. Abdulla. Effect of soya beans and soya beans fermented with schizophyllum commune fr. On ethanol-induced gastric ulcer in sprague-dawley rats. *Acta Alimentaria*, vol. 41, no. 3, pp. 334-342, 2012.
13. A. Mahmood, K. Sidik and H. Fouad. Prevention of ethanol-induced gastric mucosal injury by *Ocimum basilicum* seed extract in rats. *ASM Science Journal*, vol. 1, no. 1, pp. 1-6, 2007.
14. M. Phipps and A. Mahmood. Gastroprotective activity of P. Major in rats. *International Journal of Tropical Medicine*, vol. 1, pp. 36-39, 2006.
15. N. A. Salem, M. A. Wahba, W. H. Eisa, M. El-Shamarka and W. Khalil. Silver oxide nanoparticles alleviate indomethacin-induced gastric injury: A novel antiulcer agent. *Inflammopharmacology*, vol. 26, no. 4, pp. 1025-1035, 2018.
16. A. Mahmood, K. Sidik, I. Salmah, K. Suzainur and K. Philip. Antiulcerogenic activity of *Ageratum conyzoides* leaf extract against. *International Journal of Molecular Medicine and Advance Sciences*, vol. 50, no. 4, pp. 402-405, 2005.
17. K. A. Ketuly, M. A. Abdulla, H. A. Hadi, A. A. Mariod and S. I. Abdel-Wahab. Anti-ulcer activity of the 9 $\alpha$ -bromo analogue of beclomethasone dipropionate against ethanol-induced gastric mucosal injury in rats. *Journal of Medicinal Plants Research*, vol. 5, no. 4, pp. 514-520, 2011.
18. A. Mahmood, K. Philip and I. Salmah. Anti ulcerogenic effect of the rhizomes of *Zingiber officinale* against ethanol induced

- gastric ulcers in rats. *Journal of Animal and Veterinary Advances*, vol. 5, no. 2, pp. 122-125, 2006.
19. S. Noor, A. Mahmood, I. Salmah and K. Philip. Prevention of acute gastric mucosal lesions by *R. hasseltii* in rats. *Journal of Animal and Veterinary Advances*, vol. 5, pp. 161-164, 2006.
  20. J. Hussaini, N. A. Othman, M. A. Abdulla. Antiulcer and antibacterial evaluations of *Illicium verum* ethanolic fruits extract (IVEFE). *The Open Conference Proceedings Journal*, vol. 4, pp. 202, 2013.
  21. S. M. Dhiyaaldeen, Z. A. Amin, P. H. Darvish, I. F. Mustafa, M. M. Jamil, E. Rouhollahi and M. A. Abdulla. Protective effects of (1-(4-hydroxy-phenyl)-3-m-tolyl-propenone chalcone in indomethacin-induced gastric erosive damage in rats. *BMC Veterinary Research*, vol. 10, no. 1, pp. 1-14, 2014.
  22. M. S. Salga, H. M. Ali, M. A. Abdulla and S. I. Abdelwahab. Gastroprotective activity and mechanism of novel dichlorido-zinc (II)-4-(2-(5-methoxybenzylideneamino) ethyl) piperazin-1-iumphenolate complex on ethanol-induced gastric ulceration. *Chemico Biological Interactions*, vol. 195, no. 2, pp. 144-153, 2012.
  23. N. S. Gwaram, L. Musalam, H. M. Ali, M. A. Abdulla and S. A. Shaker. Synthesis, spectral characterization and biological activity of Zn (II) complex with 2'-[1-(2-hydroxyphenyl) ethylidene] benzenesulfanohydrazide. *Arabian Journal of Chemistry*, vol. 9, pp. S1197-S1207, 2016.
  24. N. Nazarbajhat, F. A. Kadir, A. Ariffin, M. A. Abdulla, Z. Abdullah and W. A. Yehye. Antioxidant properties and gastroprotective effects of 2-(ethylthio) benzohydrazones on ethanol-induced acute gastric mucosal lesions in rats. *PLoS One*, vol. 11, no. 6, pp. e0156022, 2016.
  25. N. S. B. A. Bashah and M. A. Abdulla. Cytoprotective effect of *Nigella sativa* L. On experimentally induced gastric ulcer in rats. *Annals of Medicine and Healthcare Research*, vol. 164, 2009.
  26. M. S. Salga, H. M. Ali, M. A. Abdulla, S. I. Abdelwahab, M. M. E. Taha, U. Yagoub. Synthesis and gastroprotective activities of some zinc (II) complexes derived from (E)-2-(1-(2-(piperazin-1-yl) ethylimino) ethyl) phenol and (E)-4-(1-(2-(piperazin-1-yl) ethylimino) ethyl) benzene-1, 3-diol Schiff bases against aspirin induced ulceration. *Arabian Journal of Chemistry*, vol. 10, pp. S1578-S1589, 2017.
  27. N. S. Al-Wajeeh, M. Hajrezaie, N. Al-Henhena, S. Kamran, E. Bagheri, M. Zahedifard, K. Saremi, S. M. Noor, H. M. Ali and M. A. Abdulla. The antiulcer effect of *Cibotium barometz* leaves in rats with experimentally induced acute gastric ulcer. *Drug Design Development and Therapy*, vol. 11, pp. 995, 2017.
  28. K. Saremi, S. K. Rad, M. Khalilzadeh, J. Hussaini and N. A. Majid. *In vivo* acute toxicity and anti-gastric evaluation of a novel dichloro Schiff base: Bax and HSP70 alteration. *Acta Biochimica et Biophysica Sinica*, vol. 52, no. 1, pp. 26-37, 2020.
  29. H. Omar, N. Nordin, P. Hassandarvish, M. Hajrezaie, A. H. S. Azizan, M. Fadaeinasab, N. A. Majid, M. A. Abdulla, N. M. Hashim and H. M. Ali. Methanol leaf extract of *Actinodaphne sesquipedalis* (Lauraceae) enhances gastric defense against ethanol-induced ulcer in rats. *Drug Design Development and Therapy*, vol. 11, pp. 1353, 2017.
  30. W. E. A. El Hady, E. A. Mohamed, O. A. E. A. Soliman and H. M. El-Sabbagh. *In vitro in vivo* evaluation of chitosan-PLGA nanoparticles for potentiated gastric retention and anti-ulcer activity of diosmin. *International Journal of Nanomedicine*, vol. 14, pp. 7191-7213, 2019.
  31. G. Wardani, K. Eraiko and S. A. Sudjarwo. Protective activity of chitosan nanoparticle against cadmium chloride induced gastric toxicity in rat. *Journal of Young Pharmacists*, vol. 10, no. 3, pp. 303-307, 2018.
  32. S. M. Salama, N. S. Gwaram, A. S. AlRashdi, S. A. Khalifa, M. A. Abdulla, H. M. Ali, H. R. El-Seedi. A zinc morpholine complex prevents HCl/ethanol-induced gastric ulcers in a rat model. *Scientific Reports*, vol. 6, no. 1, pp. 1-15, 2016.
  33. K. Saremi, E. Bagheri, S. K. Rad, A. A. Salman and N. A. Majid. *In vivo* evaluation of wound healing improvement of a new Schiff base derived bromine compound (CNBP) in rats. *Gene Reports*, vol. 16, no. 3, pp. 100429, 2019.
  34. M. I. G. El-Din, F. S. Youssef, R. S. Said, M. L. Ashour, O. A. Eldahshan and A. N. B. Singab. Chemical constituents and gastro-protective potential of *Pachira glabra* leaves against ethanol-induced gastric ulcer in experimental rat model. *Inflammopharmacology*, vol. 29, no. 1, pp. 317-332, 2021.
  35. I. A. A. Ibrahim, M. A. Abdulla, M. Hajrezaie, A. Bader, N. Shahzad, S. S. Al-Ghamdi, A. S. Gushash and M. Hasanpourghadi. The gastroprotective effects of hydroalcoholic extract of *Monolluma quadrangula* against ethanol-induced gastric mucosal injuries in Sprague Dawley rats. *Drug Design Development and Therapy*, vol. 10, pp. 93-205, 2016.
  36. Z. Rahman, D. Dwivedi and G. Jena. Ethanol-induced gastric ulcer in rats and intervention of tert-butylhydroquinone: Involvement of Nrf2/HO-1 signalling pathway. *Human and Experimental Toxicology*, vol. 39, no. 4, pp. 547-562, 2020.
  37. M. Hajrezaie, N. Salehen, H. Karimian, M. Zahedifard, K. Shams, R. A. Batran, N. A. Majid, S. A. Khalifa, H. M. Ali and H. El-Seedi. Biochanin a gastroprotective effects in ethanol-induced gastric mucosal ulceration in rats. *PLoS One*, vol. 10, no. 3, pp. e0121529, 2015.
  38. S. Z. Moghadamtousi, E. Rouhollahi, M. Hajrezaie, H. Karimian, M. A. Abdulla and H. A. Kadir. *Annona muricata* leaves accelerate wound healing in rats via involvement of Hsp70 and antioxidant defence. *International Journal of Surgery*, vol. 18, pp. 110-117, 2015.
  39. A. E. Ofusori, R. Moodley, S. B. Jonnalagadda. Antiulcerogenic effects of *Celosia trigyna* plant extracts on ethanol-induced gastric ulcer in adult Wistar rats. *Journal of Traditional and Complementary Medicine*, vol. 10, no. 6, pp. 586-593, 2020.
  40. S. Golbabapour, M. Hajrezaie, P. Hassandarvish, N. Abdul Majid, A. H. A. Hadi, N. Nordin and M. A. Abdulla. Acute toxicity and gastroprotective role of *M. pruriens* in ethanol-induced gastric mucosal injuries in rats. *BioMedical Research International*, vol. 2013, pp. 974185, 2013.
  41. M. M. E. Taha, S. I. Abdelwahab, R. Elsanousi, B. Y. Sheikh, M. A. Abdulla, S. E. Babiker, H. Elraih and E. Mohamed. Effectiveness of sidr honey on the prevention of ethanol-induced gastrulcerogenesis: Role of antioxidant and antiapoptotic mechanism. *Pharmacognosy Journal*, vol. 7, no. 3, pp. 157-164, 2015.
  42. M. R. Akanda, I. S. Kim, D. Ahn, H. J. Tae, H. H. Nam, B. K. Choo, K. Kim and B. Y. Park. Anti-inflammatory and gastroprotective roles of raddosia inflexa through downregulation of pro-inflammatory cytokines and MAPK/NF- $\kappa$ B signaling pathways. *International Journal of Molecular Sciences*, vol. 19, no. 2, pp. 584, 2018.
  43. J. Hu, J. Luo, M. Zhang, J. Wu, Y. Zhang, H. Kong, H. Qu, G. Cheng and Y. Zhao. Protective effects of radix sophorae flavescentis carbonisate-based carbon dots against ethanol-induced acute gastric ulcer in rats: Anti-inflammatory and antioxidant activities. *International Journal of Nanomedicine*, vol. 16, pp. 2461-2475, 2021.
  44. A. S. AlRashdi, S. M. Salama, S. S. Alkiyumi, M. A. Abdulla, A. H. A. Hadi, S. I. Abdelwahab, M. M. Taha, J. Hussaini and N. Asykin. Mechanisms of gastroprotective effects of ethanolic leaf extract of *Jasminum sambac* against HCl/ethanol-induced gastric mucosal injury in rats. *Evidence-Based Complementary and Alternative Medicine*, vol. 2012, pp. 786426, 2012.
  45. N. A. Salem, M. A. Wahba, W. H. Eisa, M. El-Shamarka and W. J. I. Khalil. Silver oxide nanoparticles alleviate indomethacin-induced gastric injury: A novel antiulcer agent. *Inflammopharmacology*, vol. 26, no. 4, pp. 1025-1035, 2018.
  46. K. A. Ketuly, A. H. A. Hadi, S. Golbabapour, M. Hajrezaie, P.

- Hassandarvish, H. M. Ali, N. A. Majid and M. A. Abdulla. Acute toxicity and gastroprotection studies with a newly synthesized steroid. *PLoS One*, vol. 8, no, 3, pp. e59296, 2013.
47. M. Alai and W. J. Lin. Application of nanoparticles for oral delivery of acid-labile lansoprazole in the treatment of gastric ulcer: *In vitro* and *in vivo* evaluations. *International Journal of Nanomedicine*, vol. 10, pp. 4029, 2015
  48. M. Zeeshan, A. Atiq, Q. U. Ain, J. Ali, S. Khan and H. Ali. Evaluating the mucoprotective effects of glycyrrhizic acid-loaded polymeric nanoparticles in a murine model of 5-fluorouracil-induced intestinal mucositis via suppression of inflammatory mediators and oxidative stress. *Inflammopharmacology*, vol. 29, no. 5, pp. 1539-1553, 2021.
  49. S. Zou, B. Wang, C. Wang, Q. Wang and L. Zhang. Cell membrane-coated nanoparticles: Research advances. *Nanomedicine*, vol. 15, no. 6, pp. 625-641, 2020.
  50. X. Yan, Z. Huang, Y. Wu, Z. Yu, K. Yang, Z. Chen, W. Wang, H. Hu and Z. Wang. Sequential loading of inclusion complex/nanoparticles improves the gastric retention of vladimiriae radix essential oil to promote the protection of acute gastric mucosal injury. *International Journal of Pharmaceutics*, vol. 610, pp. 121234, 2021.
  51. A. El-Rady, M. Nessren, M. A. Dahpy, A. Ahmed, D. A. Elgamel, S. Hadiya, M. A. Ahmed, Z. E. A. A. Sayed, D. Abdeltawab, A. S. Abdelmohsen, A. A. M. Farrag, A. M. Ashmawy, M. K. Khairallah, H. M. Galal. Interplay of biochemical, genetic, and immunohistochemical factors in the etio-pathogenesis of gastric ulcer in rats: A comparative study of the effect of pomegranate loaded nanoparticles versus pomegranate peel extract. *Frontiers in Physiology*, vol. 12, pp. 335, 2021.
  52. J. Liu, H. Lin, L. Yuan, D. Wang, C. Wang, J. Sun, C. Zhang, J. Chen, H. Li and S. Jing. Protective effects of anwulignan against HCl/ethanol-induced acute gastric ulcer in mice. *Evidence-Based Complementary and Alternative Medicine*, vol. 2021, pp. 9998982, 2021.
  53. S. Lu, S. Kong, Y. Wang, Z. Hu, L. Zhang and M. Liao. Gastric acid-response chitosan/alginate/tilapia collagen peptide composite hydrogel: Protection effects on alcohol-induced gastric mucosal injury. *Carbohydrate Polymers*, vol. 277, pp. 118816, 2022.
  54. J. Lawrence, G. Swerhone, J. Dynes, A. Hitchcock and D. Korber. Complex organic corona formation on carbon nanotubes reduces microbial toxicity by suppressing reactive oxygen species production. *Environmental Science Nano*, vol. 3, no. 1, pp. 181-189, 2016.