








Clinical, epidemiological, and histopathological aspects of breast cancer in female dogs at Federal Rural University of Rio de Janeiro Veterinary Hospital

Aspectos clínicos, epidemiológicos e histopatológicos do câncer de mama em cães atendidos no Hospital Veterinário da Universidade Federal Rural do Rio de Janeiro

Lucinéia Costa Oliveira¹ , Maria Eduarda dos Santos Lopes Fernandes^{1*} , Anna Julia Rodrigues Peixoto¹ , Felipe Farias Pereira da Camara Barros² , Cássia Maria Molinaro Coelho² , Vivian de Assunção Nogueira³  & Saulo Andrade Caldas² 

¹ Veterinarian, MSc., Programa de Pós-graduação em Medicina Veterinária, Departamento de Medicina e Cirurgia Veterinária (DMCV), Instituto de Veterinária (IV), Universidade Federal Rural do Rio de Janeiro (UFRRJ), *campus* Seropédica - RJ, Brazil

² Veterinarian, DSc., DMCV, IV, UFRRJ, *campus* Seropédica - RJ, Brazil

³ Veterinarian, DSc., Departamento de Epidemiologia e Saúde Pública, IV, UFRRJ, *campus* Seropédica - RJ, Brazil

Abstract

This study aimed to evaluate the clinical, epidemiological, and histopathological aspects of canine breast tumors at the Federal Rural University of Rio de Janeiro Veterinary Hospital (VH-UFRRJ) between April 2017 and October 2018. The study included 137 female canine dogs with mammary neoplasia who underwent a mastectomy. The animals were evaluated using a standard form that guided anamnesis and physical examination to assess the tumor's epidemiology, development, evolution, treatment choice, and disease prognosis. Furthermore, laboratory and imaging tests were performed on the animals to search for changes that suggested metastasis. The average age of the female dogs was 10 years, and mixed-breed dogs (33%) were the most affected, followed by poodles (21%). The inguinal (79%) and caudal abdominal (64%) breasts were the most affected. Approximately 26% of the animals were castrated, 32% had already reproduced throughout their lives, 30% had pseudocystosis, and only 8% used contraceptive methods. The majority were classified as stage I (33%) and stage III (39%) according to the Tumor-Node-Metastasis (TNM) Classification System of Malignant Tumors. In 95 female dogs, 191 nodules were histopathologically evaluated, and 62% of these animals had at least one malignant tumor. Statistically, there was a direct association between tumor size and malignancy. However, other associations, such as age at diagnosis and the degree of malignancy, were not confirmed. Therefore, it can be concluded that tumor size is an important prognostic factor, with tumors >3 cm having an approximately 70% chance of being malignant.

Keywords: dog, malignancy, mastectomy.

Resumo

O objetivo do presente trabalho foi avaliar os aspectos clínicos, epidemiológicos e histopatológicos dos tumores de mama caninos atendidos no Hospital Veterinário da Universidade Federal Rural do Rio de Janeiro, no período de abril de 2017 a outubro de 2018. Contemplaram o estudo 137 fêmeas caninas com neoplasia mamária submetidas à mastectomia. As cadelas foram avaliadas utilizando-se uma ficha padrão que orientou a anamnese e exame físico com objetivo de avaliar a epidemiologia, o desenvolvimento e evolução do tumor, bem como escolha do tratamento e prognóstico da doença. Adicionalmente foram realizados exames laboratoriais e de imagem nas pacientes, em busca de alterações que sugerissem metástase. A idade média das cadelas foi 10 anos, os animais sem raça definida (33%) foram os mais afetados, seguidos pela raça Poodle (21%). As mamas inguinais (79%) e abdominais caudais (64%) foram as mais acometidas. Cerca de 26% das cadelas eram castradas, 32% das fêmeas já haviam se reproduzido ao longo da vida, 30% tiveram pseudocistose, apenas 8% usaram métodos contraceptivos e a maioria foi classificada em estágio I (33%) e estágio III (39%), de acordo com o Sistema de Classificação de Tumores Malignos "Tumor-Node-Metastasis" (TNM - Tumor, Linfonodo, Metástase). O exame histopatológico foi realizado em 191 nódulos de 95 cadelas, 62% destas fêmeas possuíam pelo menos um nódulo maligno. Estatisticamente, houve associação direta entre o tamanho do tumor e sua malignidade. Outras associações




How to cite: Oliveira, L. C., Fernandes, M. E. S. L., Peixoto, A. J. R., Barros, F. F. P. C., Coelho, C. M. M., Nogueira, V. A., & Caldas, S. A. (2022). Clinical, epidemiological, and histopathological aspects of breast cancer in female dogs at Federal Rural University of Rio de Janeiro Veterinary Hospital. *Brazilian Journal of Veterinary Medicine*, 44, e000722. <https://doi.org/10.29374/2527-2179.bjvm000722>

Received: February 21, 2022.

Accepted: August 30, 2022

*Correspondence

Maria Eduarda dos Santos Lopes Fernandes
Departamento de Medicina e Cirurgia Veterinária, Instituto de Veterinária, Universidade Federal Rural do Rio de Janeiro - UFRRJ
Rodovia BR 465, Km 7, Campus Universitário, Bairro Zona Rural
CEP 23897-000 - Seropédica (RJ), Brazil
E-mail: dudalopesfer@hotmail.com

 Copyright Oliveira et al. This is an Open Access article distributed under the terms of the Creative Commons Attribution Non-Commercial License, which permits unrestricted non-commercial use, distribution and reproduction in any medium provided the original work is properly cited.

como idade do diagnóstico e grau de malignidade não foram confirmadas. Conclui-se, portanto, que o tamanho do tumor é um importante fator prognóstico, uma vez que tumores maiores que 3 cm têm cerca de 70% de chance de serem malignos.

Palavras-chave: cão, malignidade, mastectomia.

Introduction

Mammary neoplasia is a common condition in dogs, and its prevalence in these species is considerably increasing. Breast tumors represent more than 50% of the neoplasms that affect female canines, and half of them are malignant (Cassali et al., 2014; Daleck et al., 1998).

Compared to humans, canine mammary tumors (CMTs) have a threefold higher incidence (Brodey et al., 1983; Rivera & Von Euler, 2011). In addition, females (Misdorff, 2002; Moe, 2001; Morris et al., 2000; Saba et al., 2007; Sorenmo et al., 2009) aged 9-11 years old (Sorenmo, 2003) are more affected, with no racial predisposition (MacPhail, 2014; Queiroga & Lopes, 2002).

The inguinal breast is the most affected, followed by the abdominal and thoracic breasts (Ežerskytė et al., 2011). Therefore, the treatment choice is surgery, and the entire breast chain should be removed along with the sentinel lymph nodes (Cassali et al., 2014, MacPhail, 2014; Papazoglou et al., 2014). Prognosis depends on the tumor and histological characteristics, ranging from optimal when surgery is curative to poor when long-distance metastasis is already present (Cassali et al., 2014; MacPhail, 2014).

Therefore, this study aimed to describe and correlate epidemiological data, staging, anatomical location, size, histological type, and malignancy grade of female dogs with CMT treated at the Federal Rural University of Rio de Janeiro Veterinary Hospital (VH-UFRRJ).

Material and methods

A total of 137 female dogs with mammary neoplasms were evaluated and referred to the Obstetrics Sector of the VH-UFRRJ between April 2017 and October 2018. This study was approved by the Ethics Committee for Animal Use at UFRRJ (CEUA/UFRRJ) under protocol N^o. 3029200417.

The animals were registered with the aid of an "obstetric breast tumor" form, which directed the anamnesis and physical examination to evaluate the tumor's development and evolution, the choice of the surgical technique to be instituted, and the prognosis of the disease.

During the anamnesis, the animal's owner was asked about the onset of tumor appearance, growth rate, reproductive history, presence of pseudocyesis, and contraceptive use. The physical examination determined the amount, anatomical location, size, and characteristics (adherence, consistency, and ulceration) of each tumor and the involvement of sentinel lymph nodes. Tumors were measured in at least two dimensions. When the animal presented more than one nodule, each was measured separately, and the largest measurement was considered for clinical staging, according to the TNM Classification System of Malignant Tumors (Owen, 1980). After nodule measurement, the animals were divided into three groups: Group 1 (tumors measuring 0-3 cm), Group 2 (tumors measuring 3-5 cm), and Group 3 (tumors measuring 5 cm or more). Macroscopic evaluation of the inguinal and axillary lymph nodes was performed by palpation. During a mastectomy, inguinal lymph nodes were removed together with the mammary chain, unlike the axillary lymph nodes, which were removed only when the animals had axillary and thoracic breast tumors.

In addition, complete blood count, serum biochemistry (albumin, creatinine, urea, alanine aminotransferase, aspartate aminotransferase, and glutamic oxaloacetic transaminase), thoracic radiography, and abdominal ultrasonography were performed. Individual forms were used to record the results and data on history, anamnesis, physical examination, and evolution after surgery.

All the female dogs underwent surgery after preoperative evaluation and preparation. First, they underwent a total unilateral mastectomy of the affected mammary chain, and in cases of bilateral involvement, the chain with the largest tumor size was removed first. Then, the breast tissue was completely removed using surgical margins, according to the principles of oncologic surgery (Cassali et al., 2014).

Breast chain fragments were collected from 95 female dogs (95/137), fixed in 10% formaldehyde, and sent for histopathological examination to establish a definitive diagnosis and aid in disease

staging. The histopathological classification was based on the World Health Organization guidelines for mammary gland tumors in dogs and cats (Misdorp et al., 1999).

After clinical and histopathological examination, clinical staging of the animals was performed based on tumor size (T), neoplastic involvement of regional lymph nodes (N), and presence of distant metastases (M), according to the TNM Classification System of Malignant Tumors (Owen, 1980). The presence or absence of neoplastic involvement was determined using histopathological examination after surgical excision of the involved breast. The search for distant metastasis was performed using imaging (thoracic radiography and abdominal ultrasonography).

Pearson or Spearman correlations were used in assessing the association between the number of lesions with pseudocyesis manifestation, tumor malignancy with pseudocyesis manifestation, and degree of tumor malignancy with its size, considering r or $\rho < 0.4$ for no association, $0.4 < r$ or $\rho < 0.7$ for a weak association, and r or $\rho > 0.7$ for a strong association. In addition, a chi-square test was performed to compare tumor size (Group 1: 0-3 cm, Group 2: 3-5 cm, and Group 3: > 5 cm) and histological characteristics (malignant or benign), with a significance level of 5%.

Results

Among the 137 female dogs evaluated, mixed-breed dogs (MB), poodles, and pinschers were the most affected, representing 33%, 21%, and 11% of the sample population, respectively (Figure 1). Their ages ranged from 4-16 years, with a mean of 10 years (Figure 2).

Regarding reproductive status, 26% of the animals (36/137) were castrated, only one female dog underwent ovariectomy (OSH) shortly after the first heat, and 32% (45/137) reproduced at least once throughout their life.

Forty-one animals (30%) developed pseudocyesis. In addition, the owners of 11 female dogs (8%) reported contraceptive use at some stage of the animal's life.

The frequency of animals with two or more breast tumors was 85%, and 26% (36/138) of tumors were identified in only one breast chain. The average nodule size per animal was 4 ± 2 cm.

Regarding location, the inguinal breasts were involved in 79% (108/137) of the female dogs, the caudal abdominal breasts in 64% (87/137), the cranial abdominal breasts in 50% (69/137), the caudal thoracic breasts in 39% (54/137), and the cranial thoracic breasts in 28% (38/137). Involvement of the left and right breast chains was equivalent.

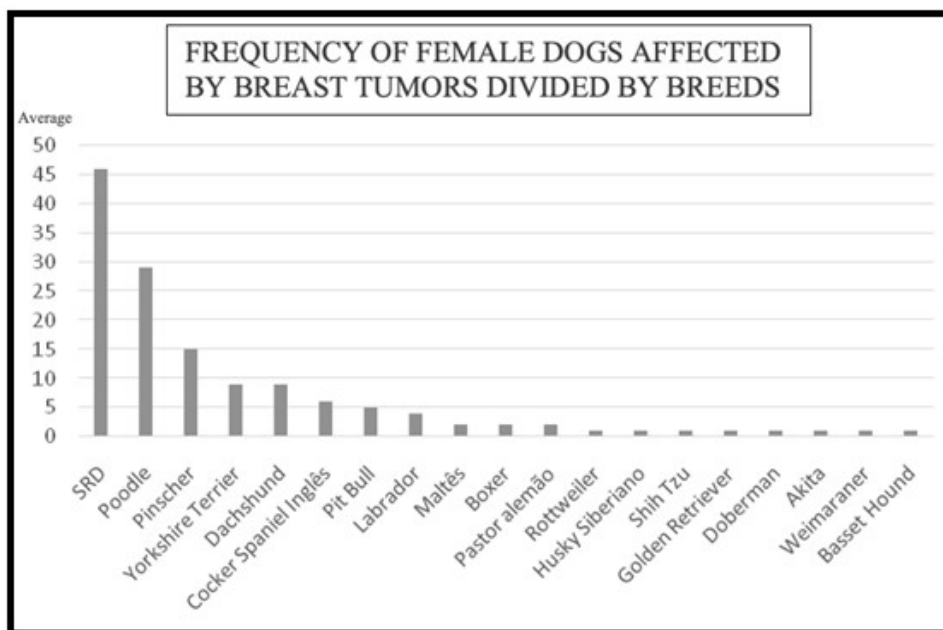


Figure 1. Breeds of canine mammary tumor (n = 137) animals treated at the Federal Rural University of Rio de Janeiro Veterinary Hospital between April 2017 and October 2018.

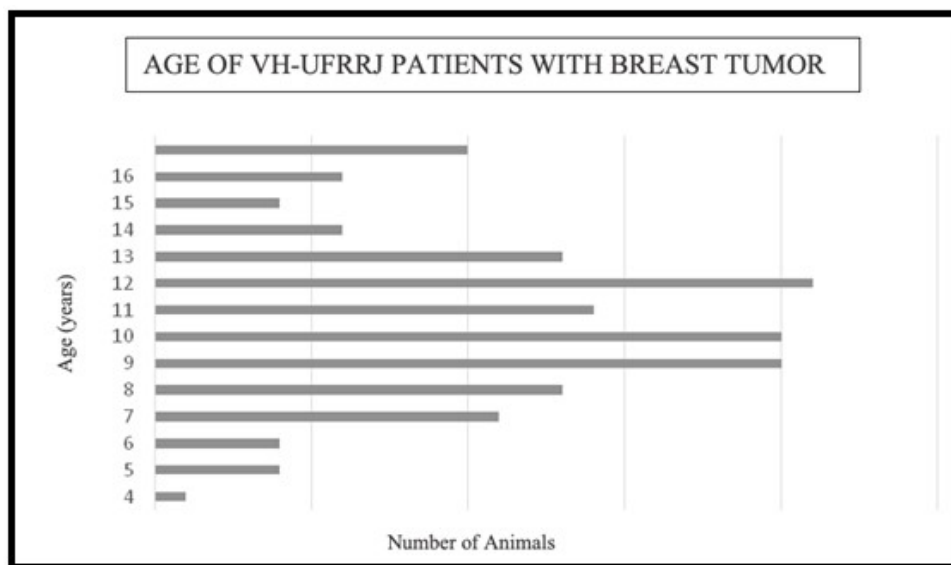


Figure 2. According to age at diagnosis, female dogs (n = 137) with mammary tumors attended the Federal Rural University of Rio de Janeiro Veterinary Hospital between April 2017 and October 2018.

Regarding clinical staging, most animals were diagnosed with stage III disease (39%). In addition, stages I (33%), II (17%), and IV (11%) were also observed; however, the most severe form of evolution (stage IV) was less frequent.

Histopathological examination of 191 neoforations from the 95 female dogs was performed, of which 47% were benign neoplasms, 37% were malignant, and 16% were pre-neoplastic or non-neoplastic lesions. Adenocarcinoma was the most prevalent malignant neoplasm (40), followed by carcinoma (15), mixed tumors (9), malignant myoepithelioma (3), osteosarcoma (1), carcinosarcoma (1), and myoepithelioma adenocarcinoma (1). Benign neoplasms included adenoma (55), mixed tumors (22), cystoadenoma (5), papilloma (4), myoepithelioma (2), hemangioma (01), and epithelioma (1). Those undiagnosed as tumors were mammary hyperplasia (30), necrosis, and suppurative secretion (1). However, the histopathological reports revealed that 62% of the animals had some type of malignant neoplasia.

There was no association between the number of nodules and time of evolution ($r = 0.167$, $p = 0.111$), age at diagnosis and degree of malignancy ($p = 0.109$, $p = 0.409$), pseudocyst and degree of malignancy ($r = 0.131$, $p = 0.355$), or number of nodules and pseudocyst ($p = 0.128$, $p = 0.241$).

There was a strong relationship between malignancy and tumor size ($p = 0.000000000106$), which means that the larger the tumor, the more likely it is to be malignant, with tumors larger than 3 cm having an approximately 70% chance of being malignant. Comparing the groups, Group 1 (0-3 cm) vs. Group 2 (> 3-5 cm) ($p = 0.00000000000000167$), Group 1 (0-3 cm) vs. Group 3 (> 5 cm) ($p = 0.00000000000000000143$), and Group 2 (> 3-5 cm) vs. Group 3 (> 5 cm) ($p = 0.0067$) showed the same relationship, with a significance level of 5%.

It was possible to contact the owners of 66 animals for survival analysis, among which 23 died. The time of contact ranged from 4-21 months after surgery. The cause of death was not defined because none of the animals underwent necropsy. As reported by the owners, eight animals died or were euthanized due to distemper, hemoparasitosis, tracheal collapse, or malignant tumor in another body location. The others died or were euthanized due to respiratory distress. The average survival of animals that died possibly due to mammary tumors was six and a half months.

Discussion

CMTs have a high incidence in female dogs but are rare in male dogs (Daleck et al., 1998; Han et al., 2016; Peleteiro, 1994; Saba et al., 2007;). There is no racial predisposition (Daleck et al., 1998; Peleteiro, 1994; Toríbio et al., 2012); however, according to Misdorp (2002), poodle dogs are the most affected. In this study, CMTs were most common in mixed-breed dogs, followed

by poodles. This is because many mixed-breed and poodle dogs were routinely treated at the VH-UFRRJ.

Middle-aged to older animals are cited as the most predisposed, with an average age of 10/11 years (Daleck et al., 1998; Ežerskytė et al., 2011; Oliveira Filho et al., 2010; Pastor et al., 2018; Toríbio et al., 2012;). In this study, the average age was 10 years, and the age range varied from 4-16 years, similar to those reported in previous literature (Al-Mansour et al., 2018; Cassali et al., 2014; Daleck et al., 1998; MacPhail, 2014; Oliveira Filho et al., 2010; Pastor et al., 2018).

In this study, unlike those reported by Pastor et al. (2018) and Vascellari et al. (2009), no positive correlation was observed between the patients' age at the time of diagnosis and the malignancy of the tumors, consistent with the results of Salas et al. (2015). These discrepancies may be explained by the smaller sample size and the low percentage of benign mammary tumors observed in our study.

According to the literature, animals castrated before the first season have a minimal chance of developing mammary cancer (0,5%); however, the level rose to 8% when dogs were spayed before the second season, with no protective effect on the risk of developing malignant mammary tumors when spayed after the second season (Beaudu-Lange et al., 2021; Gray et al., 2020; Schneider et al., 1969;). The largest blood supply to the mammary glands in the estrogen phase is thought to alter the immune response and cell multiplication (Fergusson, 1985). In this study, most female dogs with breast tumors were either intact or neutered after the second estrus, consistent with the data described in the literature. However, a single animal developed mammary tumor even after being castrated after the first estrus, suggesting that besides the hormonal influence, there are other predisposing factors, such as obesity (Sonnenschein et al., 1991) and diet (Pérez Alenza et al., 1998).

Reproduction is a contributing factor in the development of CMT. Daleck et al. (1998) reported that of the 23 female dogs with a mammary tumor treated at the Veterinary Hospital of Paulista State University in Jaboticabal, more than 78% had reproduced at least once in their lifetime, and half of them had reproduced more than once. According to these authors, the long follicular phase in the female estrous cycle predisposes to breast cancer development when analyzing the effects of steroids on etiopathogenesis. These findings differ from those in this study, as only 32% of the animals had reproduced, and most did so only once. In addition, only 11 animals used contraceptives, and 30% had at least one pseudocyst in the reproductive phase, suggesting that reproductive disorders have little influence on triggering the disease. In addition, it is worth mentioning that most of the owners of the animals that are treated at the VH-UFRRJ had low education and difficulty understanding and evaluating issues such as pseudocyst and heat. Furthermore, many of the animals are raised as backyard animals, which often makes it difficult for the owner to assess reproductive issues.

Consistent with the results of Misdorp (2002), Ežerskytė et al. (2011) and Toríbio et al. (2012), inguinal breasts (79%) were the most affected in this study. According to Misdorp (2002), these glands are most affected by a large amount of parenchyma, predisposing proliferative changes triggered by hormones.

In the TNM classification system of malignant tumors, the level III stage was higher than others (39%), as Toríbio et al. (2012) observed. This may be related to the fact that the VH-UFRRJ provides care mostly to a low-income public, which often takes longer to seek veterinary medical services for their animals. This could explain the slightly more advanced clinical evolution of the disease.

According to the histopathological classification, approximately 62% of the patients had some type of malignant tumor, with adenocarcinomas (a complex carcinoma) being the majority. Toríbio et al. (2012) found a lower frequency of malignancy (39.8%) in dogs treated at the Veterinary Hospital of the Federal University of Bahia, Salvador; however, according to Fergusson (1985), Misdorp et al. (1999), and Lana et al. (2007), the malignant characteristics vary in 50-60% of breast tumors, suggesting that the malignancy rate found in this study is within the expected range. This level of existence can be justified by the late stage of tumor removal, the high number of intact females, and the older age of the spayed animals. Canadas et al. (2019) observed in their study that the most common histopathological type of malignant breast tumors is complex carcinoma, as observed in this study.

The largest tumors were diagnosed as malignant, which is similar to the data reported by Ferreira et al. (2009). Of the 191 histologically evaluated tumors, 63% were smaller than 3 cm; however, statistically, there was a strong association between larger tumor size and malignancy in this study, similar to previous literature (Ferreira et al., 2009; Peleteiro, 1994; Toríbio et al., 2012), suggesting that the larger the tumor, the greater the chance of malignancy.

Sorenmo et al. (2009), comparing tumor size and histological type, concluded that the risk of malignancy increases as the tumor diameter increases and that nodules >3 cm are 70% likely to be malignant. In addition, large, fast-growing, adhered, ulcerated tumors with areas of necrosis or involvement of adjacent skin planes are associated with a poor prognosis and shorter survival time (Peleteiro, 1994; Toríbio et al., 2012). In this study, almost all animals that died of a possible mammary tumor had nodules larger than 4 cm, except for one animal diagnosed with inflammatory carcinoma, whose nodule was only 1.5 cm.

The median survival of animals with mammary cancer and metastasis at diagnosis is 5 months and 20 months for animals without metastasis (De Nardi et al., 2016). In contrast, there are reports of female dogs that underwent surgery and chemotherapy treatment, with a survival of > 360 days (Daleck et al., 1998). In this study, the average survival was 6.5 months, and chemotherapy was performed in only three animals since most owners chose not to or did not return after surgical excision of the tumor. This study analyzed the clinical and epidemiological characteristics of CMTs for a better understanding of the disease's development, thereby contributing to its diagnosis, treatment, and prevention.

Conclusion

Of all the analyses performed in this study, the most prominent was the correlation between tumor size and the degree of malignancy. Therefore, it is possible to conclude that tumors >3 cm are more likely to be malignant.

Acknowledgements

This work was carried out with the support of the Higher Education Personnel Improvement Coordination - Brazil (CAPES) - Financing Code 001.

Ethics statement

The study was approved by the Ethics Committee for Animal Use of UFRRJ (CEUA / UFRRJ) under protocol N° 3029200417.

Financial support

LCO, MESLF and AJRP: Received scholarship from CAPES (Coordenação de Aperfeiçoamento de Pessoal de Nível Superior). CMMC, VAN, FFPCB & SAC: None.

Conflict of interests

LCO, MESLF, AJRP, FFPCB, CMMC, VAN and SAC: No conflict of interest.

Authors' contributions

LCO - Conceptualization, acquisition data, methodology, formal analysis, project administration, investigation, writing, review & editing. MESLF and AJRP - Methodology, acquisition data & critical revision of the manuscript. FFPCB, CMMC and VAN - Methodology, formal analysis, investigation & critical revision of the manuscript. SAC - Conceptualization, acquisition data, methodology, formal analysis, project administration, investigation & critical revision of the manuscript

Availability of complementary results

Online repositories:

- PUBMED: <https://pubmed.ncbi.nlm.nih.gov>

- SciELO: <https://scielo.org>

The study was carried out at Universidade Federal Rural do Rio de Janeiro - UFRRJ, Seropédica, RJ, Brazil.

References

- Al-Mansour, M. A., Kubba, M., Al-Azreg, S. A., & Dribika, S. A. (2018). Comparative histopathology and immunohistochemistry of human and canine mammary tumors. *Open Veterinary Journal*, 8(3), 243-249. <http://dx.doi.org/10.4314/ovj.v8i3.3>. PMID:30105215.
- Beaudu-Lange, C., Larrat, S., Lange, E., Lecoq, K., & Nguyen, F. (2021). Prevalence of reproductive disorders including mammary tumors and associated mortality in female dogs. *Veterinary Sciences*, 8(9), 184. <http://dx.doi.org/10.3390/vetsci8090184>. PMID:34564579.
- Brodey, R. S., Goldschmidt, M. H., & Roszel, J. R. (1983). Canine mammary neoplasms. *Journal of the American Animal Hospital Association*, 19, 61-90.
- Canadas, A., França, M., Pereira, C., Vilaça, R., Vilhena, H., Tinoco, F., Silva, M. J., Ribeiro, J., Medeiros, R., Oliveira, P., Dias-Pereira, P., & Santos, M. (2019). Canine mammary tumors: Comparison of classification and grading methods in a survival study. *Veterinary Pathology*, 56(2), 208-219. <http://dx.doi.org/10.1177/0300985818806968>. PMID:30381007.
- Cassali, G. D., Lavalle, G. E., Ferreira, E., Estrela-Lima, A., De Nardi, A. B. D., Gherver, C., Sobral, R. A., Amorim, R. L., Oliveira, L. O., Sueiro, F. A. R., Baserra, H. E. O., Bertagnolli, A. C., Gamba, C. O., Damasceno, K. A., Campos, C. B., Araujo, M. R., Campos, L. C., Monteiro, L. N., Nunes, F. C., Horta, R. S., Reis, D. C., Luvizotto, M. C. R., Magalhães, G. M., Raposo, J. B., Ferreira, A. M. R., Tanaka, N. M., Grandi, F., Ubukata, R., Batschinski, K., Terra, E. M., Salvador, R. C. L., Jark, P. C., Delecrodi, J. E. R., Nascimento, N. A., Silva, D. N., Silva, L. P., Ferreira, K. C. R. S., Frehse, M. S., Santis, G. W. D., Silva, E. O., Guim, T. N., Kerr, B., Cintra, P. P., Silva, F. B. F., Leite, J. S., Mello, M. F. V., Ferreira, M. L. G., Fukumasu, H., Salgado, B. S., & Torres, R. (2014). Consensus for the diagnosis, prognosis and treatment of canine mammary tumors - 2013. *Brazilian Journal of Veterinary Pathology*, 7(2), 38-69.
- Daleck, C. R., Franceschini, P. H., Alessi, A. C., Santana, A. E., & Martins, I. Z. M. M. (1998). Aspectos clínico e cirúrgico do tumor mamário canino. *Ciência Rural*, 30, 731-735.
- De Nardi, A. B., Ferreira, T. M. M. R., & Assunção, K. A. (2016). Neoplasias mamárias. In C. B. Daleck & De Nardi, A. B. (Eds.). *Oncologia em Cães e Gatos* (2. ed., pp.499-507). Roca.
- Ežerskytė, A., Zamokas, G., Grigonis, A., & Juodžiukynienė, N. (2011). The retrospective analysis of mammary tumors in dogs. *Veterinarija ir Zootechnika*, 53(75), 3-8.
- Fergusson, H. R. (1985). Canine mammary gland tumors. *The Veterinary Clinics of North America. Small Animal Practice*, 15(3), 501-511. [http://dx.doi.org/10.1016/S0195-5616\(85\)50053-4](http://dx.doi.org/10.1016/S0195-5616(85)50053-4). PMID:3892866.
- Ferreira, E., Bertagnolli, A. C., Cavalcanti, M. F., Schmitt, F. C., & Cassali, G. D. (2009). The relationship between tumour size and expression of prognostic markers in benign and malignant canine mammary tumours. *Veterinary and Comparative Oncology*, 7(4), 230-235. <http://dx.doi.org/10.1111/j.1476-5829.2009.00193.x>. PMID:19891693.
- Gray, M., Meehan, J., Martínez-Pérez, C., Kay, C., Turnbull, A. K., Morrison, L. R., Pang, L. Y., & Argyle, D. (2020). Naturally-occurring canine mammary tumors as a translational model for human breast cancer. *Frontiers in Oncology*, 10, 617. <http://dx.doi.org/10.3389/fonc.2020.00617>. PMID:32411603.
- Han, J. H., Kim, K. S., & Kim, J. H. (2016). Mammary gland tumors in three male dogs. *Korean Journal of Veterinary Research*, 56(4), 229-232. <http://dx.doi.org/10.14405/kjvr.2016.56.4.229>.
- Lana, S. E., Rutterman, G. R., & Withrow, S. J. (2007). Tumors of the mammary gland. In S. J. Withrow & D. M. Vail (Eds.). *Small Animal Clinical Oncology* (4th ed., pp. 619-636). Saunders. <http://dx.doi.org/10.1016/B978-072160558-6.50029-0>.
- MacPhail, C. M. (2014). Cirurgia do sistema reprodutivo e genital. In T. W. FOSSUM (Ed.), *Cirurgia de Pequenos Animais* (4. ed., pp. 809-815). Elsevier.
- Misdorp, W. (2002). Tumors of the mammary gland. In: D. J. MEUTEN (Ed), *Tumors in Domestic Animals* (4nd ed., pp.575-606). Ames.
- Misdorp, W., Else, R. W., & Hellmén, E. (1999). Definitions and explanatory notes. In W. Misdorp (Ed.), *Histological Classification of Mammary Tumors of the Dog and Cat* (pp. 18-27). Armed Forces Institute of Pathology.
- Moe, L. (2001). Population-based incidence of mammary tumours in some dog breeds. *Journal of Reproduction and Fertility. Supplement*, 57, 439-443. PMID:11787188.
- Morris, J. S., Bostock, D. E., McInnes, E. F., Hoather, T. M., & Dobson, J. M. (2000). Histopathological survey of neoplasms in flat-coated retrievers, 1990 to 1998. *The Veterinary Record*, 147(11), 291-295. <http://dx.doi.org/10.1136/vr.147.11.291>. PMID:11037728.
- Oliveira Filho, J. C., Kommers, G. D., Masuda, E. K., Marques, B. M. F. P. P., Figuera, R. A., Irigoyen, L. F., & Barros, C. S. L. (2010). Estudo retrospectivo de 1.647 tumores mamários em cães. *Pesquisa Veterinária Brasileira*, 30(2), 177-185. <http://dx.doi.org/10.1590/S0100-736X2010000200014>.
- Owen, L. N. (1980). *TNM Classification of Tumor in Domestic Animals* (p. 53). World Health Organization.
- Papazoglou, L. G., Basdani, E., Rabidi, S., Patsikas, N. M., & Karayiannopoulou, M. (2014). Current surgical options for mammary tumor removal in dogs. *Journal of Veterinary Sciencee Medicine*, 2(1), 1-6.

- Pastor, N., Caballé, N. C., Santella, M., Ezquerro, L. J., Tarazona, R., & Duran, E. (2018). Epidemiological study of canine mammary tumors: Age, breed, size and malignancy. *Australian Journal of Veterinary Science*, 50(3), 143-147. <http://dx.doi.org/10.4067/S0719-81322018000300143>.
- Peleteiro, M. C. (1994). Tumores mamários na cadela e na gata. *Revista Portuguesa de Ciências Veterinárias*, 89, 10-29.
- Pérez Alenza, D., Rutteman, G. R., Peña, L., Beynen, A. C., & Cuesta, P. (1998). Relation between habitual diet and canine mammary tumors in a case-control study. *Journal of Veterinary Internal Medicine*, 12(3), 132-139. <http://dx.doi.org/10.1111/j.1939-1676.1998.tb02108.x>. PMID:9595373.
- Queiroga, F., & Lopes, C. (2002). Canine mammary tumors: New perspectives. In: *Proceedings of the Veterinary Sciences Congress* (pp. 183-190). SPCV.
- Rivera, P., & Von Euler, H. (2011). Molecular biological aspects on canine and human mammary tumors. *Veterinary Pathology*, 48(1), 132-146. <http://dx.doi.org/10.1177/0300985810387939>. PMID:21147766.
- Saba, C. F., Rogers, K. S., Newman, S. J., Mauldin, G. E., & Vail, D. M. (2007). Mammary gland tumors in male dogs. *Journal of Veterinary Internal Medicine*, 21(5), 1056-1059. <http://dx.doi.org/10.1111/j.1939-1676.2007.tb03064.x>. PMID:17939564.
- Salas, Y., Márquez, A., Diaz, D., & Romero, L. (2015). Epidemiological study of mammary tumors in female dogs diagnosed during the period 2002-2012: A growing animal health problem. *PLoS One*, 10(5), e0127381. <http://dx.doi.org/10.1371/journal.pone.0127381>. PMID:25992997.
- Schneider, R., Dorn, C. R., & Taylor, D. (1969). Factors influencing canine mammary cancer development and postsurgical survival. *Journal of the National Cancer Institute*, 43(6), 1249-1261. PMID:4319248.
- Sonnenschein, E. G., Glickman, L. T., Goldschmidt, M. H., & McKee, L. J. (1991). Body conformation, diet, and risk of breast cancer in pet dogs: A case-control study. *American Journal of Epidemiology*, 133(7), 694-703. <http://dx.doi.org/10.1093/oxfordjournals.aje.a115944>. PMID:2018024.
- Sorenmo, K. (2003). Canine mammary gland tumors. *The Veterinary Clinics of North America: Small Animal Practice*, 33(3), 573-596. [http://dx.doi.org/10.1016/S0195-5616\(03\)00020-2](http://dx.doi.org/10.1016/S0195-5616(03)00020-2). PMID:12852237.
- Sorenmo, K. U., Kristiansen, V. M., Cofone, M. A., Shofer, F. S., Breen, A., Langeland, M., Mongil, C. M., Grondahl, A. M., Teige, J., & Goldschmidt, M. H. (2009). Canine mammary gland tumours; a histological continuum from benign to malignant; clinical and histopathological evidence. *Veterinary and Comparative Oncology*, 7(3), 162-172. <http://dx.doi.org/10.1111/j.1476-5829.2009.00184.x> PMID:19691645.
- Toribio, J. M. M. L., Lima, A. E. L., Martins Filho, E. F., Ribeiro, L. G. R., D'Assis, M. J. M. H., Teixeira, R. G., Damasceno, K. A., Cassali, G. D., & Costa Neto, J. M. (2012). Caracterização clínica, diagnóstico histopatológico e distribuição geográfica das neoplasias mamárias em cadelas de Salvador, Bahia. *Revista Ceres*, 59(4), 427-433. <http://dx.doi.org/10.1590/S0034-737X2012000400001>.
- Vascellari, M., Baioni, E., Ru, G., Carminato, A., & Mutinelli, F. (2009). Animal tumour registry of two provinces in northern Italy: Incidence of spontaneous tumors in dogs and cats. *BMC Veterinary Research*, 5(39), 39. <http://dx.doi.org/10.1186/1746-6148-5-39>. PMID:19825169.