




Feline intraocular sarcoma: case report

Sarcoma intraocular felino: relato de Caso

Isabela Pessôa Barbieri Bastos¹ , Camila Valério Baruel¹ , Thais Fontes Braga² , Rayssa Dias Faleiro¹ , Renan Schiebel Medeiros¹  & Leonardo Rodrigues de Lima³ 

¹Veterinarian, autonomous, Rio de Janeiro, RJ, Brasil.

²Veterinarian, Resident. Programa de Residência em Oftalmologia em Animais de Companhia, Departamento de Medicina e Cirurgia Veterinária – DMCV, Instituto de Veterinária – IV, Universidade Federal do Rio de Janeiro – UFRJ, Seropédica, RJ, Brasil

³Veterinarian, DSc. DMCV, IV, UFRJ, Seropédica, RJ, Brasil, RJ, Brasil

Abstract

Ophthalmic disorders in cats are increasingly common in veterinarians' professional routine. Eye neoplasms are important diseases that can lead to discomfort, visual loss and death. Feline intraocular sarcoma is a malignant neoplasm that can be diagnosed in cats of any age. In this report, a 6-month-old female cat was treated at the Veterinary Hospital of Federal Rural University of Rio de Janeiro, with the left eyeball in the *phthisis bulbi* stage resulting from a traumatic event four months previously. Enucleation surgery for the affected eye was performed. The histopathological evaluation of the eyeball revealed early-stage intraocular sarcoma.

Keywords: neoplasm, ophthalmology, histopathology.

Resumo

As afecções oftálmicas em gatos estão cada vez mais presentes na rotina profissional do médico veterinário. As neoplasias oculares são importantes enfermidades que podem levar ao desconforto, perda visual e riscos a vida do paciente. O sarcoma intraocular felino é uma neoplasia maligna e pode ser diagnosticada em gatos de qualquer faixa etária. No presente relato, um felino, fêmea com 6 meses de idade foi atendido no Hospital Veterinário da Universidade Federal Rural do Rio de Janeiro, no serviço de Oftalmologia, apresentando bulbo ocular esquerdo em estágio de *phthisis bulbi* decorrente de um evento traumático há 4 meses. Foi indicada cirurgia de enucleação do olho afetado. Na avaliação histopatológica do bulbo ocular foi revelado o diagnóstico de sarcoma intraocular felino em estágio inicial.

Palavras-chave: neoplasia, oftalmologia, histopatologia.

Introduction

Intraocular neoplasms are important diseases in veterinary ophthalmology. Its occurrence can impair not only the animal's vision, but also its life expectancy. Post-traumatic feline eye sarcoma, also known as feline intraocular sarcoma, is a malignant neoplasm that is often associated with trauma or chronic eye inflammation (Perlmann et al., 2011).

This neoplasm is extremely aggressive, with high infiltrative capacity in intraocular structures, distant metastasis and high rates of recurrence (Dubielzig et al., 1990; Stoltz et al., 1994; Zeiss et al., 2003) The origin of post-traumatic sarcoma is still uncertain, but it has been suggested that epithelial cells of the lens, after an episode of capsular rupture, proliferate uncontrollably and develop the mesenchymal phenotype (Dubielzig et al., 1990; Wilcock, 2007; Grahn et al., 2018;).

Feline intraocular sarcoma can develop months or years after the traumatic event, involving clinical signs such as buftalmia, chronic uveitis and red eye, in addition to developing in eyes with a history of *phthisis bulbi* (Dubielzig et al., 2010; Perlmann et al., 2011; Slatter, 2013). The diagnosis is made based on histopathological examination after enucleation and its prognosis is nearly always unfavorable (Allgoewer, 2009). Here we report a case of post-traumatic ocular sarcoma in a cat.

Case report

A six months mixed-breed female cat with a history of being hit by a car four months before being presented. According to the owner, the accident involved eye trauma that progressed to an intense increase in the left eyeball and loss of corneal transparency. An external veterinarian prescribed



How to cite: Bastos, I. P. B., Baruel, C. V., Braga, T. F., Faleiro, R. D., Medeiros, R. S., & Lima, L. R. (2020). Feline intraocular sarcoma – Case report. *Brazilian Journal of Veterinary Medicine*, 42, eLocation. [[Q1: Q1]] <http://dx.doi.org/10.29374/2527-2179.bjvm106920>

Conflict of interests: No conflict of interests declared concerning the publication of this article.


Received: July 30, 2019

Accepted: September 16, 2020

The study was carried out at Hospital Veterinário, Universidade Federal Rural do Rio de Janeiro – UFRJ, Seropédica, RJ, Brasil, setor de pequenos animais, serviço de Oftalmologia.

*Correspondence

Isabela Pessôa Barbieri Bastos
Rua Dr. Anibal Moreira, 115A, Bloco 5, Ap 101
CEP 20510-110 - Tijuca (RJ), Brasil
E-mail: isabelapbbastos@gmail.com

 Copyright Bastos et al. This is an Open Access article distributed under the terms of the Creative Commons Attribution Non-Commercial License which permits unrestricted non-commercial use, distribution, and reproduction in any medium provided the original work is properly cited.

systemic antibiotics, analgesics and eye drops, but the owner did not know the name of the products. The eye gradually decreased in size and the animal was referred to the ophthalmology service.

Ophthalmic examination with the aid of a magnifying glass and Finoff transilluminator showed reduced size of the left eye and intense hypotonia, which was not measurable in an applanation tonometer (TonoPen vet®). Threat response and pupillary reflex to negative light revealed an opaque cornea, but it was not possible to evaluate the anterior chamber, lens and iris. The fundoscopic examination was also impossible due to the condition. *Phthisis bulbi* of the left eye was diagnosed, with no signs of discomfort or irritation. The ophthalmic examination was also performed on the other eye, which did not present any changes. Enucleation of the left eyeball was indicated.

Between the preoperative evaluation period and the moment of surgery, an increase in the volume of the left eyeball and intense corneal deformity were noted (Figure 1). The eyeball was surgically removed by the enucleation procedure (Figure 2) and sent for histopathological examination. Macroscopic examination revealed a phthisical ocular bulb with a brownish-yellow mass in the cornea and retinal detachment. Microscopic examination revealed proliferation of spindle cells with elongated nuclei and dense chromatin in the cornea and anterior chamber (Figure 3). The other intraocular structures were not subjected to evaluation, given the severe tissue destruction. The diagnosis was feline post-traumatic sarcoma at an early stage.

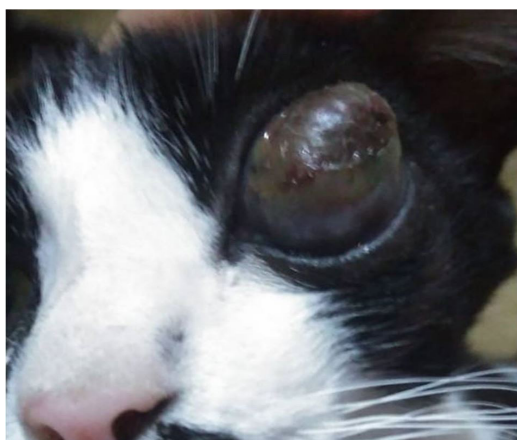


Figure 1. Female mixed-breed cat, six months old, showing enlargement in the left eyeball, with corneal deformity and opacity.




Figure 2. Female mixed-breed cat 10 days after left eyeball enucleation surgery.

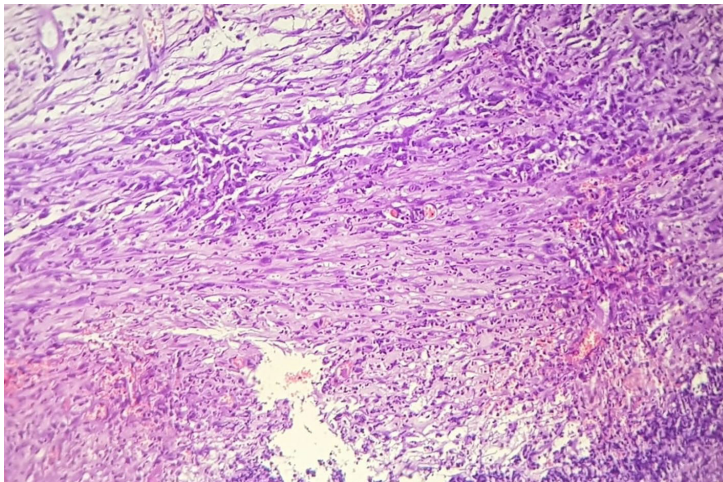


Figure 3. Histological section of the left eyeball showing neoplastic proliferation composed primarily of spindle cells with elongated nuclei and dense chromatin. Hematoxylin-eosin staining. 40x objective.

Discussion

Traumatic injuries in cats are commonly associated with falls, fights or traffic accidents, as the case reported here (Herrera, 2008).

The ocular trauma caused by being hit by a car reinforces the etiology of the formation of post-trauma neoplasm, or even chronic inflammation, due to the time that elapsed until the moment of enucleation, including *phthisis bulbi*. This corroborates the hypothesis that the formation of neoplasm manifests itself after chronic inflammation (Perlmann et al., 2011).

The increase in volume and corneal deformity observed in the days leading to enucleation surgery signaled that important intraocular changes were happening. This fact reinforced the hypothesis of the development of feline intraocular sarcoma (Dubielzig et al., 2010), confirmed later by histopathology.

Daleck & De Nardi (2016) discuss cases involving, besides inflammation, changes in the genome of cats that present sarcoma by application. This could also be a hypothesis in cases of feline intraocular sarcoma, taking into account what the authors say about inflammation related to the sarcoma by application, where the inflammation triggers massive release of cytokines that can influence carcinogenesis.

Another hypothesis is that post-traumatic intraocular sarcoma may be related to lens capsular rupture, with transformation of the lens epithelial cells in these cases, as mentioned by Grahn et al. (2018). In the case described here, the evaluation of some intraocular structures was impaired due to severe tissue destruction, the lens being one of these structures. Therefore, it was not possible to establish a connection between this case and the suggested hypothesis.

Zeiss et al. (2003) cited the malignant transformation of the lenticular epithelium as a differential for classification of intraocular sarcoma. The reason is that although most cases of intraocular sarcomas are pure mesenchymal neoplasms, there are still different morphological diagnoses, among them leiomyosarcoma of the muscles of the iris and ciliary body, and more rarely anaplastic carcinoma of the epithelium of the ciliary body. In the case described here, an immunohistochemistry test would have enabled a more accurate diagnosis, but the animal's owner did not authorize it.

Most animals do not show signs of pain or irritation in these conditions, so many cases of phthisical eyes are not monitored or subjected to early enucleation, as occurred in here. However, according to Perlmann et al. (2011), animals have presented *phthisis bulbi* for years before the diagnosis of advanced intraocular sarcoma.

According to Dubielzig (2011), the trend for the occurrence of intraocular neoplasms in general, including post-traumatic sarcoma, occurs in cats from 10.6 years of age. However, in this case the cat was only six months old, indicating that even kittens and juveniles can develop sarcoma.

Conceição et al. (2010) stated that primary ocular neoplasms have low metastatic potential at a distance, but Dubielzig et al. (1990), Stoltz et al. (1994) and Zeiss et al. (2003) all described intraocular sarcoma as potentially metastatic.

In general, sarcomas have a high rate of local recurrence, so aggressive surgery is indicated. The recommended surgical margin is at least 3 cm, but the ideal margin is least 5 cm (Daleck & De Nardi, 2016). In cases of intraocular sarcoma or other ocular neoplasms, there is no wide margin for removal. The reason is that most surgically accessible eye structures are limited to the interior of the orbit, and even the orbit itself. Therefore, early diagnosis is necessary. Dubielzig et al. (1990) cited complications such as blindness and neurological signs caused by neoplastic infiltration through the optic nerve, optic chiasm and brain, diagnosed after euthanasia.

Conclusion

In the case described, enucleation occurred only four months after the traumatic event, but even so the diagnosis was of sarcoma at an early stage. Therefore, the clinical suspicion of intraocular sarcoma should be considered in cats with *phthisis bulbi*, especially after a traumatic event. In these cases, enucleation should be considered as a therapeutic approach to prevent the development of sarcoma, which is extremely aggressive and has high metastatic potential.

References

- Allgoewer, I. (2009, Oct. 2-4) Ocular tumors. In *Proceedings of the SEVC Southern European Veterinary Conference*. Barcelona, Spain: SEVC.
- Conceição, L. F. D., Ribeiro, A. P., Piso, D. Y. T., & Laus, J. L. (2010). Considerations about ocular neoplasia of dogs and cats. *Ciência Rural*, 40(10), 2235-2242. <http://dx.doi.org/10.1590/S0103-84782010005000165>.
- Daleck, C. R., & De Nardi, A. B. (2016). *Oncologia em cães e gatos*. São Paulo: Grupo Gen-Editora Roca Ltda.
- Dubielzig, R. R. (2011). Ocular and periocular tumors in cats. In *Proceedings of the 36th World Small Animal Veterinary Congress WSAVA* (pp. 14-17). Canada: WSAVA.
- Dubielzig, R. R., Everitt, J., Shaddock, J. A., & Albert, D. M. (1990). Clinical and morphologic feature of post-traumatic ocular sarcoma in cats. *Veterinary Pathology*, 27(1), 62-65. <http://dx.doi.org/10.1177/03009858900270011>. PMID:2309385.
- Dubielzig, R. R., Ketring, K. L., McLellan, G. J., & Albert, D. M. (2010). *Veterinary ocular pathology* E-book: a comparative review. USA: Elsevier Health Sciences.
- Grahn, B., Peiffer, R., & Wilcock, B. (2018). *Histologic basis of ocular disease in animals*. Nova Jersey: John Wiley & Sons. <http://dx.doi.org/10.1002/9781119108603>.
- Herrera, D. (2008). *Oftalmologia em animais de companhia*. São Paulo: MedVep.
- Perlmann, E., Rodarte-Almeida, A. C. V., Albuquerque, L., Safatle, A. M. V., Pigatto, J. A. T., & Barros, P. S. M. (2011). Feline intraocular sarcoma associated with *phthisis bulbi*. *Arquivo Brasileiro de Medicina Veterinária e Zootecnia*, 63(3), 591-594. <http://dx.doi.org/10.1590/S0102-09352011000300009>.
- Slatter, D. H. (2013). *Fundamentos de oftalmologia veterinária*. São Paulo: Roca.
- Stoltz, J. H., Carpenter, J. L., Albert, D. M., Vainisi, S. J., & Munn, R. J. (1994). Histologic, immunohistochemical, and ultrastructural features of an intraocular sarcoma of a cat. *Journal of Veterinary Diagnostic Investigation*, 6(1), 114-116. <http://dx.doi.org/10.1177/104063879400600124>. PMID:8011767.