










EVALUATION OF APICAL TRANSPORTATION AND APICAL ROOT SEALING IN ROOT CANALS PREPARED WITH MTWO ROTARY SYSTEM WITH AND WITHOUT APICAL ENLARGEMENT – AN *IN VITRO* STUDY

Matheus Albino SOUZA¹ , João Paulo DE CARLI² , Fernando Tolfo RODRIGUES³ , Larissa PIUCO³ ,
Karolina Frick BISCHOFF⁴ , Juliane BERVIAN⁵ , Julia ZANDONÁ⁶ , Estela Marta Doffo WINOCUR⁷ ,
Adriana de Jesus SOARES⁷ 

¹ Department of Endodontics, School of Dentistry, University of Passo Fundo, Passo Fundo, Rio Grande do Sul, Brazil.

² Department of Oral Medicine, School of Dentistry, University of Passo Fundo, Passo Fundo, Rio Grande do Sul, Brazil.

³ School of Dentistry, University of Passo Fundo, Passo Fundo, Rio Grande do Sul, Brazil.

⁴ Postgraduate Program in Dentistry, School of Dentistry, University of Passo Fundo, Passo Fundo, Rio Grande do Sul, Brazil.

⁵ Department of Pediatric Dentistry, School of Dentistry, University of Passo Fundo, Passo Fundo, Rio Grande do Sul, Brazil.

⁶ Department of Dental Materials, School of Dentistry, Federal University of Rio Grande do Sul, Porto Alegre, Rio Grande do Sul, Brazil.

⁷ Department of Restorative Dentistry, School of Dentistry of Piracicaba, State University of Campinas, Piracicaba, São Paulo, Brazil.

Corresponding author:

João Paulo De Carli

Email: joaodecarli@upf.br

How to cite: SOUZA, M.A., et al. Evaluation of apical transportation and apical root sealing in root canals prepared with MTwo rotary system with and without apical enlargement – an *in vitro* study. *Bioscience Journal*. 2021, **37**, e37004. <https://doi.org/10.14393/BJ-v37n0a2021-56141>

Abstract

The aim of this study was to evaluate apical transportation and apical root canal sealing after root canal filling in human teeth prepared with MTwo® Rotary System with and without apical foramen enlargement. Twenty mandibular premolars were divided into two groups (n=10). Group 1 had root canals prepared 1mm beyond the apical foramen. Group 2 had root canals prepared 1mm below the root canal length. After chemo-mechanical preparation, samples were submitted to scanning electronic microscopy. Apical foramen images had 75x magnification at standardized positions, allowing measurements from the apical foramen area before and after root canal preparation, and after root canal filling. Apical foramen shape and apical transportation, as well as its level of circumferential filling after root canal preparation were accessed using the Image Subtraction System. Scanning electronic microscopy analysis demonstrated that samples of Group 1 showed larger foraminal diameter than samples of Group 2 ($p<0.05$). Apical foramen transportation was statistically different between Groups 1 and 2 ($p=0.0108$). Furthermore, the apical foramen sealing also differed statistically between groups 1 and 2 ($p=0.0007$) and 100% of samples of Group 1 showed apical root canal sealing. Apical root canal sealing was more effective when the root canal was prepared with apical foramen enlargement, even when the apical transportation was detected.

Keywords: Apical Foramen. Enlargement. Instrumentation. Root Canal Obturation.

1. Introduction

The apical limit of root canal instrumentation and filling is one of the major controversial issues in Endodontics (Negishi et al. 2005). The maintenance of the pulp stump in teeth with vital pulp and the possibility of injury to apical and periapical tissues have supported the principle of the working length to remain up to 1-2 mm from the radiographic apex (Ricucci and Langeland 1998; Holland et al. 2005). However, it is known that this area has physical space enough to host significant amount of microorganisms. Furthermore, the apical third of root canals associated to the periapical lesion, including cemental canal, shows high infection percentage, with predominance of anaerobic bacteria (Brandão et al. 2019).

The success predictability of the root canal therapy does not depend only on the quality of instrumentation and filling, but also on complete elimination of organic substrate and microorganisms from the root canal, including the apical foramen area (Schilder 2006; Silva et al. 2016). According to previous study, maintaining the patency of the apical foramen prevents the accumulation of pulp and dentinal debris, which can induce apical blockage, deviation, apical zip and root perforation (Mohammadi et al. 2017). In addition, this step aids the penetration of irrigant solution in the apical third, enabling the tridimensional filling of the root canal (Buchanan 2000; Schilder 2006). Thus, adequate apical sealing has the purpose of preventing reinfection and percolation of periapical fluids toward the root canal.

The apical third can be considered a critical area, because the apical diameter shows high variation in all dental groups (Wu et al. 2000). Cases of periapical lesion, recognizing the presence of microorganisms in the cemental canal and even in the lesion itself (Brandão et al. 2019), have contributed to spread the acceptance of cleaning and enlargement of the apical foramen during root canal therapy.

The preparation of apical third root canals with larger diameter showed better periapical repair and microbial reduction according to previous studies (Card et al. 2002; Rollison et al. 2002; Usman et al. 2004; Jara et al. 2018; Brandão et al. 2019). However, there is no consensus on any technique that results in complete cleaning of the apical third (Tan and Messer 2002). In addition, the diameter of the apical foramen, as well as the filling level of the root canal, represents an important aspect to be considered when assessing the growth of conjunctive tissue within the root canal and periapical repair after root canal therapy (Brandão et al. 2019).

The aim of this study was to evaluate apical transportation and apical root canal sealing after root canal filling in human teeth prepared with MTwo® Rotary System, with and without apical foramen enlargement.

2. Material and Methods

Specimen preparation

This study was submitted to the Science and Ethics Commission. Teeth were stored in 0.02% thymol solution and autoclaved before use. Twenty freshly extracted human lower premolar teeth with similar root segments and fully developed apices were selected. Root surfaces were examined for the absence of fracture lines or anatomic irregularities and were discarded if any of these features were found. All teeth were extracted from patients aged 20-50 years with no initial endodontic treatment. Each tooth was decoronated below the cemento-enamel junction perpendicular to the longitudinal axis using a slow-speed, water-cooled diamond disc (Isomet 2000; Buehler Ltd, Lake Bluff, IL). Roots were cut to uniform length of 13 mm from the root apex. After procedures, root canals were irrigated with distilled water and the pulp tissue was removed with #15 K-file (Maillefer, Ballaigues, Switzerland). Samples were dried and stored in incubator for 24 hours at 38 °C.

SEM image records – pre-instrumentation

Roots were placed in metal deck containing 20 similar cells, 8 mm in diameter and 9 mm in depth in order to promote the standardization of images. The coronal portion of roots was placed into cells so that the apical foramen remains upturned. After root placement, cells were filled with epoxy resin in order to promote sample fixation. During sample fixation, only a slight pressure was applied in order to prevent the epoxy resin from invading the apical foramen, with enough space to perform instrumentation in the desired working length.

Samples were coated with gold and image acquisition was performed under scanning electronic microscopy (SEM) (JEOL – JSM 5600LV, Tokyo, Japan). Image records were made at 75x magnification in order to promote the record of the original morphology from the apical foramen.

Chemomechanical preparation and SEM image records - post-instrumentation and post-filling

Firstly, the cervical and middle thirds of each sample were prepared. Largo #2 (Dentsply-Maillefer, Ballaigues, Switzerland), Hero 20.06 (Micro-mega, Rio de Janeiro, RJ, Brazil) and Gates-Glidden #5, #4, #3 and #2 (Dentsply-Maillefer, Ballaigues, Switzerland) were used to prepare these thirds. 2% chlorhexidine gel

was used as chemical auxiliary and irrigation with 5 ml of 0.9% saline solution was performed after the use of each instrument.

Samples were randomly divided into 2 groups (n=10) according to working length and apical foramen enlargement. The first specimen was randomly chosen from all specimens and assigned to group 1, the second specimen to group 2, and so on. The distribution was repeated until each group presented the complete number of specimens. This number of samples was based on previous study of systematic literature review that comprises a series of reviewed studies with similar number of samples (Sousa-Neto et al. 2018).

In group 1, the working length was established 1mm beyond the apical foramen and samples were prepared using Mtwo rotary nickel-titanium instruments (VDW, Munich, Germany) at constant speed of 350 rpm up to #40.04 file, promoting enlargement of the apical foramen. Patency was performed by inserting #10 K-file (Dentsply-Maillefer, Ballaigues, Switzerland) into the canal up to the moment its tip was seen in the apical foramen, between each instrument, in order to prevent blockage of the apical third. Final irrigation with 2 mL of 17% EDTA (Essential-Pharma, Piracicaba, Brazil) for 3 minutes followed by irrigation with 5 mL of 0.9% saline solution was performed in order to remove the smear layer. Subsequently, all canals were dried with sterile paper points to conclude the protocol.

After chemomechanical preparation, samples were coated with gold and image acquisition was performed at 75x magnification in order to promote the record of morphology from the apical foramen after instrumentation.

Then, samples were filled with single medium gutta-percha point (Odous de Deus, Belo Horizonte, Brazil) and Pulp Canal Sealer (Sybron-Endo, Orange, USA), previously calibrated by the operator. The limit used for locking the gutta-percha point was 1 mm from the apical foramen. The Touch and Heat system (Analytic Technology, Redmont, USA) was used to cut the filling material, followed by vertical compression with Medium cold plugger (Odous de Deus, Belo Horizonte, Brazil).

In group 2, the working length was established 1mm from the apical foramen and chemomechanical preparation, image acquisition after instrumentation and root canal filling were performed on the same way as described in group 1.

After root canal filling, samples of both groups were sealed using Coltosol (Vigodent, Rio de Janeiro, Brazil). Samples were coated for the last time with gold and submitted to SEM, recording images at 75x magnification and promoting the record of morphology from the apical foramen after root canal filling.

Comparative evaluation method of SEM images

Recorded images were evaluated using computer system (Emago, Amsterdam, Netherland), which provides overlap of photomicrographs and allows the identification of differences between them through process called Image Subtraction. This process was based on and adapted from previous studies of Silva-Santos et al. (2018), allowing the standardization of measurements from evaluated areas.

Two subtractions were performed. The first subtraction was performed by overlapping images from pre-instrumentation and post-instrumentation of both groups. The second subtraction was performed by overlapping images from post-instrumentation and post-filling of both groups.

The comparison of the diameter of apical foramens was performed through measurements of the apical foramen area before and after instrumentation. The apical transportation evaluation after root canal instrumentation was performed by scores, being (0) absence of apical transportation and (1) presence of apical transportation.

The area filled with endodontic filling material was also measured in both groups. In this case, after image subtraction analysis, the apical sealing was evaluated in a dichotomous way: if sealed (yes) or not sealed (no). For that, the sealing surface of the apical foramen corresponding to the area associated with the adjacent external surfaces covered by the extrusion of filling material was considered. Apical transportation and apical sealing were assessed by two previously blinded and calibrated examiners. The inter-examiner's reliability was determined using the Kappa's coefficient test.

Statistical analysis

One-way ANOVA was applied to compare the diameter of the apical foramen in both groups, before and after instrumentation, followed by Tukey's post hoc procedure, at 5% significance level.

Fisher's test was applied to compare the apical transportation in both groups. Fisher's test, followed by Student's t-test, was applied to compare the apical sealing in both groups.

3. Results

The Kappa coefficient test indicated agreement between examiners for data interpretation (Kappa=0.923). Means and standard deviations from measurements of the apical foramen area in both groups detected before and after root canal preparation are shown in Table 1. There was no statistically significant difference between groups before root canal preparation ($p>0.05$), but statistically significant difference was observed between groups after root canal preparation ($p<0.05$).

Table 1. Means and standard deviations from measurements of the apical foramen area in both groups detected before and after root canal preparation.

Groups	Apical foramen area (mm ²)	
	Pre-instrumentation	Post-instrumentation
Group 1 Foraminal enlargement (n=10)	5.17 (± 0.92) Ab	8.99 (± 1.17) Aa
Group 2 No foraminal enlargement (n=10)	4.83 (± 1.20) Aa	5.63 (± 1.07) Ba

Distinct upper case letters in the column and distinct lower case letters in the line indicate statistically significant difference at 5% level.

Data regarding the apical transportation in both groups are shown in Table 2 and illustrated in Figure 1. There is no statistically significant difference between groups after root canal preparation ($p<0.05$), with higher apical transportation percentage in Group 1.

Table 2. Data regarding apical transportation in both groups.

Groups	Apical transportation scores after root canal preparation		"p" value
	Absent	Present	
Group I Foraminal enlargemet (n=10)	4	6	0.0108
Grupo II No foraminal enlargement (n=10)	10	0	----

"p" value obtained by Fisher's Test ($\alpha=0.05$).

Means and standard deviations of the apical foramen sealing in both groups are shown in Table 3 and illustrated in Figure 2, as well as the apical sealing percentage. There was no statistically significant difference between groups after root canal filling ($p<0.05$), with higher apical sealing percentage in Group 1.

Table 3. Means and standard deviations, and apical foramen sealing percentage in both groups.

Groups	Apical foramen filling (total area) (mm ²)	Apical sealing n (%)
Group 1 Foraminal enlargement (n=10)	29.95 (± 5.21) A	10 (100%)
Group 2 No foraminal enlargement (n=10)	6.79 (± 12.38) B	2 (20%)

Distinct upper case letters in the column indicate statistically significant difference at 5% level.

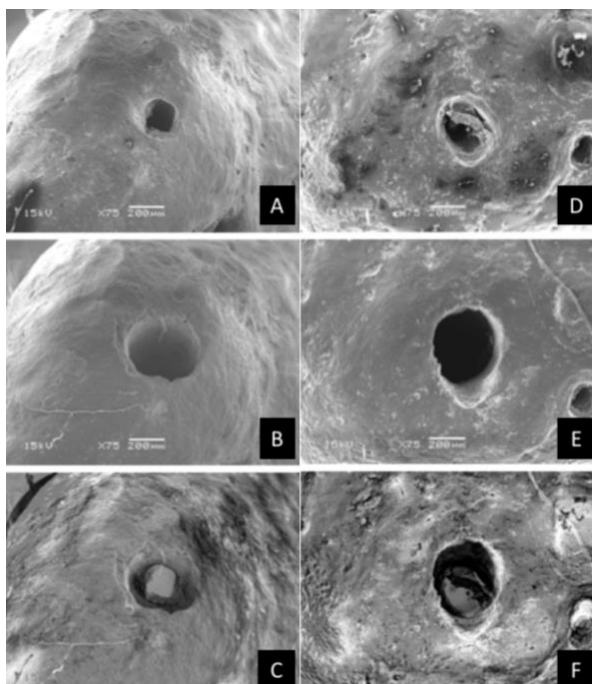


Figure 1. Photomicrographs revealing apical transportation in both groups. A – initial photomicrograph of G2; B – after preparation with no foraminal enlargement; C – subtraction of images; D - initial photomicrograph of G1; E – after preparation with foraminal enlargement; F – subtraction of images.

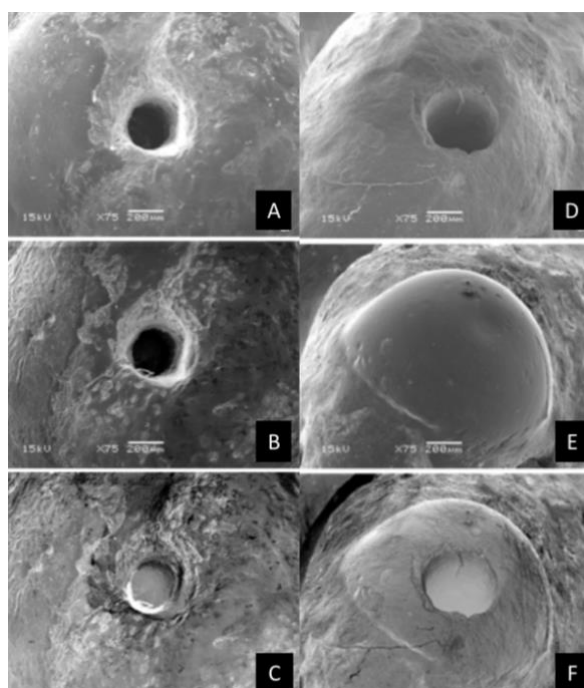


Figure 2. Photomicrographs revealing apical foramen sealing in both groups. A – initial photomicrograph of G2; B – after sealing with no foraminal enlargement; C – subtraction of images; D - initial photomicrograph of G1; E – after sealing with foraminal enlargement; F – subtraction of images.

4. Discussion

The success of endodontic treatment is based on adequate disinfection and tridimensional filling of the root canal system (Souza 1998). According to literature, the selection of the site defined to finish the chemomechanical preparation is controversial and there is no consensus about this location. There are some authors who support pulp stump maintenance and preservation of periapical tissues (Ricucci and Langeland 1998; Holland et al. 2005). On the other hand, other authors report that enlargement of the apical foramen is necessary to obtain adequate repair of periapical tissues (Souza 1998; Mounce 2005).

The literature reports different working lengths, being 1mm from the apical foramen the most common. According to this concept, the cemental canal should not be instrumented (Ricucci and Langeland

1998; Ricucci 1998). However, the absence of cleaning and organic tissue remnants could be observed in previous studies, when chemomechanical preparation was performed 1mm from the apical foramen (Wu et al. 2000; Wu et al. 2002). On the other hand, some studies revealed some undesirable apical enlargement effects such as higher postoperative pain (Silva et al. 2017), higher extrusion of debris and filling material (Albuquerque et al. 2020), higher apical deviation (Silva et al. 2016) and foraminal deformation (Silva-Santos et al. 2018). In the present study, apical morphology modification and apical transportation were evaluated after the use of two root canal preparation techniques, with or without apical foramen enlargement, followed by apical sealing evaluation after root canal sealing.

According to the protocol used in this study, the apical instrumentation limit was established 1mm from the apical foramen for Group 1. In this case, the samples were prepared using rotary nickel-titanium Mtwo instruments, showing the last file a taper of 0.04mm and a diameter close to 40 and 45 k-file. This concept is in accordance with previous studies (Benatti et al. 1985; Jara et al. 2018; Brandão et al. 2019), which demonstrated that this type of apical enlargement does not have interference in the periapical repair. Furthermore, according to previous study, this type of apical enlargement provides better adaptation in the interface between filling material and apical foramen (Silva et al. 2016).

Data from Table 1 show that there was statistically significant difference between groups after root canal preparation, when the apical foramen morphology was evaluated ($p < 0.05$). Samples of Group 1 (1mm from the apical foramen) showed higher mean apical foramen diameter after instrumentation when compared to its condition before instrumentation. Regarding samples of Group II, (1mm from the apical foramen), there was no statistically significant difference in the mean apical foramen diameter after instrumentation when compared to its condition before instrumentation. These results also were observed in previous study (Silva et al. 2016), where enlargement of the apical foramen could not be observed when root canal preparation was performed 1mm from the apical foramen. These data are confirmed by previous studies (Chugal et al. 2003; Endo et al. 2011), which showed that enlargement of the apical foramen improved the cleaning and filling ability during root canal therapy. Furthermore, previous studies have demonstrated that enlargement of the apical foramen in the teeth of dogs was essential to reduce and eliminate infection on the apical foramen area (Souza-Filho et al. 1987; Borlina et al. 2010).

Apical transportation favors microorganisms and tissue remnants on dentine walls, compromising disinfection as well as the sealing of the root canal system, interfering with the repair outcome and inducing postoperative pain (Wu et al. 2000). Thus, it is essential that root canal instrumentation do not provide apical transportation. According to apical transportation results in the present study, there was statistically significant difference between groups after root canal preparation ($p < 0.05$), with higher apical transportation percentage in Group 1. According to the present study, 6 of 10 samples (60%) of Group 1 where apical enlargement was performed showed apical transportation. These results are in accordance with previous study (Silva et al. 2016), where apical transportation could be detected in 66.7% of cases in which root canal preparation was performed 1mm from the apical foramen. However, apical transportation had no interference on the root canal filling. Therefore, the consequences of apical transportation may not be significant during endodontic treatment.

The results of present study showed that adequate apical sealing could be observed in 100% of samples of Group 1, where the apical foramen was enlarged. These results are in accordance with previous study, which reported that enlargement of the apical foramen provides more homogeneous apical sealing (De Carvalho Maciel and Zaccaro Scelza 2006), filling of lateral canals (Venturi 2008) and deep penetration in dentinal tubules (Perassi et al. 2004). The same apical sealing results were found by Silva et al. 2016, who used K3 system for root canal preparation and AH Plus as root canal sealer and observed, through SEM images, better filling quality in groups where apical enlargement was performed. Other authors also reported that apical enlargement can prevent root canal recontamination due to fluid percolation from periapical tissues (Pomel et al. 2003). On the other hand, some precautions must be taken during root canal filling when foraminal enlargement is performed. For example, the operator cannot insert large amount of endodontic sealer into the root canal or apply high pressure during vertical condensation. This can cause an excessive leakage of endodontic sealer in periapical tissues and cause postoperative pain or delayed repair (Schaeffer et al. 2005).

According to data obtained in this study, enlargement of the apical foramen seems to be a predictable procedure that requires ability from operator during the apical preparation stage. The present study suggests root canal preparation 1mm from the apical foramen, from the moment in which this procedure provides enlargement of the apical foramen, improving the apical sealing and consequently providing better conditions to perform adequate and tridimensional root canal filling. The present study has some limitations such as the sample size, the measurement accuracy of the evaluation method, the variability of instrumentation techniques, and lack of evaluation of foraminal enlargement biological variables, among others. Future studies, using microtomography and *in vivo* evaluations should be carried out in order to evaluate these variables and compensate the limitations of the present study.

5. Conclusions

Under the limitation of this study, it could be concluded that enlargement of the apical foramen induces high apical transportation percentage, but this event does not have interference in the apical sealing. In addition, the apical sealing was more effective in cases prepared with enlargement of the apical foramen. Further controlled clinical trials should be developed in the future in order to evaluate the effectiveness of root canal preparation with enlargement of the apical foramen to provide better success predictability of the root canal therapy.

Authors' Contributions: SOUZA, M.A. and SOARES, A.J.: conception and design, data acquisition, data analysis and interpretation, drafting of the manuscript, final approval; DE CARLI, J.P., RODRIGUES, F.T., PIUCO, L. and BISCHOFF, K.F.: data acquisition, data analysis and interpretation, drafting of the manuscript, final approval; BERVIAN, J. and ZANDONÁ, J.: data analysis and interpretation, drafting of the manuscript, final approval; WINOCUR, E.M.D.: drafting of the manuscript, final approval.

Conflicts of Interest: The authors declare no conflicts of interest.

Ethics Approval: Approved by Science and Ethics Commission of State University of Campinas. CEP FOP/UNICAMP: 089/2011.

Acknowledgments: Not applicable.

References

- ALBUQUERQUE, P.P., et al. Influence of foraminal enlargement on the apical extrusion of filling material: Volumetric analysis using micro-computed tomography. *Australian Endodontic Journal*. 2020, **46**(2), 210-216. <https://doi.org/10.1111/aej.12394>
- BENATTI, O., et al. A histological study of the effect of diameter enlargement of the apical portion of the root canal. *Journal of Endodontics*. 1985, **11**(10), 428-434. [https://doi.org/10.1016/S0099-2399\(85\)80080-7](https://doi.org/10.1016/S0099-2399(85)80080-7)
- BORLINA, S.C., et al. Influence of apical foramen widening and sealer on the healing of chronic periapical lesions induced in dogs' teeth. *Oral Surgery, Oral Medicine, Oral Pathology, Oral Radiology, and Endodontics*. 2010, **109**(6), 932-940. <https://doi.org/10.1016/j.tripleo.2010.01.028>
- BRANDÃO, P.M., et al. Influence of foraminal enlargement on the healing of periapical lesions in rat molars. *Clinical Oral Investigations*. 2019, **23**(4), 1985-1991. <https://doi.org/10.1007/s00784-018-2628-2>
- BUCHANAN, L.S. The standardized-taper root canal preparation – Part 1. Concepts for variably tapered shaping instruments. *International Endodontic Journal*. 2001, **33**(6), 516-529. <https://doi.org/10.1046/j.1365-2591.2000.00384.x>
- CARD, S.J., et al. The effectiveness of increased apical enlargement in reducing intracanal bacteria. *Journal of Endodontics*, 2002, **28**(11), 779–783. <https://doi.org/10.1097/00004770-200211000-00008>
- CHUGAL, N.M., CLIVE, J.M. and SPANGBERG, L.S.W. Endodontic infection: some biologic and treatment factors associated with outcome. *Oral Surgery, Oral Medicine, Oral Pathology, Oral Radiology, and Endodontics*. 2003, **96**(1), 81-90. [https://doi.org/10.1016/S1079-2104\(02\)91703-8](https://doi.org/10.1016/S1079-2104(02)91703-8)
- ENDO, M.S., SOARES, A.J. and SOUZA-FILHO, F.J. Análise morfológica do forame apical após o preparo endodôntico com patência e ampliação foraminal. *Revista da Associação Paulista de Cirurgiões Dentistas*. 2011, **65**(2), 145-151. ISSN: 0004-5276.
- HOLLAND, R., et al. Influence of apical patency and filling material on healing process of dogs' teeth with vital pulp after root canal therapy. *Brazilian Dental Journal*. 2005, **16**(1), 9-16. <http://dx.doi.org/10.1590/S0103-64402005000100002>
- JARA, C.M., et al. Influence of apical enlargement on the repair of apical periodontitis in rats. *International Endodontic Journal*. 2018, **51**(11), 1261-1270. <https://doi.org/10.1111/iej.12949>
- MOHAMMADI, Z., et al. Establishing Apical Patency: To be or not to be? *Journal of Contemporary Dental Practice*. 2017, **18**(4), 326-329. <https://doi.org/10.5005/jp-journals-10024-2040>
- MOUNCE, R. What is apical patency and does it matter? *Compendium of Continuing Education in Dentistry (Jamesburg, N.J. : 1995)*. 2005, **26**(1), 62-66.

- NEGISHI, J., KAWANAMI, M. and OGAMI, E. Risk analysis of failure of root canal treatment for teeth with inaccessible apical constriction. *Journal of Dentistry*. 2005, **33**(5), 399-404. <https://doi.org/10.1016/j.jdent.2004.11.003>
- PERASSI, F.T., et al. Secretion of tumor necrosis factor-alpha by mouse peritoneal macrophages in the presence of dental sealers, Sealapex and Endomethasone. *Journal of Endodontics*. 2004, **30**(7), 534-537. <https://doi.org/10.1097/00004770-200407000-00017>
- POMEL, L., et al. Apical leakage of four endodontic sealers. *Journal of Endodontics*. 2003, **29**(3), 208-210. <https://doi.org/10.1097/00004770-200303000-00011>
- RICUCCI, D. Apical limit f root canal instrumentation and obturation, part 1. Literature review. *International Endodontic Journal*. 1998, **31**(6), 344-393. <https://doi.org/10.1046/j.1365-2591.1998.00184.x>
- RICUCCI, D. and LANGELAND, K. Apical limit f root canal instrumentation and obturation, part 2. A histological study. *International Endodontic Journal*. 1998, **31**(6), 394-409. <https://doi.org/10.1046/j.1365-2591.1998.00183.x>
- ROLLISON, S., BARNETT, F. and STEVENS, R.H. Efficacy of bacterial removal from instrumented root canals in vitro related to instrumentation technique and size. *Oral Surgery, Oral Medicine, Oral Pathology, Oral Radiology, and Endodontics*. 2002, **94**(3), 366-371. <https://doi.org/10.1067/moe.2002.126164>
- DE CARVALHO MACIEL, A.C. and ZACCARO SCELZA, M.F. Efficacy of automated versus hand instrumentation during root canal retreatment: an ex vivo study. *International Endodontic Journal*. 2006, **39**(10), 779-784. <https://doi.org/10.1111/j.1365-2591.2006.01148.x>
- SCHAEFFER, M.A., WHITE, R.R. and WALTON, R.E. Determining the optimal obturation length: a meta-analysis of literature. *Journal of Endodontics*. 2005, **31**(4), 271-274. <https://doi.org/10.1097/01.don.0000140585.52178.78>
- SCHILDER, H. Filling root canals in three dimensions. *Journal of Endodontics*. 2006, **32**(4), 281-290. <https://doi.org/10.1016/j.joen.2006.02.007>
- SILVA, E.A.B., et al. Evaluation of effect of foraminal enlargement of necrotic teeth on postoperative symptoms: A systematic review and meta-analysis. *Journal of Endodontics*. 2017, **43**(12), 1969-1977. <https://doi.org/10.1016/j.joen.2017.07.014>
- SILVA, J.M., et al. Influence of working length and foraminal enlargement on foramen morphology and sealing ability. *Indian Journal of Dental Research*. 2016, **27**(1), 66-72. <https://doi.org/10.4103/0970-9290.179834>
- SILVA-SANTOS, A.M., et al. Foraminal deformation after foraminal enlargement with rotary and reciprocating kinematics: A scanning electronic microscopy study. *Journal of Endodontics*. 2018, **44**(1), 145-148. <https://doi.org/10.1016/j.joen.2017.08.013>
- SOUZA-NETO, M.D., et al. Root canal preparation using micro-computed tomography analysis: a literature review. *Brazilian Oral Research*. 2018, **32**, 20-43. <https://doi.org/10.1590/1807-3107bor-2018.vol32.0066>
- SOUZA, R.A. Clinical and radiographic evaluation of the relation between the apical limit of root canal filling and the success in Endodontics. Part 1. *Brazilian Endodontic Journal*. 1998, **3**, 43-48.
- SOUZA-FILHO, F.J., BENATTI, O. and ALMEIDA, O.P. Influence of the enlargement of the apical foramen in periapical repair of contaminated teeth of dog. *Oral Surgery, Oral Medicine, Oral Pathology, Oral Radiology, and Endodontics*. 1987, **64**(4), 480-484. [https://doi.org/10.1016/0030-4220\(87\)90157-5](https://doi.org/10.1016/0030-4220(87)90157-5)
- TAN, B.T. and MESSER, H.H. The quality of apical canal preparation using hand rotary instruments with specific criteria for enlargement based on initial apical file size. *Journal of Endodontics*. 2002, **28**(9), 658-664. <https://doi.org/10.1097/00004770-200209000-00008>
- USMAN, N., BAUMGARTNER, J.C. and MARSHALL, J.G. Influence of instrument size on root canal debridement. *Journal of Endodontics*. 2004, **30**(2), 110-112. <https://doi.org/10.1097/00004770-200402000-00012>
- VENTURI, M. An ex-vivo evaluation of a gutta-percha filling technique when used with two endodontic sealers: Analysis of the filling of main and lateral canals. *Journal of Endodontics*. 2008, **34**(9), 1105-1110. <https://doi.org/10.1016/j.joen.2008.06.017>
- WU, M.K., FAN, B. and WESSELINK, P.R. Leakage along apical root fillings in curved canals. Part I. Effects of apical transportation on seal of root fillings. *Journal Endodontics*. 2000, **26**(4), 210-216. <https://doi.org/10.1097/00004770-200004000-00003> ISSN 0099-2399
- WU, M.K., et al. Does the first file to bind correspond to the diameter of the canal in the apical region? *International Endodontic Journal*. 2002, **35**(3), 264-267. <https://doi.org/10.1046/j.1365-2591.2002.00474.x>
- WU, M.K., et al. Prevalence and extent of long oval canals in the apical third. *Oral Surgery, Oral Medicine, Oral Pathology, Oral Radiology, and Endodontics*. 2000, **89**(6), 739-743. <https://doi.org/10.1067/moe.2000.106344>

Received: 16 July 2020 | Accepted: 30 August 2020 | Published: 12 January 2021



This is an Open Access article distributed under the terms of the Creative Commons Attribution License, which permits unrestricted use, distribution, and reproduction in any medium, provided the original work is properly cited.