

## Case Report

# Ewing's sarcoma of ilium, a diagnostic dilemma - case report with review of literature

Usama Saleh Alshaya, Munzir Abbashir, Mubashir Maqbool Wani\*

*Department of Orthopedics, Division of Surgical Specialities, King Fahad Medical City, Riyadh, Saudi Arabia*

**Abstract.** Ewing's sarcoma is a highly malignant tumor of bone and is more common in children in the age group of 10 to 20 years. Sometimes the classic clinical and radiological presentation of Ewing's sarcoma may not be the norm and patient may have an atypical presentation leading to diagnostic confusion. This is especially true for Ewing's sarcoma involving iliac bone. We present such a case of Ewing's sarcoma involving the right ilium in a patient presenting as right lower quadrant pain and non-specific radiological changes. To the best of our knowledge, this scenario has not been reported in literature. We recommend early magnetic resonance imaging and computed tomography to diagnose the disease early when there is slightest suspicion of the disease.

**Keywords:** Ewing's sarcoma, ilium, diagnosis

### Introduction

Ewing's sarcoma is known for being highly malignant. Named after James Ewing [1], it is the second most common primary malignant tumor of bone in children with a characteristic predilection for an age group between 10-20 years [2]. Although the exact etiology is not known, it has been found that in 85% of ES patients, the pathognomonic t (11:22) chromosomal translocation is found. The location of ES is most often in the pelvis and lower extremity [3]. In 12.5% cases of ES, iliac bone is the site of origin. Clinically, the most common presenting symptom is pain (90%), followed by swelling (70%) [4]. Radiologically, it is described as a central, diaphyseal, lytic tumor, which is often permeative and has a lamellated or 'onion skin' periosteal reaction affecting a long bone, and associated with soft tissue mass. The bone lesions are usually lytic, but may be sclerotic or mixed. Most of the lesions are diaphyseal or metadiaphyseal.

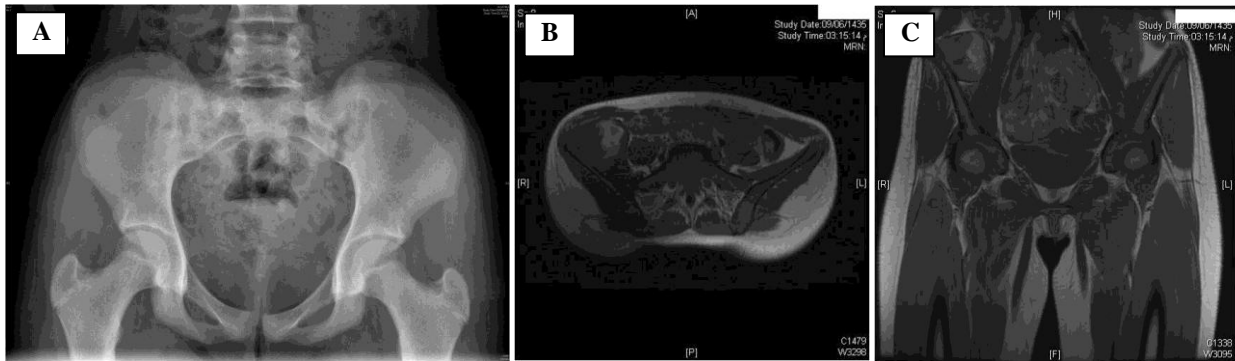
Diagnosing Ewing's sarcoma of ilium remains a challenge in its early stages. This is partly because of the myriad of symptoms it presents with and the very non-recognizable subtle changes radiographically when in its initial stage. We describe one such case who had Ewing's sarcoma of right ilium and presented with pain in the right lower quadrant of the abdomen. We also reviewed the literature regarding the diagnostic dilemma of Ewing's sarcoma of ilium and the different clinical presentations it can have. None of the patients with Ewing's sarcoma to the best of our knowledge has ever presented with right lower quadrant pain

### Case Report

A girl 13 years of age, Saudi in origin presented to us with a history of pain right lower quadrant of 6 months duration. She had been visiting many clinics for her pain with no relief to her symptoms. In the initial stages of her disease, she had undergone multiple ultrasound examinations with no clue of the diagnosis. The patient already had undergone appendectomy 2 years back, so appendicitis was not kept as a differential diagnosis. In one of the latest ultrasound examination of the abdomen, the sonologist picked up a mass in her right iliac fossa arising from pelvis suspecting an abscess or a tumor. Patient was referred to our clinic for further evaluation and treatment. On our examination, there was no tenderness in the right iliac fossa nor any palpable swelling could be palpated. ESR, CBC, CRP were normal. X ray pelvis AP was done which did not show any significant bony changes (Fig. 1 A). MRI of the pelvis was done which showed a soft tissue mass arising along the right iliac bone most probably soft tissue sarcoma with focal bony involvement (Figs. 1 B and 1 C). This was followed by technetium -99m MDP scintigraphy. This was negative for multifocal skeletal metastatic disease and negative for local invasion of the osseous structures. CT scan of thorax and abdomen was done which ruled out any metastasis.

Under sterile conditions, ultra sound -guided fine needle aspiration of the right iliac fossa mass was done using 22 G needle. About 15 ml hemorrhagic fluid was aspirated. This showed presence of malignant cells. It was followed by an open biopsy of the mass which was

\* Corresponding author: Mubashir Maqbool Wani, MBBS  
[mmwani@kfmc.med.sa](mailto:mmwani@kfmc.med.sa).



**Figure 1** (A) X-ray anteroposterior view of the pelvis showing hard to pick changes in the right ilium. (B and C) MRI images of the patient before initiation of neo-adjuvant chemotherapy, showing mass arising along the right iliac bone most probably soft tissue sarcoma with focal bony involvement.

reported by the histopathologists as Ewing's sarcoma. Patient was put on neo adjuvant chemotherapy which included Vincristine, cyclophosphamide, doxorubicin and etoposide, ifosfamide (VCD/IE 3 weekly). Following neoadjuvant chemotherapy, the mass had shrunk in size and internal hemipelvectomy was undertaken excising the tumor mass along with the involved bone sparing the sacroiliac joint and hip joint (Fig. 2 A). The margins were negative for any residual tumor. The patient was again given chemotherapy after surgery and radiotherapy was added to minimize the chances of recurrence. Presently patient is doing fine, is ambulatory and pain free. The last MRI done for the patient does not show any evidence of recurrence (Figs. 2 B and 2 C). The patient will follow us regularly. Written informed consent was obtained from the patient for publication of this case report and accompanying images.

### Discussion

Early diagnosis of Ewing's sarcoma of ilium remains challenge partly because of the subtle difficult to pick changes in the radiographs and the clinical symptoms patients have. After reviewing the literature by searching pubmed with terms like 'Ewing's sarcoma of ilium', 'Diagnosis of Ewing's sarcoma of ilium', 'clinical presentations of Ewing's sarcoma', we could find few case reports regarding the atypical presentation of Ewing's sarcoma. The delay in diagnosis can partly be due to the the radiologic appearance of inflammatory and tumorous lesions in the iliac bone which is characterized by destructive alterations and consolidations simultaneously. This pattern is nonspecific. The value of plain films of this area is compromised by the anatomy of the iliac bone and by overlying structures [5]. There have been instances where authors have diagnosed Ewing's sarcoma of the ilium as sacroiliitis [6, 7, 8] and in some cases even septic arthritis [9] possibly because of transarticular spread in these patients. The authors of these cases mainly relied on clinical presentation and plain radiography initially which lead to the diagnostic confusion. There have also been cases reported of Ewing's sarcoma of ilium mimicking juvenile rheumatoid arthritis [10] and pain in the hip [11]. In our case the patient's presentation as right lower

quadrant pain again lead to diagnostic confusion and delayed treatment till a definite diagnosis could be reached to.

Patients of Ewing's sarcoma need a multidisciplinary approach to treatment which includes involvement of oncologists, radiation oncologists, surgeons and radiologists. Haematogenous spread to lungs and bone is very common in Ewing's sarcoma, so neo adjuvant chemotherapy has an important role in treatment of Ewing's sarcoma. While surgery is effective and appropriate for patients who can undergo complete resection with acceptable morbidity, children who have unresectable tumors or who would suffer loss of function are treated with radiation therapy alone. We were fortunate enough to have clear margins at the time of surgery in our patient without causing any functional disability to the patient. Prognosis depends on extent of the disease, size and location of the tumor, presence or absence of the tumor metastasis, tumor response to therapy, age, and disease relapse. Most centers today report long-term survival of 60% to 70%. The worst prognostic factor is the presence of distant metastasis. Even with aggressive treatment, patients with metastasis have only a chance of 20% long-term survival. Histological grades are of no prognostic significance.

### Conclusion

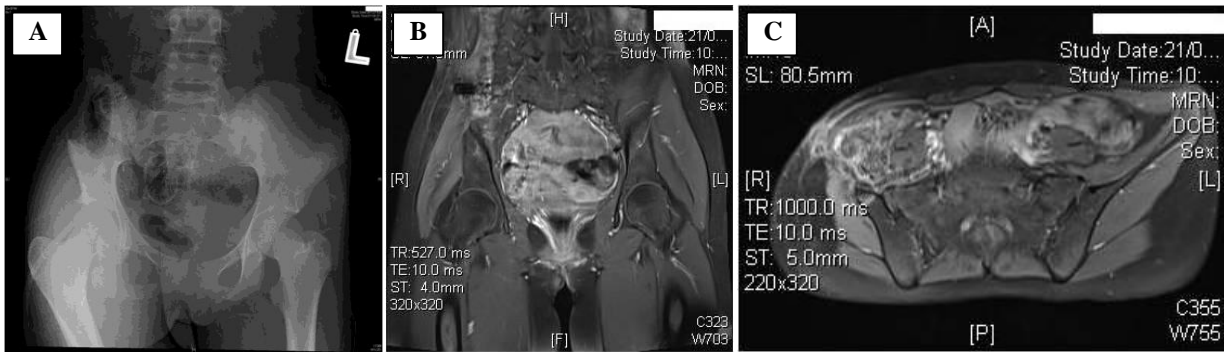
We believe that Ewing's sarcoma should be kept as one of the rare differential diagnosis for lower quadrant pain. Ultrasonography should not be relied on much and X-rays may not add more to the knowledge. Lower threshold should be kept for investigations like CT and MRI to pick the disease early and start the appropriate treatment.

### Conflict of interest

The authors declare no conflicts of interest.

### References

1. Huvos AG. James Ewing: cancer man. *Ann Diagn Pathol* 2:146-148, 1998.
2. Grier HE: The Ewing family of tumors: Ewing's sarcoma and primitive neuroectodermal tumors. *Pediatr Clin North Am* 44:991-1004, 1997.



**Figure 2** (A) X-ray image of the patient showing right internal hemipelvectomy. (B and C) MRI images of the patient showing no evidence of tumor.

3. Kissane JM, Askin FB, Foulkes M et al.: Ewing's sarcoma of bone clinic pathologic aspects of 303 cases from the Intergroup Ewing's sarcoma study. *Hum Pathol* 14:773-779, 1983.

4. Vlasak R, Sim FH: Ewing's sarcoma. *Orthop Clin North Am* 27:591-603, 1996.

5. Appell RG, Oppermann HC. Differential diagnosis of tumorous changes in the iliac bone region in children. Case reports and review of the literature. *Radiologie* 24:60-67, 1984.

6. Adelman HM, Wallach PM, Flannery MT: Ewing's sarcoma of the ilium presenting as unilateral sacroiliitis. *J Rheumatol* 18:1109-1111, 1991.

7. Pouchot J, Barge J, Marchand A, Carbonnier J, Vinceneux P: Ewing's sarcoma of the ilium mimicking an

infectious sacroiliitis. *J Rheumatol* 19:1318-1320, 1992.

8. Al-Adsani A, Niazy MN, Mohd M. Ewing's sarcoma of the ilium mimicking sacroiliitis. *Rheumatology (Oxford)*. 38:792-793, 1999.

9. Halwai MA<sup>1</sup>, Mir BA, Wani MM, Bashir A, Hussain A. Ewing's sarcoma of the ilium mimicking inflammatory arthritis of the hip: a case report. *Cases J* 2:6487, 2009.

10. Wang XN, Su GX, Wu FQ. Report of a child with Ewing's sarcoma who was misdiagnosed as juvenile idiopathic arthritis. *Zhonghua Er Ke Za Zhi* 50:866-867, 2012.

11. De Maddi F, Rigante D, de Ritis R, et al. Misdiagnosis of Ewing's sarcoma of the ilium at the pelvis X-ray. *Rheumatol Int* 32:1109-1110, 2012.