

CASR REPORT

Odontogenic Pain as the Principal Presentation of Vertebral Artery Pseudoaneurysm; a Case Report

Marco Zenteno¹, Hernando Raphael Alvis-Miranda², Angel Lee¹, Luis Rafael Moscote-Salazar^{2*}

1. Department of Neurosurgery, National Institute of Neurology and Neurosurgery, D.F. Mexico, Mexico.

2. Department of Neurosurgery, University of Cartagena, Cartagena de Indias, Colombia.

*Corresponding Author R: Luis Rafael Moscote-Salazar. Department of Neurosurgery, University of Cartagena, Cartagena de Indias, Colombia.

Tel: +573012835380; E-mail: mineurocirujano@aol.com

Received: October 2014; Accepted: January 2015

Abstract

Dissection of the vertebral artery is an important but rare cause of cerebrovascular accidents. Here we report a 48-year-old man with toothache since 4 days before who presented to the emergency department with neck pain and final diagnosis of dissecting right vertebral artery pseudoaneurysm. To our knowledge, this maybe the first report of odontogenic pain as the first manifestation of vertebral artery pseudoaneurysm in the literatures.

Key words: vertebral artery dissection, toothache, stroke.

Cite this article as: Zenteno M, Alvis-Miranda HR, Lee A, Rafael L. Odontogenic pain as the principal presentation of vertebral artery pseudoaneurysm; a case report. *Emergency*. 2015; 3(3):122-24

Introduction:

Dissection of the vertebral artery is an important but a rare cause of cerebrovascular accidents (1). The annual incidence rate of vertebral artery dissection is estimated to be about 1-1.5 per 100,000 population. However it is responsible for 20% of cerebrovascular accidents in young adults and represents about 0.4 to 2.5% of all cerebrovascular events (2, 3). In recent years, this clinical entity has received more attention from neurologists and neurosurgeons, which has allowed its early and further diagnosis. Learning various possible manifestations, can help lessen missed diagnosis. Here we report a case of dissecting vertebral artery pseudoaneurysm, presenting itself with odontogenic pain principally.

Case report:

A 48-year-old man suffering from toothache and neck pain was referred to the emergency department. Toothache was initiated since four days ago. He was visited by dentists several times and taken different analgesics, without any improvement. The dental pain had exacerbated and neck pain was added, too. On arrival, he had normal vital signs and was conscious. He had stiff neck, but no focal neurologic deficits. Other physical exams also did not reveal any positive finding. Brain computed tomography (CT) scan revealed subarachnoid hemorrhage. Three-dimensional CT angiography showed the presence of a dissecting pseudoaneurysm of the right vertebral artery (Figures 1 and 2). We decided to eliminate it through endovascular ap-

proach, before a potentially lethal rupture. Therefore, the patient underwent surgery with stent insertion. His post-operative evolution was completely satisfactory and he was discharged after 5 days.

Discussion:

Vertebral artery dissection is a recognized cause of ischemic stroke in young adults. Atherosclerosis, connective tissue diseases, and cervical trauma are risk factors associated with development of this pathology (1, 3, 4). The pathophysiology of dissection and pseudoaneurysm basically consist of an initial intimal tear, followed by entry of blood between the intima and the adventitia, which leads to growing and ballooning of the pseudoaneurysm (5). Vertebral and basilar arteries play the main role in the posterior circulation of brain. Therefore, the most prevalent clinical symptoms of vertebral artery dissection consist of neck pain and posterior headache that may follow cerebrovascular accidents related to posterior circulation entity. If extra-cranial dissection extends to the intracranial fossa, and also in cases of primary intracranial dissection, subarachnoid hemorrhage may occur (6). Some authors have declared that this should be considered as one of the differential diagnoses in patients referred with any cranio-cervical pain. But vertebral dissection presenting with facial pain has rarely been described in the literature (3, 7). Modalities such as brain magnetic resonance imaging (MRI), computed tomography, and conventional angiography are frequently used for diagnosis. In spite of all that, conventional digital subtraction angiography has



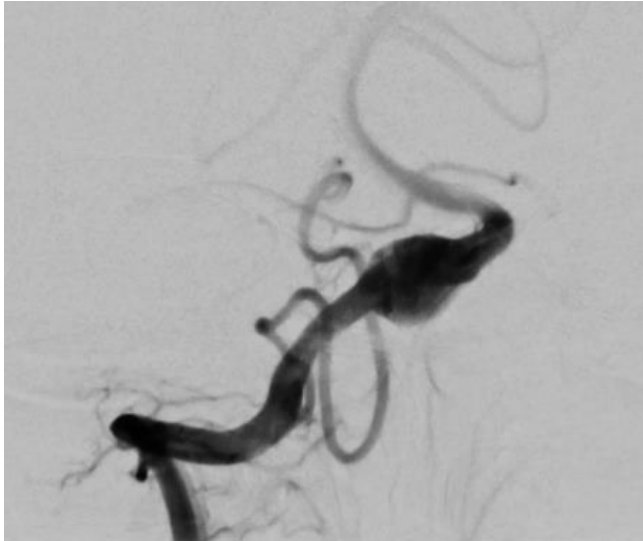

Figure 1: Conventional angiography confirmed the pseudoaneurysm of the right vertebral artery.

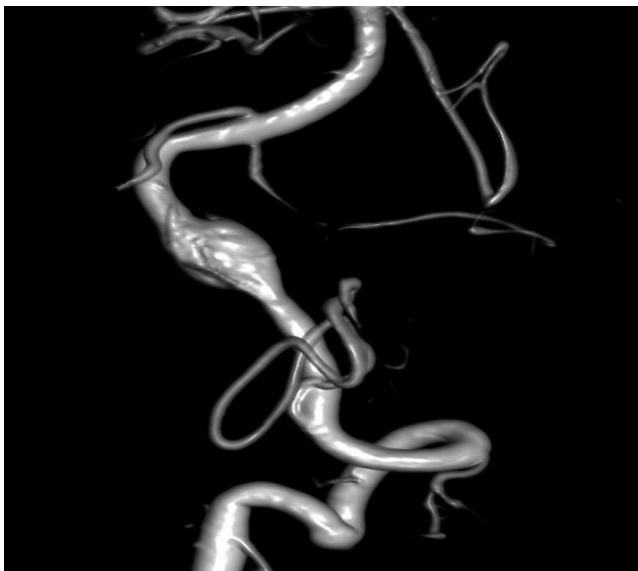


Figure 1: Three-dimensional computed angiography demonstrated the pseudoaneurysm of the right vertebral artery.

remained as the gold standard in terms of diagnostic modality to make the proper diagnosis and have a dynamic evaluation of the blood flow through the visualized defect (8). A three-dimensional reconstruction shows important morphologic information of the lesion (9). Dynamic computed tomography angiography (CTA) can also provide critical hemodynamic information. Standard CT and MRI with or without contrast enable evaluation of surrounding neurovascular and soft tissue structures and provide a better understanding of the surrounding anatomy (10, 11).

Surgery could be accomplished by either endovascular technique or surgical trapping with clips above and below. Some advantages of the endovascular management

are as follows: it is minimally invasive, needs less time for vascular occlusion during repair, avoids devitalized tissue, and can be performed in the presence of previously instituted anti-platelet or anti-coagulant therapies (12-15). Favorable outcome is assumed for younger patients, those who are diagnosed before appearing the stroke, and even in most ischemic strokes. On the other hand, late or missed diagnosis can lead to poor outcome (15-17).

Conclusion:

Dissection of the vertebral artery is a rare but important cause of cerebrovascular accidents in adults. Becoming familiar with atypical manifestations, as in our case, can lead to early diagnosis and therefore may reduce morbidity and mortality.

Conflict of interest:

None.

Funding support:

None.

Authors' contributions:

All authors passed four criteria for authorship contribution based on recommendations of the International Committee of Medical Journal Editors.

References:

1. Mokri B, Houser OW, Sandok BA, Piepgras DG. Spontaneous dissections of the vertebral arteries. *Neurology*. 1988;38(6):880-.
2. Schievink WI, Mokri B, O'Fallon WM. Recurrent spontaneous cervical-artery dissection. *New England Journal of Medicine*. 1994;330(6):393-7.
3. Gottesman RF, Sharma P, Robinson KA, et al. Clinical characteristics of symptomatic vertebral artery dissection. A systematic review. *The neurologist*. 2012;18(5):245.
4. Kasmaei HD, Baratloo A, Nasiri Z, Soleymani M, Yazdani MO. Recombinant Tissue Plasminogen Activator Administration in Patients With Cerebrovascular Accident; A Case Series. *Archives of Neuroscience*. 2015;2(2).
5. Nader R, Gragnaniello C. *Neurosurgery Tricks of the Trade: Cranial*; Thieme; 2013.
6. Baumgartner R, Bogousslavsky J, Caso V, Paciaroni M. Clinical manifestations of vertebral artery dissection. *Frontiers of neurology and neuroscience*. 2005;77.
7. Krespi Y, Gurol ME, Coban O, Tuncay R, Bahar S. Vertebral artery dissection presenting with isolated neck pain. *Journal of Neuroimaging*. 2002;12(2):179-82.
8. Chappell ET, Moure FC, Good MC. Comparison of computed tomographic angiography with digital subtraction angiography in the diagnosis of cerebral aneurysms: a meta-analysis. *Neurosurgery*. 2003;52(3):624-31.
9. Tanoue S, Kiyosue H, Kenai H, Nakamura T, Yamashita M, Mori H. Three-dimensional reconstructed images after rotational angiography in the evaluation of intracranial aneurysms: surgical correlation. *Neurosurgery*. 2000;47(4):866-71.
10. Nader R, Gragnaniello C, Berta SC, Sabbagh AJ, Levy ML.



TOPIC BOOK REVIEW.

11. Malhotra AK, Camacho M, Ivatury RR, et al. Computed tomographic angiography for the diagnosis of blunt carotid/vertebral artery injury: a note of caution. *Annals of surgery*. 2007;246(4):632-43.
12. Brown M, Rogers J, Bland J. Endovascular versus surgical treatment in patients with carotid stenosis in the Carotid and Vertebral Artery Transluminal Angioplasty Study (CAVATAS): a randomised trial. *The Lancet*. 2001;357(9270):1729-37.
13. Kitanaka C, Tanaki J-I, Kuwahara M, Teraoka A, Sasaki T, Takakura K. Nonsurgical treatment of unruptured intracranial vertebral artery dissection with serial follow-up angiography. *Journal of neurosurgery*. 1994;80(4):667-74.
14. Halbach VV, Higashida RT, Dowd CF, et al. Endovascular treatment of vertebral artery dissections and pseudoaneurysms. *Journal of neurosurgery*. 1993;79(2):183-91.
15. Khurana DS, Bonnemann CG, Dooling EC, Ouellette EM, Buonanno F. Vertebral artery dissection: issues in diagnosis and management. *Pediatric neurology*. 1996;14(3):255-8.
16. De Bray J, Penisson-Besnier I, Dubas F, Emile J. Extracranial and intracranial vertebrobasilar dissections: diagnosis and prognosis. *Journal of Neurology, Neurosurgery & Psychiatry*. 1997;63(1):46-51.
17. Shah Q, Messé SR. Cervicocranial arterial dissection. Current treatment options in neurology. 2007;9(1):55-62.

