

**ŻYBOWSKA-MĘCZYŃSKA, Monika, PAWŁOWSKI, Bartosz, SIENKIEWICZ, Michał, ZATŁOKA-MAZUR, Dorota, KLIMAS, Filip, RUSIŃSKI, Kacper, POCZEK, Adriana, PUDEŁKO, Iwona, ZIĘBA, Zuzanna and SZCZEPANIK, Natalia. Bone tumors in children and adolescents in pediatric practice. Quality in Sport. 2025;38:58257. eISSN 2450-3118.**

<https://doi.org/10.12775/QS.2025.38.58257>

<https://apcz.umk.pl/QS/article/view/58257>

The journal has been 20 points in the Ministry of Higher Education and Science of Poland parametric evaluation. Annex to the announcement of the Minister of Higher Education and Science of 05.01.2024. No. 32553.

Has a Journal's Unique Identifier: 201398. Scientific disciplines assigned: Economics and finance (Field of social sciences); Management and Quality Sciences (Field of social sciences).

Punkty Ministerialne z 2019 - aktualny rok 20 punktów. Załącznik do komunikatu Ministra Szkolnictwa Wyższego i Nauki z dnia 05.01.2024 r. Lp. 32553. Posiada Unikatowy Identyfikator Czasopisma: 201398.

Przypisane dyscypliny naukowe: Ekonomia i finanse (Dziedzina nauk społecznych); Nauki o zarządzaniu i jakości (Dziedzina nauk społecznych).

© The Authors 2025;

This article is published with open access at Licensee Open Journal Systems of Nicolaus Copernicus University in Torun, Poland

Open Access. This article is distributed under the terms of the Creative Commons Attribution Noncommercial License which permits any noncommercial use, distribution, and reproduction in any medium, provided the original author (s) and source are credited. This is an open access article licensed under the terms of the Creative Commons Attribution Non commercial license Share alike. (<http://creativecommons.org/licenses/by-nc-sa/4.0/>) which permits unrestricted, non commercial use, distribution and reproduction in any medium, provided the work is properly cited.

The authors declare that there is no conflict of interests regarding the publication of this paper.

Received: 27.01.2025. Revised: 17.02.2025. Accepted: 18.02.2025 Published: 18.02.2025.

## **Bone tumors in children and adolescents in pediatric practice**

1. Monika Żybowska-Męczyńska, St. John Paul II Mazovian Provincial Hospital in Siedlce, Poland, Księcia Józefa Poniatowskiego 26, 08-110 Siedlce, Poland, Email: [zybowska.m@gmail.com](mailto:zybowska.m@gmail.com), ORCID: <https://orcid.org/0000-0002-3885-5907>
2. Bartosz Pawłowski, University Clinical Hospital No. 4 in Lublin Doktora Kazimierza Jaczewskiego Street 8, 20- 954 Lublin, Email: [bartek4245@gmail.com](mailto:bartek4245@gmail.com), ORCID: <https://orcid.org/0009-0009-3515-1777>
3. Michał Sienkiewicz Regional Specialist Hospital in Biała Podlaska Terebelska Street 57/65, 21-500 Biała Podlaska Email: [michal.sienkiewicz09@gmail.com](mailto:michal.sienkiewicz09@gmail.com) ORCID: <https://orcid.org/0009-0001-0427-9198>
4. Dorota Zatłoka-Mazur, Tytus Chałubiński Regional Hospital in Zakopane, Kamieniec 10 street, 34-500 Zakopane, [zdorota811@gmail.com](mailto:zdorota811@gmail.com), ORCID: <https://orcid.org/0009-0003-3663-1891>
5. Filip Klimas, SP ZOZ MSWiA Hospital in Kraków, Kronikarza Galla 25 street, 30-053 Kraków, Email: [e1filipklimas@gmail.com](mailto:e1filipklimas@gmail.com), ORCID: <https://orcid.org/0009-0000-5266-8676>

6. Kacper Rusiński, University Clinical Hospital in Poznan, Przybyszewskiego Street 49, 60-355 Poznań, E-mail [kacper.rusinski1@gmail.com](mailto:kacper.rusinski1@gmail.com), ORCID: <https://orcid.org/0009-0005-4002-9267>
7. Adriana Potoczek, University Clinical Hospital in Katowice, Medyków 14 street, 40-752 Katowice, e-mail: [adriana.potoczek@interia.pl](mailto:adriana.potoczek@interia.pl), ORCID: <https://orcid.org/0009-0002-3981-3490>
8. Iwona Pudelko, University Clinical Hospital in Wrocław, Borowska 213 street, 50-556 Wrocław, e-mail: [i.pudelko.97@gmail.com](mailto:i.pudelko.97@gmail.com), ORCID: <https://orcid.org/0009-0001-6403-4141>
9. Zuzanna Zięba, University Clinical Hospital in Poznan, Przybyszewskiego Street 49, 60-355 Poznań, E-mail: [zuzia1997.z@gmail.com](mailto:zuzia1997.z@gmail.com), ORCID: <https://orcid.org/0009-0002-1576-8058>
10. Natalia Szczepanik, Medical clinic in Piastów Clinic at Konopnicka, ul. Konopnicka 11 Piastów, 05-820 Piastów, e-mail: [szczepaniknatalia3@gmail.com](mailto:szczepaniknatalia3@gmail.com), ORCID: <https://orcid.org/0009-0006-5179-4324>

**Abstract:**

Bone cancers in children are uncommon, making up approximately 5,5 % of all pediatric cancers. Childhood cancers are characterized by rapid development, and any delay in diagnosis can lead to serious consequences and even be life-threatening. The most common malignant tumors in key practice are: osteosarcoma (OS) and Ewing sarcoma (EWS). OS and EWS in children and adolescents require integrated diagnostics and age-appropriate therapy to ensure the best possible treatment outcomes. In recent years, the survival rates of pediatric cancer patients have improved and, consequently, it is necessary to reduce the long-term, late effects of treatment in order to promote the reduction of the deterioration in quality of life caused by treatment and to ensure the best possible return to everyday life.

**Keywords:** bone cancers, children, osteosarcoma, Ewing's sarcoma

**Introduction:**

Neoplastic diseases in the pediatric population are extremely rare. They occur with a frequency of about 1.5-3% of all human neoplasms. However, neoplastic diseases are the first cause of deaths caused by disease before reaching the age of 15 [1,2]. Neoplasms in children are also characterized by rapid development, and any delay in diagnosis can cause serious consequences or even life-threatening. In Poland, the most common are leukemia (approx. 27%), CNS neoplasms (approx. 23%), lymphomas - (15%), and bone tumors constitute approx. 5.5%. The most common malignant tumors in key practice are: osteosarcoma (OS) and Ewing sarcoma (EWS). OS and EWS in the pediatric population require a multidisciplinary diagnostic and therapeutic approach, taking into account the specificity of the patient's age, in order to achieve the best possible treatment effects. Only early diagnosis and appropriate therapy will allow for achieving therapeutic success, which for such a specific patient as children and adolescents is extremely important due to numerous physical and psychological aspects. In this work, we wanted to draw attention to the two most common bone tumors, which are OS and EWS. It happens that patients are not referred to the appropriate centers, and only early detection gives greater chances for cure [3]. In most cases, the etiology is unknown, but reports from the literature and studies show a significant influence of the environment, gene mutations as risk factors. Additionally, initial symptoms can be very non-specific, which can significantly delay diagnosis.

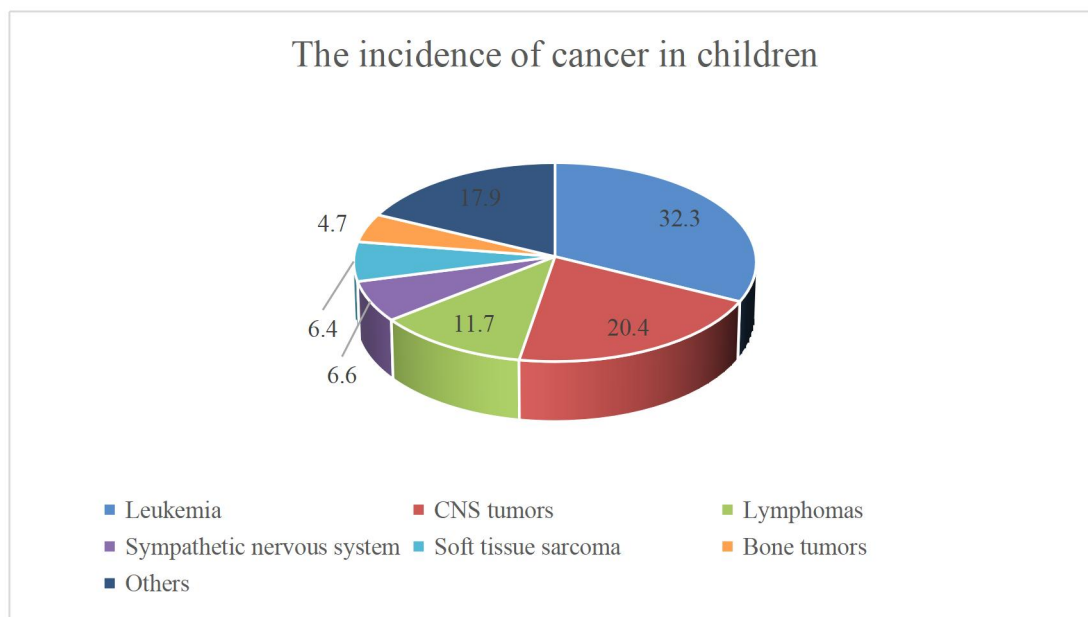


Chart 1. Frequency of occurrence of cancer diseases in children [4]

### **Osteosarcoma (OS)**

It most often occurs in children during puberty. In the male population, this tumor develops more frequently. The most common locations include the metaphysis of long bones, especially the distal part of the femur and the proximal part of the tibia [5]. The clinical picture is most often characterized by the occurrence of pain, which is present in most patients. Patients often wake up during sleep because the pain is so severe. For doctors, any complaint of pain reported by a child or parents should be a worrying symptom, especially pain that occurs at rest. In addition, the presence of a nodular lesion or limb deformity should require further tests to exclude other bone pathologies [6]. Studies have shown that some genetic disorders, such as Li-Fraumeni syndrome, Rothmund-Thomson syndrome, may be associated with a predisposition to OS [7]. The occurrence of OS may be related to exposure to radiation and chemotherapy. [8]. Studies have also been conducted which showed that patients diagnosed with OS had elevated levels of alkaline phosphatase (ALP) compared to the control group [9]. During the diagnostic process, it is necessary to determine the concentration of electrolytes such as: potassium, sodium, chlorides, bicarbonates, calcium, phosphorus and magnesium. Renal function is also checked by performing - Blood urea nitrogen (BUN) and creatinine values and liver functions are assessed - Aspartate aminotransferase (AST), alanine aminotransferase (ALT), bilirubin and albumin [10].

### Ewing's sarcoma (EWS)

Ewing's sarcoma is the second most common bone tumor in children. A characteristic feature of these tumors is non-random chromosomal translocations that lead to the formation of fusion genes that play a key role in the pathogenesis of the tumor. The most common translocation is t(11;22)(q24;q12), which occurs in as many as 85% of tumors [11]. The most frequently reported symptoms include pain and swelling. Unlike osteosarcoma, EWS may be characterized by the occurrence of general symptoms. A worrying symptom should always be pain that is not the result of trauma, lasts longer than 1 month, and persists at night. Such symptoms are an urgent indication for imaging tests [12].

	<b>Osteosarcoma (OS)</b>	<b>EWS</b>
Age of onset	Most often between 10 and 20 years of age	Peak incidence at 15 years of age
Frequency by sex	More common in boys	More common in boys
Location	Metaphyses of long bones	pelvis, axial skeleton and femur; however, it can occur in almost any bone or soft tissue.
Main symptoms	Intense pain (approx. 90%), often waking from sleep, Pain of a sharp or dull nature at the site of the tumor - Redness at the site of the tumor - Limping	- General symptoms (fever) may be more common, - pain, - swelling at the site of the tumor
Treatment	Chemotherapy, surgical treatment	Chemotherapy, surgical treatment, radiotherapy

Table 1. Comparison of osteosarcoma and EWS [2, 13]

### **Symptoms suggestive of a malignant bone tumor**

The most common symptom that may be associated with the development of bone tumors is pain. The duration of the symptoms is variable, even from several days to even weeks. The first symptom may also be the occurrence of a pathological fracture. The location is also key. Symptoms may vary depending on the location. Difficulty breathing, pneumonia may be associated with Ewing's sarcoma, which is located in the chest wall. [14]. Swelling should also be a cause for concern, sometimes there is no pain and only swelling at the site of the tumor. Another disturbing symptom is limited mobility, both active and passive, which may consequently lead to gait disturbances. [15].

The symptoms can develop at different rates, which is why it is essential to detect symptoms at an early stage of development. Diagnosis of a bone tumor is possible after demonstrating a pathological focus on an imaging test. A huge problem is the time from the moment of symptoms to diagnosis, which is often too long [16]. X-rays, MRI scans and bone isotope scans are performed. On the X-rays taken, we analyze: bone shape, tumor location, its boundaries and dimensions, degree and type of bone destruction, condition of the cortical layer and marrow cavity, periosteal reaction and the relationship of the tumor to the surrounding soft tissues. EWS is often characterized by the occurrence of a bone tumor in the soft tissues [17].

### **Physical activity after treatment**

Having an oncological disease and the treatment associated with it lead to a decrease in bone mass. This is mainly caused by endocrine changes in the body. Patients after oncological treatment may experience numerous long-term side effects that significantly affect the physical and mental aspects [18].

In recent years, the survival rates of pediatric cancer patients have improved and, consequently, it is necessary to reduce the long-term, late effects of treatment in order to promote the reduction of the deterioration in quality of life caused by treatment and to ensure the best possible return to everyday life.

Temesgen Lingerih et al. In their study, they showed that the average time from the first symptoms to the oncology center was 5 months. The analysis showed that in their study, 52.6% of patients were boys and 47.4% were girls, which confirms the occurrence of OS and EWS more often in males. Almost half of the children were between 5 and 10 years old. The

study also showed that 41.9% of patients were diagnosed with advanced (Metastatic) disease [19].

Children who have undergone oncological treatment are exposed not only to long-term hospital stays, but also to long-term absence from school, the possibility of participating in various types of sports activities, competitions, and sports tournaments, which significantly limits their contacts with classmates and may negatively affect their social, mental and physical development [20]. Children after cancer treatment are often exposed to social isolation, which makes it harder for them to find their place in team sports, which is why they do not engage in physical activity [21].

The study by Martin Kaj Fridh et al. involved determining the effect of physical activity implemented in-hospital physical activity program during treatment [22]. The study included children aged 6-18 years at diagnosis who were treated with chemo-/radiotherapy. A control group and a research group were designated, the intervention group were 75 children after cancer treatment and the control group were 33 patients who are after 1 year of treatment. There were no statistically significant differences in age, gender, height, weight, BMI or distribution of diagnoses. It was shown that children who already received a physical activity program in the hospital, were supported by peers, achieved higher cardiorespiratory fitness scores compared to children who received usual care 1 year after the end of treatment. Studies have shown that children who engage in physical activity during treatment as a result need less intensive rehabilitation after the end of treatment to achieve a level of physical fitness appropriate for their age. It was shown that specialist actions are still needed to improve cardiorespiratory fitness. The introduction of supervised physical intervention in hospitals and childhood cancer treatment centres, additionally supported by peers, may help to positively influence cardiorespiratory fitness and muscle strength in children struggling with cancer after treatment. It is extremely important for children after cancer treatment to feel involved in the school community. Only taking care of all aspects during treatment will allow these goals to be achieved.

### **Conclusions:**

Pediatric patients diagnosed with bone cancer still have to cope with numerous difficulties. Access to healthcare is often difficult, which can cause delays in diagnosis and significantly affect the therapeutic process [23]. Childhood cancers pose a serious health challenge for children and medical personnel. Careful observation is essential. It is worth paying attention

to early symptoms, worrying symptoms. Bone pain in children is a common symptom that can result from both benign and malignant processes. Delay in the diagnosis of a malignant tumor leads to a significant deterioration in prognosis and a decrease in the patient's quality of life after the end of therapy. It is worth paying attention to changes in the body structure of pediatric patients, the appearance of the lower and upper limbs, because the most common location of bone tumors involves the limbs. Any chronic bone pain, pain not caused by trauma should be a red flag and such symptoms require an X-ray. The vast majority of patients are in good shape at the time of diagnosis, which is why multidisciplinary care is necessary so that therapeutic effects are achieved extremely quickly and the quality of life does not deteriorate significantly. It is crucial to provide the child and parents with appropriate help after the diagnosis, and to realistically present all aspects of the disease.

**Disclosure:** Authors do not report any disclosures

**Authors' contribution:** Monika Żybowska-Męczyńska, Bartosz Pawłowski, Michał Sienkiewicz, Dorota Zatloka-Mazur, Filip Klimas, Kacper Rusiński, Adriana Potoczek, Iwona Pudełko, Zuzanna Zięba, Natalia Szczepanik

**Conceptualization:** Monika Żybowska-Męczyńska, Bartosz Pawłowski, Michał Sienkiewicz

**Methodology:** Monika Żybowska-Męczyńska, Bartosz Pawłowski, Michał Sienkiewicz, Dorota Zatloka-Mazur, Natalia Szczepanik

**Investigation:** Monika Żybowska-Męczyńska, Bartosz Pawłowski, Michał Sienkiewicz, Filip Klimas, Natalia Szczepanik

**Sources:** Filip Klimas, Kacper Rusiński, Adriana Potoczek, Iwona Pudełko, Zuzanna Zięba

**Formal Analysis:** Monika Żybowska-Męczyńska, Bartosz Pawłowski, Michał Sienkiewicz

**Visualization:** Michał Sienkiewicz, Dorota Zatloka-Mazur, Filip Klimas, Kacper Rusiński, Adriana Potoczek, Iwona Pudełko, Zuzanna Zięba, Natalia Szczepanik

**Supervision:** Monika Żybowska-Męczyńska, Bartosz Pawłowski, Michał Sienkiewicz

**Validation:** Monika Żybowska-Męczyńska, Bartosz Pawłowski, Michał Sienkiewicz, Natalia Szczepanik

**Writing- Original Draft:** Monika Żybowska-Męczyńska, Bartosz Pawłowski, Michał Sienkiewicz, Dorota Zatloka-Mazur, Filip Klimas, Kacper Rusiński, Adriana Potoczek, Iwona Pudełko, Zuzanna Zięba, Natalia Szczepanik



**Writing- Review & Editing:** Monika Żybowska-Męczyńska, Bartosz Pawłowski

**Project administration:** Monika Żybowska-Męczyńska, Bartosz Pawłowski, Natalia Szczepanik

**All authors have read and agreed with published version of the manuscript.**

**Funding statement:** No external funding was received to perform this review.

**Conflict of interest:** The authors declare no conflict of interest.

**Statement of institutional review board:** Not applicable.

**Statement of informed consent:** Not applicable.

**Data availability:** Not applicable.

**Acknowledgments:** Not applicable.

#### **References:**

1. Marmol-Perez A, Ubago-Guisado E, Rodriguez-Solana A, Gil-Cosano JJ, Martinez-Vizcaino V, Cavero-Redondo I, Ruiz JR and Gracia-Marco L (2023), Effect of exercise on bone health in children and adolescents with cancer during and after oncological treatment: A systematic review and meta-analysis. *Front. Physiol.* 14:1088740. doi: 10.3389/fphys.2023.1088740
2. Pediatrics vol. 1, Wanda Kawalec, Ryszard Grenda, Marek Kulus, PZWL, ISBN: 9788301236359
3. Zarghooni K, Bratke G, Landgraf P, Simon T, Maintz D, Eysel P. The Diagnosis and Treatment of Osteosarcoma and Ewing's Sarcoma in Children and Adolescents. *Dtsch Arztebl Int.* 2023 Jun 16;120(24):405-412. doi: 10.3238/arztebl.m2023.0079. PMID: 37097079; PMCID: PMC10437036.
4. Marin Navarro A, Susanto E, Falk A, Wilhelm M. Modeling cancer using patient-derived induced pluripotent stem cells to understand development of childhood malignancies. *Cell Death Discov.* 2018 Feb 1;4:7. doi: 10.1038/s41420-017-0009-2. PMID: 29531804; PMCID: PMC5841293.
5. Isakoff MS, Bielack SS, Meltzer P, Gorlick R. Osteosarcoma: Current Treatment and a Collaborative Pathway to Success. *J Clin Oncol.* 2015;33(27):3029-3035. doi:10.1200/JCO.2014.59.4895
6. Khan M, Patel R, Youssef M, Banerjee R, Pardiwala A, Belen C. A Systemic Review of Primary Malignant Long Bone Tumors in Children and Adolescents. *Acta Chir*

- Orthop Traumatol Cech. 2024;91(2):77-87. English. doi: 10.55095/ACHOT2024/010. PMID: 38801663.
7. Saucier E, Bougeard G, Gomez-Mascard A, Schramm C, Abbas R, Berlanga P, Briandet C, Castex MP, Corradini N, Coze C, Guerrini-Rousseau L, Guinebretière JM, Khneisser P, Lervat C, Mansuy L, Marec-Berard P, Marie-Cardine A, Mascard E, Saumet L, Tabone MD, Winter S, Frebourg T, Gaspar N, Brugieres L. Li-Fraumeni-associated osteosarcomas: The French experience. *Pediatr Blood Cancer*. 2024 Dec;71(12):e31362. doi: 10.1002/pbc.31362. Epub 2024 Oct 10. PMID: 39387369
  8. Le Vu B, de Vathaire F, Shamsaldin A, Hawkins MM, Grimaud E, Hardiman C, Diallo I, Vassal G, Bessa E, Campbell S, Panis X, Daly-Schveitzer N, Lagrange JL, Zucker JM, Eschwège F, Chavaudra J, Lemerle J. Radiation dose, chemotherapy and risk of osteosarcoma after solid tumours during childhood. *Int J Cancer*. 1998 Jul 29;77(3):370-7. doi: 10.1002/(sici)1097-0215(19980729)77:3<370::aid-ijc11>3.0.co;2-c. PMID: 9663598.
  9. Tan GJS, Gerrand CH, Rankin KS. Blood-borne biomarkers of osteosarcoma: A systematic review. *Pediatr Blood Cancer*. 2019 Jan;66(1):e27462. doi: 10.1002/pbc.27462. Epub 2018 Sep 24. PMID: 30251311.
  10. <https://emedicine.medscape.com/article/988516-overview?form=fpf>
  11. Durer S, Gasalberti DP, Shaikh H. Ewing Sarcoma. 2024 Jan 8. In: StatPearls [Internet]. Treasure Island (FL): StatPearls Publishing; 2025 Jan-. PMID: 32644609.
  12. Bernstein M, Kovar H, Paulussen M, et al. Ewing sarcoma family of tumors: Ewing sarcoma of bone and soft tissue and the peripheral primitive neuroectodermal tumors. In: Pizzo PA, Poplack DG, editors. *Principles and practice of pediatric oncology*. 5th. Lippincott Williams & Wilkins; 2006. pp. 1002–32
  13. <https://www.dana-farber.org/cancer-care/types/childhood-osteosarcoma>
  14. Zarghooni K, Bratke G, Landgraf P, Simon T, Maintz D, Eysel P. The Diagnosis and Treatment of Osteosarcoma and Ewing's Sarcoma in Children and Adolescents. *Dtsch Arztebl Int*. 2023 Jun 16;120(24):405-412. doi: 10.3238/arztebl.m2023.0079. PMID: 37097079; PMCID: PMC10437036.]
  15. Cerase A, Priolo F. Skeletal benign bone-forming lesions. *Eur J Radiol*. 1998 May;27 Suppl 1:S91-7. doi: 10.1016/s0720-048x(98)00049-7. PMID: 9652508.

16. Grimer RJ. Size matters for sarcomas! *Ann R Coll Surg Engl.* 2006 Oct;88(6):519-24. doi: 10.1308/003588406X130651. PMID: 17059708; PMCID: PMC1963770.
17. *Pediatrics* Tom Lissauer, Graham Clayden red. wyd. pol. Andrzej Milanowski Wydawca: Edra Urban & Partner ISBN: 9788376098159, 2023]
18. Miller KD, Fidler-Benaoudia M, Keegan TH, Hipp HS, Jemal A, Siegel RL. Cancer statistics for adolescents and young adults, 2020. *CA Cancer J Clin.* 2020 Nov;70(6):443-459. doi: 10.3322/caac.21637. Epub 2020 Sep 17. PMID: 32940362.
19. Lingerih T, Yeshiwas S, Mohamedsaid A, Arega G. Patterns and treatment outcomes of primary bone tumors in children treated at tertiary referral hospital, Ethiopia. *BMC Cancer.* 2024 Mar 28;24(1):394. doi: 10.1186/s12885-024-12169-x. PMID: 38549062; PMCID: PMC10976724.].
20. Collins DE, Ellis SJ, Janin MM, Wakefield CE, Bussey K, Cohn RJ, Lah S, Fardell JE. A Systematic Review Summarizing the State of Evidence on Bullying in Childhood Cancer Patients/Survivors [Formula: see text]. *J Pediatr Oncol Nurs.* 2019 Jan/Feb;36(1):55-68. doi: 10.1177/1043454218810136. Epub 2018 Nov 8. PMID: 30406714
21. Storch EA, Milsom VA, Debraganza N, Lewin AB, Geffken GR, Silverstein JH. Peer victimization, psychosocial adjustment, and physical activity in overweight and at-risk-for-overweight youth. *J Pediatr Psychol.* 2007 Jan-Feb;32(1):80-9. doi: 10.1093/jpepsy/jsj113. Epub 2006 Apr 6. PMID: 16601255.
22. Fridh, M.K., Schmidt-Andersen, P., Andrés-Jensen, L. et al. Children with cancer and their cardiorespiratory fitness and physical function—the long-term effects of a physical activity program during treatment: a multicenter non-randomized controlled trial. *J Cancer Surviv* (2023). <https://doi.org/10.1007/s11764-023-01499-7>
23. Miller KD, Fidler-Benaoudia M, Keegan TH, Hipp HS, Jemal A, Siegel RL. Cancer statistics for adolescents and young adults, 2020. *CA Cancer J Clin.* 2020: 70: 443-459. <https://doi.org/10.3322/caac.21637>