



A review of oculoplastic surgery and ocular surface disorders

Mukaddes Damla Ciftci¹ and Ozlem Barut Selver¹

¹ Ege University Faculty of Medicine, Department of Ophthalmology, Izmir, Turkey

ABSTRACT

Background: Ocular surface health is closely related to the condition of the ocular adnexa, particularly the eyelids. Both ocular adnexal disorders and oculoplastic procedures performed to treat them can cause ocular surface disorders (OSD). In this review, we aimed to summarize the relationship between oculoplastic procedures and OSD.

Methods: In this narrative review, an electronic search of the PubMed/MEDLINE database was conducted using various combinations of keywords including “oculoplastic surgery,” “ocular surface disorders,” “dry eye,” and “management,” without time or language limitations, to include studies concerning oculoplastic surgery and OSD.

Results: We included articles involving oculoplastic procedures and OSD with discussions of preventive approaches and management strategies in this context. For a systematic approach, the preoperative assessments and postoperative treatment of patients were retrieved and summarized. Preoperative preventive measures included evaluation of tear film break-up time, tear osmolarity, tear meniscus area and height measurement by anterior segment optic coherence tomography, lipid layer thickness by interferometer, corneal staining and Oxford Scheme, Schirmer test, blink rate and completeness, ocular surface disease index scoring, eyelid closure, and Bell’s phenomenon. Postoperative assessments included the presence and severity of dry eye and early management of dry eye with artificial tears, topical anti-inflammatory medications, and night taping; evaluation of the presence of chemosis, and, if present, management with pharmacologic, mechanical, or surgical therapies when needed; and prompt detection and treatment of lagophthalmos and consequent exposure keratopathy.

Conclusions: Careful preoperative examination of the ocular surface is mandatory to reduce or eliminate complications after oculoplastic surgery. Ocular surface-related complications that surgeons encounter after oculoplastic surgery should be promptly diagnosed and treated.

KEYWORDS

ectropion, entropion, lagophthalmos, ocular surface, oculoplastic, surgery

INTRODUCTION

Ocular surface disorders (OSD) represent a spectrum of diseases that affect the eye surface. Different OSD cause overlapping signs and symptoms, such as redness, tearing, irritation, foreign body sensation, light sensitivity, and intermittent blurred vision. Dry eye is the most common form of OSD, with an incidence ranging from 5.7% to 21.6% [1, 2]. The integrity of the ocular surface ecosystem is maintained by the functions of the tear film, lids and their adnexa, blink reflex, and lacrimal apparatus [3], which implies a mutual relationship between these structures.

Correspondence: Ozlem Barut Selver, Department of Ophthalmology, Ege University Medical Faculty Hospital, 35100 Bornova-Izmir, Turkey. Email: ozlembarutselver@gmail.com. ORCID iD: <https://orcid.org/0000-0003-3333-3349>

How to cite this article: Ciftci MD, Barut Selver O. A review of oculoplastic surgery and ocular surface disorders. Med Hypothesis Discov Innov Optom.2022 Spring; 3(1): 5-11. <https://doi.org/10.51329/mehdiptometry144>

Received: 03 July 2022; Accepted: 01 September 2022



Copyright © Author(s). This is an open-access article distributed under the terms of the Creative Commons Attribution-NonCommercial 4.0 International License (<https://creativecommons.org/licenses/by-nc/4.0/>) which permits copy and redistribute the material just in noncommercial usages, provided the original work is properly cited.

Table 1. Practical approach to oculoplastic surgeries and ocular surface disorders

Preoperative Preventive Measures	Postoperative Assessment and Management
Detailed drug history (i.e. medications with drying effects such as antihistamines, antidepressants, thiazides or osmotic diuretics, and hormone replacement therapy [9]).	Watch for lower lid malposition [9].
History of laser vision correction [9].	Evaluation of presence and severity of dry eye [4].
Tear film break-up time [10, 11], corneal staining and Oxford Scheme [10, 11].	Early management of dry eye with artificial tears, topical anti-inflammatory medications, and night taping [7, 16].
Schirmer test [10, 12, 13], tear osmolarity [11], lipid layer thickness by interferometer [14, 15], and blink rate and completeness [4].	Evaluation of presence of chemosis, and if present, management with pharmacologic, mechanical, or surgical therapies when needed [17].
Tear meniscus area and height measurement by anterior segment optic coherence tomography [10].	Detection and early treatment of lagophthalmos and consequent exposure keratopathy [4].
Recording ocular surface disease index (OSDI) score [14].	Consider the optimal time for refractive surgery after blepharoplasty [18].
Check for eyelid closure and Bell's Phenomenon [4].	Careful follow-up for at least 3 months postoperatively [8].

Structural abnormalities of the ocular adnexa, such as entropion, ectropion, and lagophthalmos, can cause or aggravate pre-existing OSD [4], and it is therefore necessary to evaluate and optimize them prior to oculoplastic procedures. Conservative blepharoplasty for dermatochalasis with coexisting dry eye symptoms alleviates postoperative symptoms [5]. Therefore, vigilant preoperative assessment to identify OSD and dry eye is pivotal when planning oculoplastic surgery.

However, oculoplastic procedures can also cause OSD. Blepharoptosis repair and upper eyelid blepharoplasty themselves may lead to dry eye of varying severity [6]. The short-term effects of cosmetic blepharoplasty on tear film dynamics and deterioration of dry eye symptoms [7], the ocular surface, and tear fluid dynamics [8] have been reported. Blepharoplasty could unmask underlying tear film deficiencies due to transient postoperative lagophthalmos of the upper lid [9], highlighting the necessity of a careful preoperative evaluation to identify and manage this and improve postoperative satisfaction.

In this review, we aim to summarize the relationship between oculoplastic procedures and OSD and to propose recommendations for the prevention and management of OSD in this context.

METHODS

For this narrative review, we conducted an electronic search of the PubMed/MEDLINE database using various combinations of keywords including “oculoplastic surgery,” “ocular surface disorders,” “dry eye,” and “management,” without time or language limitations, to include studies involving oculoplastic surgery and OSD. We reviewed titles and abstracts of the retrieved articles, and relevant studies were included in this review.

RESULTS

We included articles concerning oculoplastic procedures and OSD that included discussions of preventive approaches and management strategies in this context. Detailed evaluation of patients before oculoplastic surgery is at least as important as the surgery itself. Patients should be evaluated for blinks, static and dynamic features of the eyelids, eyelashes, meibomian gland function, Bell's phenomenon, fornices, eye movements, and the presence and severity of dry eye [4]. A systematic approach to preoperative or postoperative oculoplastic cases could be evaluation of blinking, eyelid closure and Bell's phenomenon, eyelid position, eyelid margin inflammation, and dry eye. We further discuss the details of these evaluations, and we present the retrieved recommendations on the pre- and postoperative prevention and management of OSD in Table 1.

DISCUSSION

Evaluation of Blinking: Tear film homeostasis is sustained by the lacrimal functional unit composed of tear-secreting glands and their neuronal and immunological components [19]. *Blink* is defined as a fast eyelid movement that closes and opens the palpebral fissure [20]. Blink disorders impair the tear film. Blinking should be evaluated for frequency and completeness. Blink rates vary among healthy individuals, ranging from 3 to

26 per minute. Different mental activities affect blinking frequency. For example, the blink rate increases when engaged in conversation; in contrast, when focusing on a specific visual task, the blink rate decreases. A *complete blink* is defined as coverage of two-thirds or more of the corneal surface by the eyelid [4, 21]. An effective blink is defined by three characteristics: complete, brief, and soft, meaning that only the eyelid muscles participate in the unforced action [22]. Control of blinking is mediated by the integration of autonomic and voluntary neural controls [23].

A reduced blink rate is associated with increased tear evaporation [24]. A decreased blink rate can also be caused by different pathological conditions such as decreased corneal sensitivity, neurotrophic keratopathy, and extrapyramidal disorders [4, 25]. Either orbicularis muscle excision or eyelid swelling could reduce the blink rate [7], promoting the evaporative loss of tears [8]. However, an increased blinking rate is associated with ocular surface irritation [26].

Evaluation of Eyelid Closure and Bell's Phenomenon: *Lagophthalmos* is defined as a defect in complete closure of the eye, and it can be *notch* or *generalized* [4]. Notch lagophthalmos is caused by local defects of the eyelids. Coloboma of the eyelid, trauma, and surgery can all cause notch lagophthalmos [4]. The main cause of generalized lagophthalmos is facial nerve paralysis with resulting orbitalis oculi dysfunction, also called *paralytic lagophthalmos*. The most common cause of paralytic lagophthalmos is Bell's palsy. Lagophthalmos that occurs during sleep is called *nocturnal lagophthalmos* [27], which can cause exposure keratopathy, especially in the inferior cornea, and is associated with dry eye symptoms. The diagnosis can be challenging because there are no changes in the eyelids during the daytime. This entity is associated with dry eye disease, and patients may develop symptomatic OSD [28]. Additionally, multiple eyelid surgeries may cause orbicularis weakness [4]. *Cicatricial lagophthalmos* is caused by trauma or surgery that results in excessive scarring of the eyelids [27].

Exposure keratopathy is the main complication of lagophthalmos [29], and it may have devastating effects on the ocular surface. Figure 1 shows an anterior segment photograph of a patient with Bell's palsy, lagophthalmos, and corneal pannus as a result of chronic exposure. Lagophthalmos should initially be evaluated during gentle eye closure. Eventually, it should be evaluated during forced closure to determine possible orbicularis weakness [4].

Bell's phenomenon is described as an upward deviation of the eye during forcible eyelid closure. Present in more than 80% of adults, it is a protective reflex to avoid corneal exposure during eyelid closure [30]. The neural mechanism of Bell's phenomenon has yet to be identified, and no areas in the frontal eye field were found to be activated with regard to Bell's phenomenon [31]. This reflex reduces exposure risk and protects the tear film and ocular surface in patients with lagophthalmos. Before ptosis surgery, clinicians should assess for the presence of Bell's phenomenon [32]. In addition to a comprehensive physical examination, evaluation for the presence of Bell's phenomenon should be performed in all patients before blepharoplasty [9].

Evaluation of Eyelid Position: Dermatochalasis [5] and blepharoptosis [6] are upper eyelid disorders frequently encountered in ophthalmology. Treatment with upper eyelid blepharoplasty can lead to postoperative dry eye of varying severities. Upper eyelid surgery can affect the lacrimal, accessory lacrimal, and meibomian

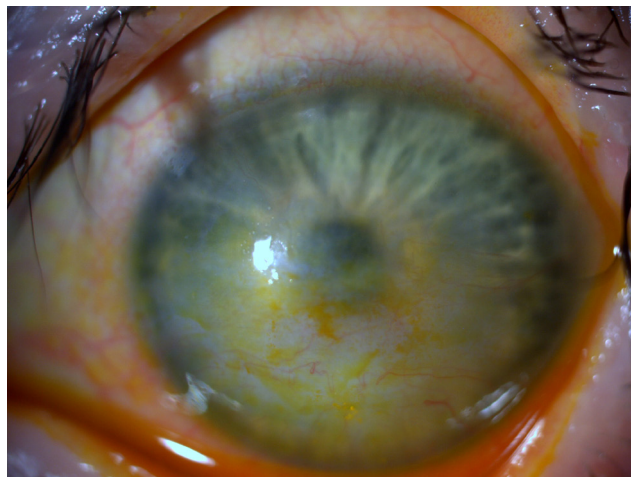


Figure 1. Anterior segment photograph of a patient with Bell's palsy that caused lagophthalmos and subsequent corneal pannus as a result of chronic exposure.

glands. This may negatively affect tear production. Aksu Ceylan et al. [6] found that upper eyelid blepharoplasty and levator advancement ptosis surgery led to a decrease in the Schirmer test results six months after the procedure. Studies have reported that dry eye and ocular irritation symptoms after upper eyelid blepharoplasty and blepharoptosis repair can regress within weeks after surgery [33, 34]. Figure 2 shows anterior segment photographs of corneal dellen formation in a patient after upper eyelid blepharoplasty.

Entropion is defined as the inversion of the eyelid border against the eyeball. It can be the cause or the result of OSD. Chronic cicatricial diseases such as ocular cicatricial pemphigoid can cause subconjunctival scarring and entropion [35]. Likewise, entropion can lead to ocular surface irritation and, eventually, OSD. Patients with entropion should be evaluated carefully for meibomian gland dysfunction and OSD [36]. Figure 3 shows an anterior segment photograph of a patient with entropion and inferior corneal pannus.

Ectropion is the outward turning of the eyelid margin, which typically occurs on the lower eyelid. It can cause exposure of the ocular surface, punctate epithelial erosions, and corneal ulceration. Management generally begins with the use of artificial tears. Surgical repair is commonly needed to improve eyelid function [37]. Clinicians can identify entropion or ectropion preoperatively using careful slit-lamp examination.

Evaluation of Eyelid Margin Inflammation and Dry Eye: *Blepharitis* is a chronic inflammatory disease of the eyelid margin. It may occur in patients of any age. It may be associated with many ocular conditions such as meibomian gland dysfunction and evaporative dry eye. Systemic diseases, such as rosacea, may be associated with blepharitis and recurrent hordeolum. A long-term commitment to eyelid hygiene is essential [38]. Candidates for blepharoplasty should be carefully evaluated for the presence of blepharitis.

According to the Tear Film and Ocular Surface Society Dry Eye Workshop II (TFOS DEWS II) [39], dry eye is a multifactorial ocular surface disease. It is characterized by tear film instability, tear hyperosmolarity, and

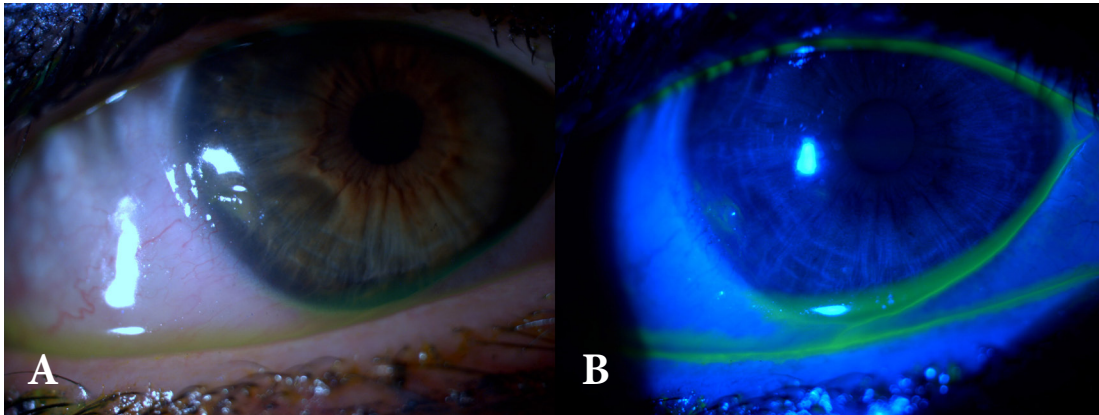


Figure 2. (A) and (B) show saucer-like depressions in the nasal aspect of the corneal surface, consistent with corneal dellen formation in a patient with a previous upper eyelid blepharoplasty.

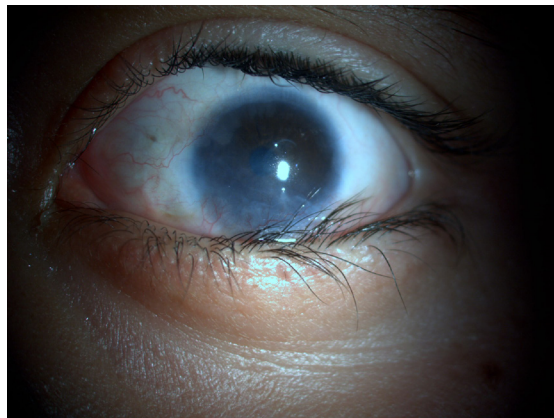


Figure 3. Anterior segment photograph of a patient with misdirected eyelashes due to lower eyelid entropion, which abraded the cornea and led to inferior corneal pannus.

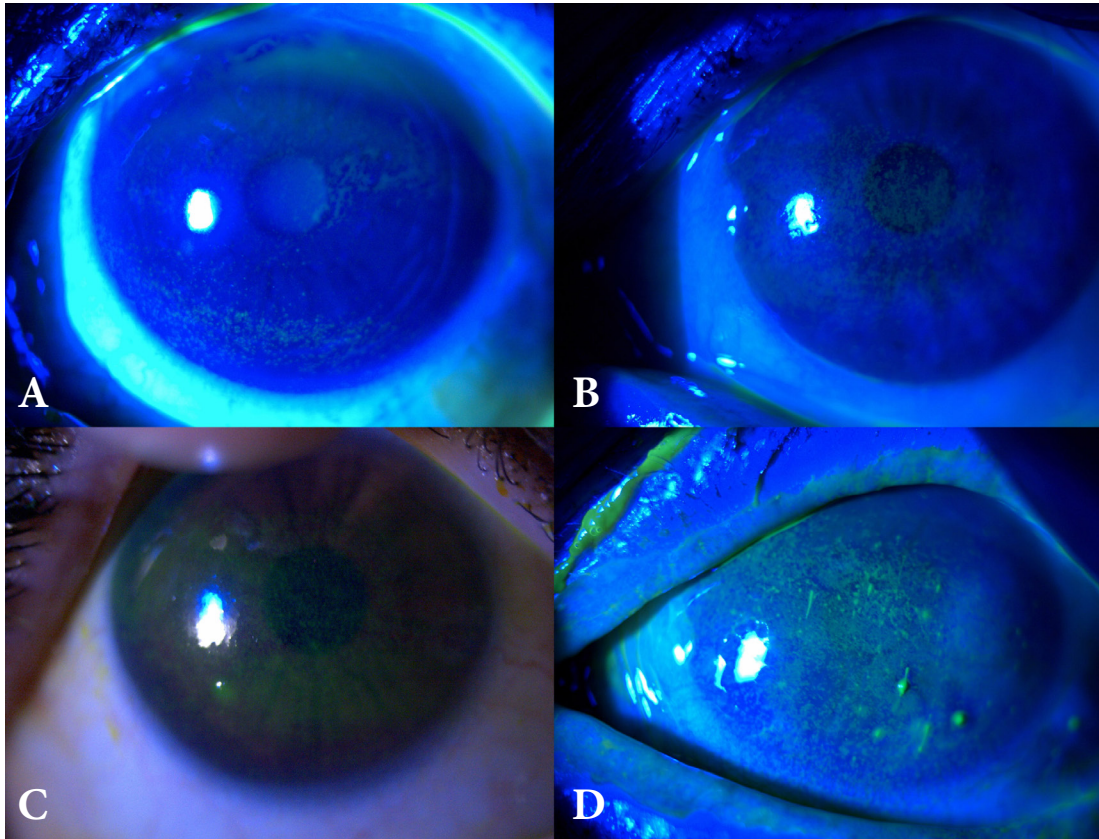


Figure 4. These anterior segment slit-photographs represent (A) grade 1, (B) grade 2, (C) grade 3, and (D) grade 4 staining of the ocular surface with fluorescein according to the Oxford Scale.

ocular surface inflammation. Oculoplastic procedures can worsen pre-existing dry eye due to anatomical changes and provoked inflammation. Patients should be investigated for dry eye and graded according to severity both pre- and postoperatively. The Oxford Scheme can be used to estimate surface damage in dry eye by ocular surface staining with fluorescein [40]. Figure 4 demonstrates the different grades of dry eye according to the Oxford Scheme.

The present review had several limitations, including the use of a single indexing source and the presence of few relevant primary studies. However, it highlights that OSD could temporarily affect patient satisfaction after blepharoplasty. Patients interested in blepharoplasty may benefit from a formal preoperative evaluation to identify subclinical signs of OSD. Patients should be informed that irritation, tearing, and dryness may occur postoperatively, especially when there are predisposing risk factors in preoperative assessments. Careful postoperative examination and management are recommended to enhance the ocular surface integrity. Patients should be instructed to report postoperative symptoms related to OSD for timely management. Excellent surgeon and patient education, as well as careful preoperative evaluation and postoperative follow-up, can improve oculoplastic surgery outcomes and reduce complication rates. Future studies focusing on patient instructions may prove useful in more thoroughly evaluating the effects of patient education and awareness. Moreover, further primary studies may shed light on the relationship between oculoplastic surgery and OSD.

CONCLUSIONS

Oculoplastic procedures have become more common in recent years for both cosmetic and functional purposes. The procedures themselves can cause or worsen OSD. In contrast, OSD and ocular adnexal disorders may coexist. Patients undergoing oculoplastic surgery should be carefully examined for OSD, both preoperatively and postoperatively, and appropriate treatment should be initiated when necessary.

ETHICAL DECLARATIONS

Ethical approval: Informed consent was obtained from all individuals whose anterior segment photographs are used as figures.

Conflict of interests: None

FUNDING

None.

ACKNOWLEDGEMENTS

None.

REFERENCES

- Schaumberg DA, Sullivan DA, Buring JE, Dana MR. Prevalence of dry eye syndrome among US women. *Am J Ophthalmol.* 2003;136(2):318-26. doi: 10.1016/s0002-9394(03)00218-6 pmid: 12888056
- Moss SE, Klein R, Klein BE. Long-term incidence of dry eye in an older population. *Optom Vis Sci.* 2008;85(8):668-74. doi: 10.1097/OPX.0b013e318181a947 pmid: 18677233
- Rao SK, Mohan R, Gokhale N, Matalia H, Mehta P. Inflammation and dry eye disease-where are we? *Int J Ophthalmol.* 2022;15(5):820-827. doi: 10.18240/ijo.2022.05.20 pmid: 35601175
- Avisar I, Nahum Y, Mimouni M, Kremer I, Malhotra R. Oculoplastic aspects of ocular surface disease and their management. *Surv Ophthalmol.* 2020;65(3):312-322. doi: 10.1016/j.survophthal.2019.11.003 pmid: 31837384
- Floegel I, Horwath-Winter J, Muellner K, Haller-Schober EM. A conservative blepharoplasty may be a means of alleviating dry eye symptoms. *Acta Ophthalmol Scand.* 2003;81(3):230-2. doi: 10.1034/j.1600-0420.2003.00064.x pmid: 12780399
- Aksu Ceylan N, Yeniad B. Effects of Upper Eyelid Surgery on the Ocular Surface and Corneal Topography. *Turk J Ophthalmol.* 2022;52(1):50-56. doi: 10.4274/tjo.galenos.2021.63255 pmid: 35196840
- Yan Y, Zhou Y, Zhang S, Cui C, Song X, Zhu X, et al. Impact of Full-Incision Double-Eyelid Blepharoplasty on Tear Film Dynamics and Dry Eye Symptoms in Young Asian Females. *Aesthetic Plast Surg.* 2020;44(6):2109-2116. doi: 10.1007/s00266-020-01874-0 pmid: 32696159
- Shao C, Fu Y, Lu L, Chen J, Shen Q, Zhu H, et al. Dynamic changes of tear fluid after cosmetic transcutaneous lower blepharoplasty measured by optical coherence tomography. *Am J Ophthalmol.* 2014;158(1):55-63.e1. doi: 10.1016/j.ajo.2014.03.016 pmid: 24709809
- Lee WB, McCord CD Jr, Somia N, Hirmand H. Optimizing blepharoplasty outcomes in patients with previous laser vision correction. *Plast Reconstr Surg.* 2008;122(2):587-594. doi: 10.1097/PRS.0b013e31817d61d9 pmid: 18626378
- Aydemir E, Aksoy Aydemir G. Changes in Tear Meniscus Analysis After Ptosis Procedure and Upper Blepharoplasty. *Aesthetic Plast Surg.* 2022;46(2):732-741. doi: 10.1007/s00266-021-02613-9 pmid: 34590166
- Hollander MHJ, Pott JWR, Delli K, Vissink A, Schepers RH, Jansma J. Impact of upper blepharoplasty, with or without orbicularis oculi muscle removal, on tear film dynamics and dry eye symptoms: A randomized controlled trial. *Acta Ophthalmol.* 2022;100(5):564-571. doi: 10.1111/aos.15036 pmid: 34612583
- Mainville N, Jordan DR. Etiology of tearing: a retrospective analysis of referrals to a tertiary care oculoplastics practice. *Ophthalmic Plast Reconstr Surg.* 2011;27(3):155-7. doi: 10.1097/IOP.0b013e3181ef728d pmid: 20940663
- Turker IC, Dogan CU. Evaluating the Effects of Upper Eyelid Blepharoplasty on Tear Film Quality and Intraocular Pressure. *Beyoglu Eye J.* 2020;5(3):169-173. doi: 10.14744/bej.2020.81300 pmid: 35098083
- Zhang S, Yan Y, Lu Y, Zhou Y, Fu Y. Effect of Transcutaneous Upper Eyelid Blepharoplasty on Blink Parameters and Lipid Layer Thickness. *Front Med (Lausanne).* 2021;8:732041. doi: 10.3389/fmed.2021.732041 pmid: 34881256
- Holtmann C, Finis D, Knop E, Borrelli M, Geerling G. Lateral Canthal Sling Procedure for Meibomian Gland Dysfunction? Results of a Pilot Study. *Curr Eye Res.* 2021;46(10):1489-1494. doi: 10.1080/02713683.2021.1896741 pmid: 33749468
- Hamawy AH, Farkas JP, Fagien S, Rohrich RJ. Preventing and managing dry eyes after periorbital surgery: a retrospective review. *Plast Reconstr Surg.* 2009;123(1):353-359. doi: 10.1097/PRS.0b013e31819346ea pmid: 19116572
- Weinfeld AB, Burke R, Codner MA. The comprehensive management of chemosis following cosmetic lower blepharoplasty. *Plast Reconstr Surg.* 2008;122(2):579-586. doi: 10.1097/PRS.0b013e31818001d0 pmid: 18626377
- Victoria AC, Chuck RS, Rosenberg J, Schwarcz RM. Timing of eyelid surgery in the setting of refractive surgery: preoperative and postoperative considerations. *Curr Opin Ophthalmol.* 2011;22(4):226-32. doi: 10.1097/ICU.0b013e318328347b275 pmid: 21654396
- Stern ME, Gao J, Siemasko KF, Beuerman RW, Pflugfelder SC. The role of the lacrimal functional unit in the pathophysiology of dry eye. *Exp Eye Res.* 2004;78(3):409-16. doi: 10.1016/j.exer.2003.09.003 pmid: 15106920
- Cruz AA, Garcia DM, Pinto CT, Cechetti SP. Spontaneous eyeblink activity. *Ocul Surf.* 2011;9(1):29-41. doi: 10.1016/s1542-0124(11)70007-6 pmid: 21338567
- Abelson R, Lane KJ, Angeli E, Johnston P, Ousler G, Montgomery D. Measurement of ocular surface protection under natural blink conditions. *Clin Ophthalmol.* 2011;5:1349-57. doi: 10.2147/OPHTH.S22017 pmid: 22034554
- McMonnies CW. Diagnosis and remediation of blink inefficiency. *Cont Lens Anterior Eye.* 2021;44(3):101331. doi: 10.1016/j.clae.2020.04.015 pmid: 32499135

23. Abi-Jaoude E, Segura B, Cho SS, Crawley A, Sandor P. The Neural Correlates of Self-Regulatory Fatigability During Inhibitory Control of Eye Blinking. *J Neuropsychiatry Clin Neurosci*. 2018;30(4):325-333. doi: [10.1176/appi.neuropsych.17070140](https://doi.org/10.1176/appi.neuropsych.17070140) pmid: 29843584
24. The definition and classification of dry eye disease: report of the Definition and Classification Subcommittee of the International Dry Eye WorkShop (2007). *Ocul Surf*. 2007;5(2):75-92. doi: [10.1016/s1542-0124\(12\)70081-2](https://doi.org/10.1016/s1542-0124(12)70081-2) pmid: 17508116
25. Naase T, Doughty MJ, Button NF. An assessment of the pattern of spontaneous eyeblink activity under the influence of topical ocular anaesthesia. *Graefes Arch Clin Exp Ophthalmol*. 2005;243(4):306-12. doi: [10.1007/s00417-004-0990-z](https://doi.org/10.1007/s00417-004-0990-z) pmid: 15864619
26. Alex A, Edwards A, Hays JD, Kerkstra M, Shih A, de Paiva CS, et al. Factors predicting the ocular surface response to desiccating environmental stress. *Invest Ophthalmol Vis Sci*. 2013;54(5):3325-32. doi: [10.1167/iovs.12-11322](https://doi.org/10.1167/iovs.12-11322) pmid: 23572103
27. Pereira MV, Glória AL. Lagophthalmos. *Semin Ophthalmol*. 2010;25(3):72-8. doi: [10.3109/08820538.2010.488578](https://doi.org/10.3109/08820538.2010.488578) pmid: 20590416
28. Takahashi A, Negishi K, Ayaki M, Uchino M, Tsubota K. Nocturnal Lagophthalmos and Sleep Quality in Patients with Dry Eye Disease. *Life (Basel)*. 2020;10(7):105. doi: [10.3390/life10070105](https://doi.org/10.3390/life10070105) pmid: 32635438
29. Gire A, Kwok A, Marx DP. PROSE treatment for lagophthalmos and exposure keratopathy. *Ophthalmic Plast Reconstr Surg*. 2013;29(2):e38-40. doi: [10.1097/IOP.0b013e3182674069](https://doi.org/10.1097/IOP.0b013e3182674069) pmid: 23034688
30. Lee JE, Park JM, Choi HY, Oum BS. Bell's phenomenon during screening examination for retinopathy of prematurity. *Korean J Ophthalmol*. 2012;26(3):189-94. doi: [10.3341/kjo.2012.26.3.189](https://doi.org/10.3341/kjo.2012.26.3.189) pmid: 22670075
31. Suzuki Y, Kiyosawa M, Ishiwata K, Oda K, Ishii K. Cerebral Functional Response during Eyelid Opening/Closing with Bell's Phenomenon and Volitional Vertical Eye Movements in Humans. *Tohoku J Exp Med*. 2016;240(2):141-146. doi: [10.1620/tjem.240.141](https://doi.org/10.1620/tjem.240.141) pmid: 27725571
32. Yoon JS, Lew H, Lee SY. Bell's phenomenon protects the tear film and ocular surface after frontalis suspension surgery for congenital ptosis. *J Pediatr Ophthalmol Strabismus*. 2008;45(6):350-5. doi: [10.3928/01913913-20081101-17](https://doi.org/10.3928/01913913-20081101-17) pmid: 19043946
33. Kim HH, De Paiva CS, Yen MT. Effects of upper eyelid blepharoplasty on ocular surface sensation and tear production. *Can J Ophthalmol*. 2007;42(5):739-42. doi: [10.3129/i07-141](https://doi.org/10.3129/i07-141) pmid: 17823642
34. Zhao S, Song N, Gong L. Changes of Dry Eye Related Markers and Tear Inflammatory Cytokines After Upper Blepharoplasty. *Front Med (Lausanne)*. 2021;8:763611. doi: [10.3389/fmed.2021.763611](https://doi.org/10.3389/fmed.2021.763611) pmid: 34957146
35. Ross AH, Cannon PS, Selva D, Malhotra R. Management of upper eyelid cicatricial entropion. *Clin Exp Ophthalmol*. 2011;39(6):526-36. doi: [10.1111/j.1442-9071.2011.02503.x](https://doi.org/10.1111/j.1442-9071.2011.02503.x) pmid: 21819506
36. Yang MK, Sa HS, Kim N, Jeon HS, Hyon JY, Choung H, et al. Quantitative analysis of morphological and functional alterations of the meibomian glands in eyes with marginal entropion. *PLoS One*. 2022;17(4):e0267118. doi: [10.1371/journal.pone.0267118](https://doi.org/10.1371/journal.pone.0267118) pmid: 35421204
37. Ozgur O, Kaufman EJ. Entropion. 2022. In: StatPearls [Internet]. Treasure Island (FL): StatPearls Publishing; 2022 Jan-. pmid: 28722958
38. Bernardes TF, Bonfioli AA. Blepharitis. *Semin Ophthalmol*. 2010;25(3):79-83. doi: [10.3109/08820538.2010.488562](https://doi.org/10.3109/08820538.2010.488562) pmid: 20590417
39. Craig JP, Nichols KK, Akpek EK, Caffery B, Dua HS, Joo CK, et al. TFOS DEWS II Definition and Classification Report. *Ocul Surf*. 2017;15(3):276-283. doi: [10.1016/j.jtos.2017.05.008](https://doi.org/10.1016/j.jtos.2017.05.008) pmid: 28736335
40. Bron AJ, Evans VE, Smith JA. Grading of corneal and conjunctival staining in the context of other dry eye tests. *Cornea*. 2003;22(7):640-50. doi: [10.1097/00003226-200310000-00008](https://doi.org/10.1097/00003226-200310000-00008) pmid: 14508260