



Case Report

# Benign multicystic peritoneal mesothelioma: a case report

Rashmi Sharma<sup>1</sup>, Shobha Verma<sup>2</sup>, Devanshi Desai<sup>3</sup>, Renu Malhotra<sup>1</sup>,  
Ranjana Desai<sup>4</sup>

<sup>1</sup>Govind Diagnostic Clinic, Jodhpur, India

<sup>2</sup>Dr. Shobha Verma Hospital, Bali, India

<sup>3</sup>Jawaharlal Nehru Medical College, Belgaum, India

<sup>4</sup>Dr. Sampurnanand Medical College, Jodhpur, India

## Keywords:

Calretinin;  
Mesothelioma;  
Multicystic;  
Peritoneum;  
Pelvic inflammatory  
disease;

## ABSTRACT

Free-floating peritoneal masses found during laparotomy should arouse a suspicion of benign multicystic peritoneal mesothelioma and they must be removed and subjected to histopathological examination and immunochemical staining to ascertain their benign nature. The objective of the study was to report a rare case of benign multicystic peritoneal mesotheliomas. We report an incidental finding of multiple free-floating peritoneal masses in a pregnant primigravida woman with a normal antenatal course who underwent a cesarean section in a rural hospital setting in India for fetal distress. The masses were removed from the peritoneal cavity during the surgery and subjected to histopathological examination and found to be benign multicystic peritoneal mesotheliomas. Immunohistochemistry of the cysts revealed that the mesothelial cells lining the cysts were positive for calretinin and WT1 and negative for CD31.

## Correspondence:

Dr. Rashmi Sharma

Govind Diagnostic Clinic, Sardarpura, Jodhpur – 342003, India

ORCID ID: 0000-0002-0783-269X

Email : drrashmisharmamd@gmail.com



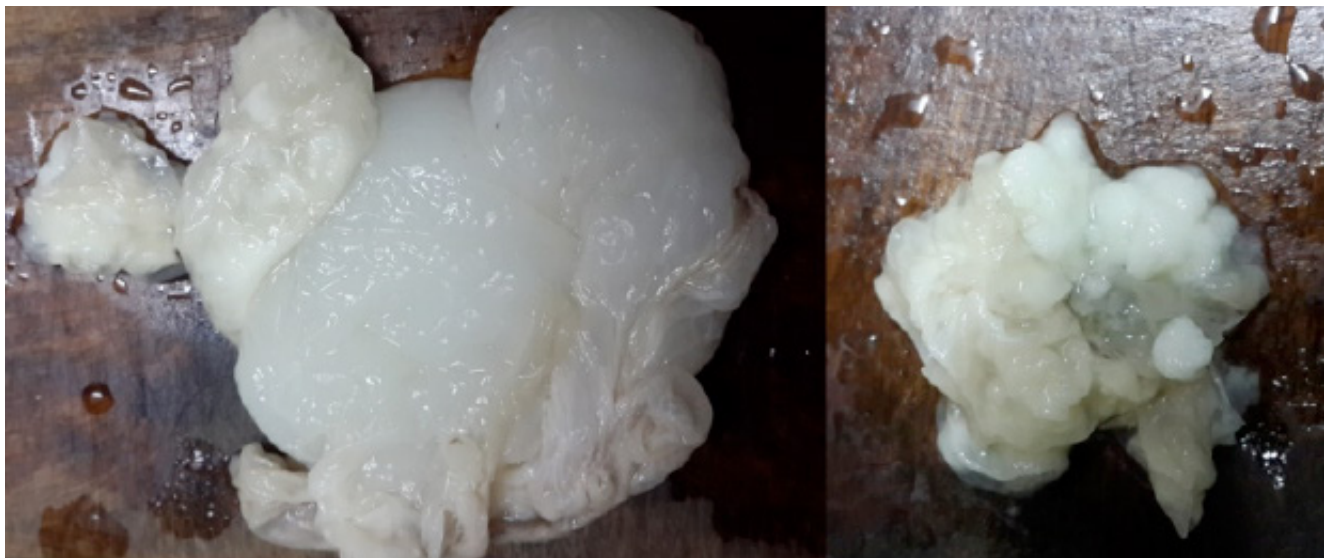
Received : May 25<sup>th</sup> 2020 ; Accepted : September 30<sup>th</sup> 2020

Citation: Sharma R, Verma S, Desai D, Malhotra M, Desai R. Benign Multicystic Peritoneal Mesothelioma: A Case Report. J Pathol Nep 2021;12(2):1864-7. DOI: 10.3126/jpn.v11i2.29114

Copyright: This is an open-access article distributed under the terms of the Creative Commons Attribution 4.0 International License, which permits unrestricted use, distribution, and reproduction in any medium, provided the original author and source are credited.

## INTRODUCTION

Benign multicystic peritoneal mesotheliomas (BMPM) are rare accidental findings in a laparotomy procedure and are usually seen in young women of their reproductive age.<sup>1</sup> They are often associated with prior pelvic surgeries<sup>2</sup>, pelvic inflammatory diseases<sup>2</sup>, endometriosis.<sup>3</sup> They may, at times, complicate pregnancy or may be the cause of acute abdomen.<sup>4</sup> Though considered benign they are prone to recurrence and estrogen can modulate their growth because of the presence of estrogen receptors within the cysts.<sup>5</sup> Until now very few cases have been reported in the literature. When encountered during a routine laparotomy, they present an unusual perplexing diagnostic challenge to a surgeon who is unprepared to see lesions other than for which the



**Figure 1:**(a) Gross appearance of one of the tumor masses. It is white in color with a smooth surface and paper-thin walls. (b) The cut section of a cyst shows that the walls are very thin and the cyst was filled with watery fluid.

primary surgery was indicated. We report this case because of its rarity and the accidental nature of finding them during a routine cesarean section in an asymptomatic patient and the need to recognize it as an obfuscating but benign lesion encountered during routine laparotomy.

### CASE REPORT

A 26-years healthy primigravida was subjected to a cesarean section at term because of a reduction in a fetal heartbeat. There was no prior history of surgery, endometriosis, or inflammatory disease in this patient. She had been asymptomatic during the entire antenatal period and had normal antenatal ultrasound findings. At the time of cesarean section, multiple free-floating masses of size 7 x 4 x 2 and 5 x 4 x 2 cm were seen in the peritoneum which were readily picked up, preserved, and sent for histopathological examination as they were a source of perplexity and concern to the operating surgeon. A healthy female child was delivered. After the closure of the uterus and abdomen, the patient made an uneventful recovery.

The gross examination of the material received consisted of multiple cystic structures collectively measured 9 x 7 x 2 cm. The external surface of the cysts was smooth (fig.1a) The cyst walls were papery thin and on cutting the cysts, they extruded clear fluid mixed with whitish gelatinous material (fig. 1b). Microscopic examination with routine hematoxylin and eosin stain revealed multiple thin-walled cysts lined by mesothelial cells and containing eosinophilic fluid (fig.2a). There were mild inflammatory cells in the stroma between the cysts with foci of mesothelial cell hyperplasia. Hence, the diagnosis of benign cystic mesothelioma/multicystic mesothelioma was made. However, also considering lymphangioma and malignant mesothelioma as differentials, the tumor was subjected to immunohistochemistry which revealed that the mesothelial cells lining the cysts were positive for calretinin (fig. 2b)

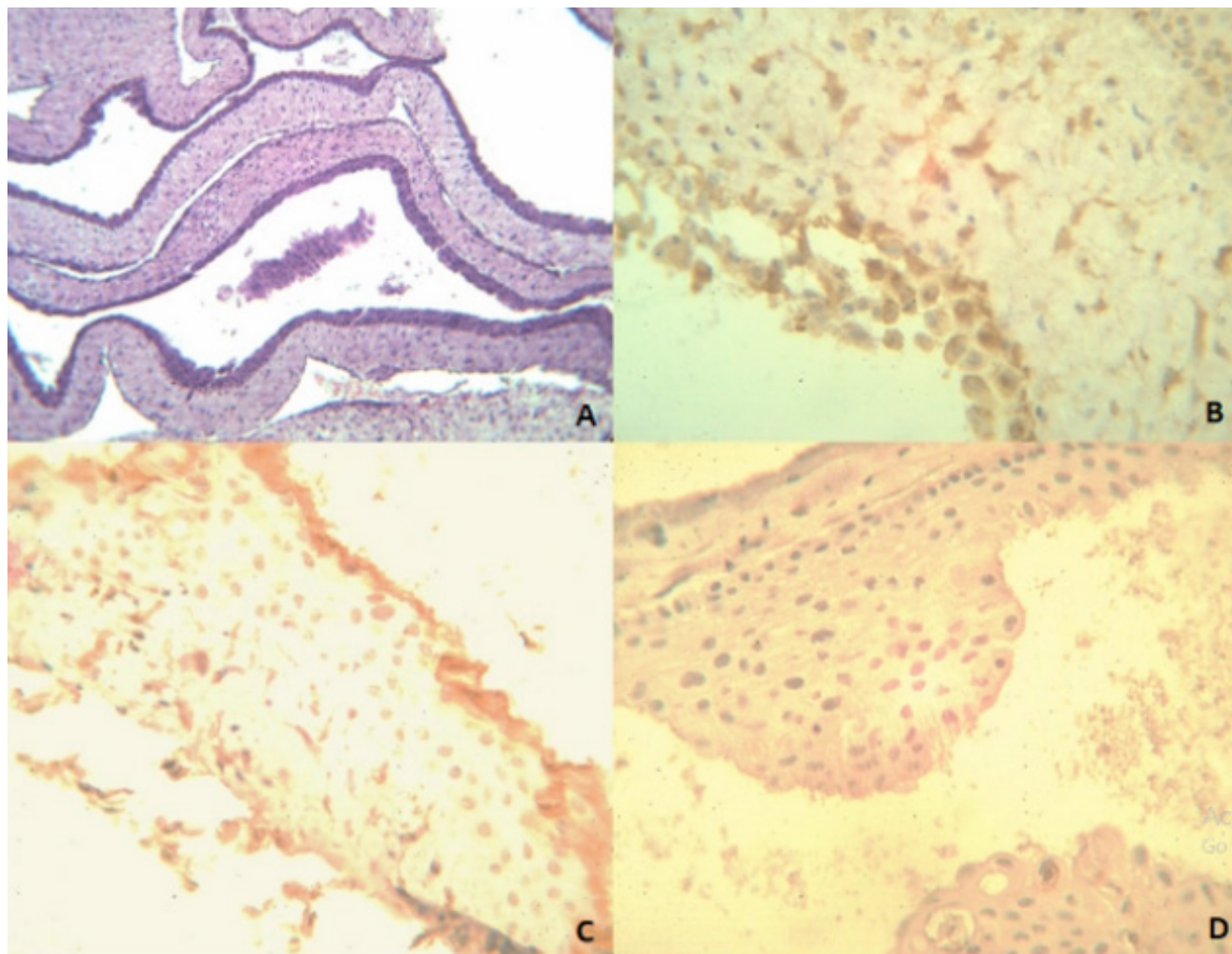
and WT1 (fig.2c) and negative for CD31 (fig.2d). Therefore the diagnosis of benign multicystic mesothelioma was confirmed and upheld.

### DISCUSSION

Benign cystic mesothelioma, also called multicystic mesothelioma, is a rare tumor that usually occurs in women of reproductive age group. Since they are usually asymptomatic, they are difficult to diagnose preoperatively.<sup>6</sup> In our case the patient was a primigravida, married for one and half years, and had no complaints of the disease, which may, sometimes, clinically present as acute/ chronic abdominal pain.<sup>1,3,7</sup>

This tumor was first described by Menemeyer and Smith.<sup>8</sup> Though considered benign these tumors are prone to recurrence.<sup>5</sup> They arise from epithelial and mesenchymal elements of the mesothelioma cells and do not metastasize. They appear as multicystic lesions from the surface of the pelvic viscera, the serosal surface of the intestine, omentum, retroperitoneal space, spleen, and liver. Solitary masses can be seen arising from the basal pleura.<sup>9</sup> They are usually large, maybe multifocal or unilocular. They can also be seen as free-floating cysts<sup>10</sup> as in our case. Microscopically, the cysts are thin-walled and may contain eosinophilic fluid. The mesothelial cells lining the cyst may vary from flattened to endothelial-like to cuboidal. Inflammatory cells are often present within the stroma between cysts, along with focal mesothelial hyperplasia.<sup>11</sup>

The pathogenesis of the tumor has been widely debated regarding its inflammatory or neoplastic origin. Some attribute it to inflammatory processes because of its co-existence with pelvic surgeries, endometriosis, and recurrent pelvic infections.<sup>3</sup> But currently its neoplastic origin is favored because the incidence of its association with previous surgeries is low, and there is no preponderance of



**Figure 2:** (A) (Top Left) Multiple thin-walled cysts lined by mesothelial cells and containing eosinophilic fluid. There were mild inflammatory cells in the stroma between cysts with foci of mesothelial cell hyperplasia (HE stain, X50). (B) Immunohistochemistry of tissue shows that the mesothelial cells lining the cysts are positive for Calretinin. (C) Immunohistochemistry showing mesothelial cells of the cysts are positive for WT-1. (D) Immunohistochemistry showing mesothelial cells of the cysts are negative for CD 31.

BMPM with abdominal infections.

A large case series undertaken to elucidate the role of hormone receptors in the genesis of this tumor has found that two cases were positive with estrogen receptors which indicates its neoplastic origin.<sup>5</sup> Estrogen receptor positivity also impacts the growth and recurrence risk of this tumor which is high; approximately 40 to 50 %. The present case also hints towards a neoplastic origin. Our patient was pregnant and it is well known that both estrogen and progesterone levels are elevated during pregnancy and estrogen can trigger the neoplastic process.<sup>5</sup>

It has also been suggested that estrogen receptor-positive multicystic peritoneal mesotheliomas respond to tamoxifen therapy which makes it mandatory to test this tumor for the presence of estrogen receptors.<sup>5</sup> In the present case, however, the estrogen receptor study was not done. It's also pertinent to note here that the presence of this tumor in male patients precludes the use of tamoxifen.

These tumors grow slowly and progressively in untreated lesions and may recur after surgical resection. Rarely, they may be associated with an adenomatoid tumor which is again a benign mesothelial tumor of unresolved etiopathogenesis, whether neoplastic or hyperplastic. Some authors suggest that BMPM represents borderline lesion between adenomatoid and malignant mesothelioma.<sup>6,7</sup>

Differential diagnosis of this tumor is most commonly with adenocarcinoma, lymphangioma, malignant mesothelioma, well-differentiated papillary mesothelioma, abdominal carcinomatosis in endometriosis, cystic ovarian neoplasm, and pseudomyxoma peritonei. Immunohistochemistry for benign multicystic mesothelioma is calretinin positive and also positive for WT-I, CK 7, and CK 5/6 but negative for CD 31.<sup>12,13</sup> Lymphangiomas occur in younger patients and may contain chylous fluid which is grossly evident in the cut section of the tumor. Histologically they show lymphoid aggregates and smooth muscle within their walls and are CD 31 positive. Cystic teratomas contain adipose tissue and

calcifications.<sup>11,14</sup>

Mesenteric cysts, omental cysts, and pseudocysts are often confused with benign multicystic mesotheliomas. But they are usually unilocular with no distinct cyst wall or internal septa and they are keratin and calretinin negative.

Pseudomyxoma peritoneal (mucinous peritoneal) metastasis may have coexisting omental laking, soft tissue peritoneal nodules, scalloping of serosal margins of the liver or spleen. Loculated ascites has an irregular border and are surrounded by bowel loops or abdominal/ pelvic organs. Malignant mesothelioma is desmin negative but P53 positive, EMA and CEA positive. Peritoneal endometriosis is a condition that produces peritoneal cysts. These cysts are not free-floating and are fibrotic and hemorrhagic and should not be confused with cystic mesotheliomas.<sup>15</sup>

## CONCLUSIONS

In conclusion, BMPM is an oddity that can present as an incidental finding of multiple free-floating peritoneal cysts during routine laparotomy surgery, and should not be a source of concern and perplexity for the operating surgeon as they are benign lesions. When such free-floating peritoneal masses are encountered during laparotomy, they should arouse a suspicion of BMPM and they must be removed and subjected to histopathological examination and immunochemical staining to ascertain their benign nature.

**Conflict of interest:** None

## REFERENCES

1. Safioleas M, Constantinou K, Michael S et al. A Case Report and Review of the Literature. *World J Gastroenterol* 2006;12:5739-42. [Crossref](#)
2. Szollosi A, Ferenc C, Pinter T et al. Benign cystic mesothelioma, a rare tumor of the peritoneum. *MagySeb.* 2005;58:35 - 7. [Website](#)
3. Groisman GM, Kerner H. Multicystic mesothelioma with endometriosis. *Acta ObstetGynecolScand* 1992; 71:642-4. [Crossref](#)
4. Koo PJ, Wills JS, Case 146 : Benign multicystic mesothelioma. *Radiology* 2009;251: 944-6. [Crossref](#)
5. Sawh R.N. Malpica A, Deavers M.T. et al. Benign Cystic mesothelioma of the peritoneum: A Clinicopathologic study of 17 cases and immunohistochemical analysis of estrogen and progesterone receptor status. *Human Pathology*, 2003;34:369 - 74. [Crossref](#)
6. Kurisu Y, Tsuji M, Shibayama Y et al. Multicystic mesothelioma caused by endometriosis: 2 case reports and review of the literature. *Int J Gynecol Pathol.* 2011;30:63-6. [Crossref](#)
7. Akbayir O, Gedikbasi A, Akyol A. Benign cystic mesothelioma: a case series with one case complicated by pregnancy. *J ObstetGynaecol Res*, 2011;37:1126-31. [Crossref](#)
8. Gonzalez-Moreno S, Yan H, Alcorn KW et al. Malignant transformation of Benign cystic mesothelioma of the peritoneum. *J Surgical Oncology* 2002; 79:243-51. [Crossref](#)
9. Tentes A-A, Zorbas G, Pallas N. Multicystic Peritoneal mesothelioma. *The American journal of case reports* 2012;13:262-4. [Crossref](#)
10. Park JY, Kim KW, Kwon H et al. Peritoneal mesotheliomas: Clinicopathological features, CT findings and differential diagnosis. *Am J Roent.*, 2008;191;814-25. [Crossref](#)
11. Somasundaram S, Khajanchi M, Vajas T et al. Benign Multicystic Peritoneal Mesothelioma: A Rare Tumor of the Abdomen. *Case reports in surgery*.2015; Article ID 613148,1-3. [Crossref](#)
12. Cury PM, Butcher DN, Fischer C et al. Value of mesothelium associated antibodies thrombomodulin, cytokeratin, 5/6 calretinin and CD 44 H in distinguishing epithelial pleural mesotheliomas from adenocarcinomas metastatic to pleura. *Mod. Pathol* 2000;13:107-12. [Crossref](#)
13. Daglionic, Dei Tos AP, Laurino L, et al. Calretinin a novel immunohistochemical marker for mesothelioma. *AMJ. Surg Pathol* 1996;1037-46. [Crossref](#)
14. Chua TC, Yan TD, Morris DL. Surgical biology for the clinician: peritoneal mesothelioma: current understanding and management. *Canadian Journal of Surgery*, 2009;52;59- 64. [Website](#)
15. Clement PB. Pathology of endometriosis. *PatholAnnu* 1990;25:245-95. [Website](#)