

## ENDOSCOPIC PICTURES OF CHRONIC INFLAMMATORY DISEASES OF THE NOSE AND PARANASAL SINUSES

Submission Date: October 30, 2023, Accepted Date: November 04, 2023,

Published Date: November 09, 2023

**Djuraev Jamolbek**

Dsc, Associate Professor, Tashkent Medical Academy, Uzbekistan

### ABSTRACT

Rhinosinusitis occurs much more often than it is diagnosed, since in some cases the clinical picture of acute sinusitis is masked by the symptoms of acute viral infections. However, it is believed that sinusitis with influenza and ARVI should be considered not only as their complications, but also as their manifestation. In the development of the inflammatory process in the nasal cavity and paranasal sinuses, in addition to external causes (climatogeographic conditions, level of infectious diseases, environmental conditions, nutritional patterns, stressful situations) that cause disturbances in mucociliary transport, anomalies in the structure of the intranasal structures and the ethmoidal labyrinth can play an important role.

### KEYWORDS

Rhinosinusitis, ARVI, paranasal sinuses.

### INTRODUCTION

Factors that disrupt the patency of the natural openings of the paranasal sinuses and the mechanisms of their aeration and cleansing include anomalies in the development of the nasal turbinates, curvature of the nasal septum and deformation of the nasal valve, the functions of which have not yet been fully studied [2,3,9,12]. This pathological effect creates conditions for blockade of the ostiomeatal complex, and subsequently the development of an inflammatory process in the paranasal sinuses [4,5,9,11]. Under conditions of secretion stagnation and a decrease in

the partial pressure of oxygen in the SNP, favorable conditions are created for the development of bacterial infection [10,11].

Special examination methods, which have been included in the arsenal of otolaryngologists in recent years, allow us to detail the nature of damage to the nasal cavity and paranasal sinuses. [1,5,8,13-17]. This is an instrumental endoscopic study that can be used to objectively assess the degree of nasal breathing impairment [6,7,8,12,18-23].

Endoscopy of the nasal cavity is the most reliable method for studying -the nasal cavity, the condition of the paranasal sinuses and their natural anastomoses and plays a leading role in making a diagnosis, objectively assessing the effectiveness of treatment and choosing the optimal surgical option [ 6,12,24].

Using an endoscope, it is possible to sequentially examine all parts of -the nasal cavity, starting with the vestibule and nasal valve. Pay attention to the color of the mucous membrane, the presence and nature of discharge, evaluate the size of the nasal concha, as well as the condition of the pharyngeal tonsil and the mouths of the auditory tubes [ 7,11,25]. Endoscopy helps to identify nasopharyngeal cysts, as well as confirm the diagnosis of Thornwald's bursa [11].

**The purpose of the study** was to study the role of endoscopic examination in chronic inflammatory diseases of the nose and paranasal sinuses.

## METHODS

We examined 200 patients with chronic inflammatory diseases of the nose and paranasal sinuses. 186 of them were hospitalized at the Republican Specialized Cardiology Center with a diagnosis of myocarditis, which were divided into two groups. The first group consisted of 80 patients with chronic inflammatory diseases of the nose and paranasal sinuses, the second

group consisted of 106 patients without pathology of the nose and paranasal sinuses . All patients were subjected to a comprehensive clinical and laboratory examination, which included taking a medical history, rhinoendoscopy and computed tomography examination. The control group consisted of 20 healthy volunteers from among the employees of the 2nd clinic of the Tashkent Medical Academy. Rhinoendoscopy was performed using an endoscope from Karl Storz (Germany) 0 0 , 30 0 and 70 0 .

## RESULTS & DISCUSSIONS

The main complaints presented by patients were difficulty in nasal breathing (92.5%), nasal discharge (78.4%), impaired sense of smell (22.2%), low-grade fever (36.4%), general weakness ( 42.5%). Patients often noted pain (78.4%) in the maxillary region. CT scans of all patients revealed various combinations of paranasal sinuses involved in the pathological process. In 31 patients, isolated lesions of the maxillary sinuses were found, in 29 – lesions of the maxillary and ethmoidal sinuses, in 14 – lesions of the ethmoidal and frontal sinuses, 6 patients were found to have lesions of the maxillary, ethmoidal and main sinuses . In 45 patients, a curvature of the nasal septum was detected, in 7 - polyps, in 11 - hypertrophy of the ethmoid bulla, in 17 - hypertrophy of the inferior turbinates.

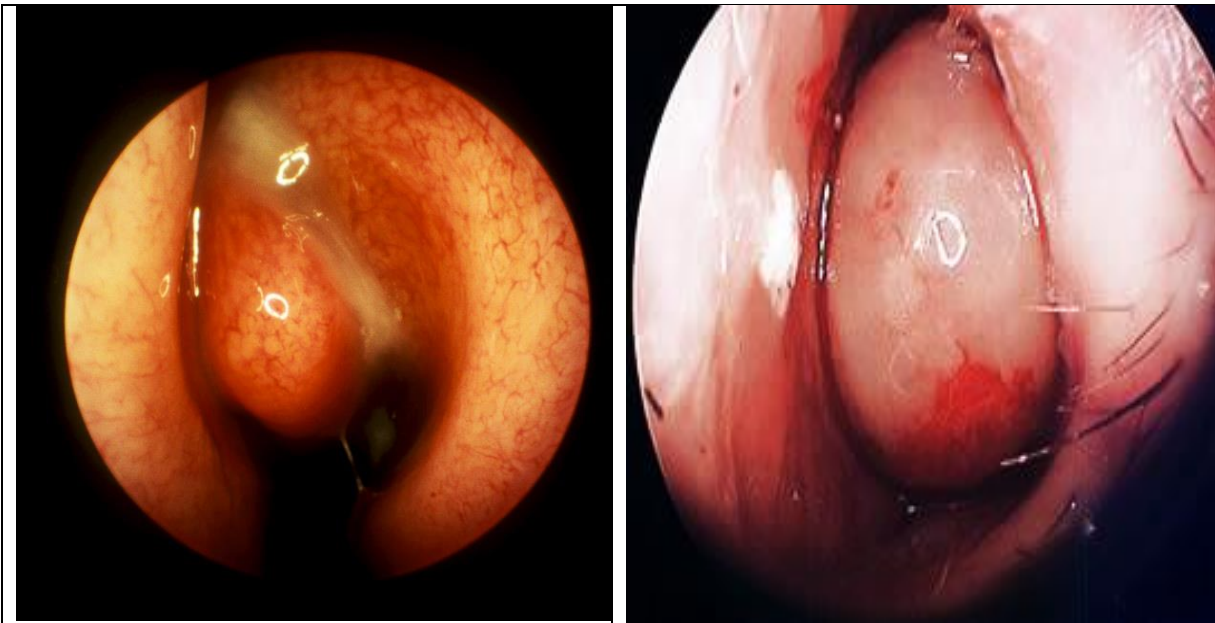


Figure 1. Nasal endoscopy reveals purulent discharge in the left middle meatus

Figure 2. Nasal endoscopy reveals enlargement of the inferior turbinate on the left.

As stated above, an endoscopic examination of the nasal cavity was performed before and after treatment (Figure 1, 2). The results of the endoscopic study showed that all patients had hyperemia and swelling of the nasal mucosa, 62 had pathological discharge in the nose, 45 had a deviated nasal septum, 7 had polyps in the middle meatus, 13 had pathology of the middle turbinate, 5 – hypertrophy of the uncinat process, 18 – hypertrophy of the inferior turbinate, 10 patients – hypertrophy of the ethmoid bulla.

In the postoperative period, all patients were prescribed lavage of the nasal cavity by moving drugs

according to the Proetz method. We included among the medications the most sensitive to this type of infection in the nose. Local application of the drug Nasonex at a dose of 125 mcg in each half of the nose 2 times a day for 7 days. The criteria for the effectiveness of treatment were: positive dynamics in diagnostic endoscopy nasal cavity, as well as analysis of outpatient records and subjective assessment of his condition by the patient himself.

In endoscopic examination, the following scoring system is used to diagnose nasal polyps (Table 1).




Table 1

Character	Basic	3 months	6 months	1 year	2 year
Polyp on the left (0,1,2,3)					
Polyp on the right (0,1,2,3)					
Edema on the left (0,1,2)					
Edema on the right (0,1,2)					
Divisions , left (0,1,2)					
In divisions , right (0,1,2)					
Total points					

During endoscopy , in the absence of nasal polyps, 0 is given; polyps that do not extend beyond the middle turbinate and require endoscopic examination for visualization are given 1; polyps extending beyond the middle turbinate and visible through the nasal planum are given 2; category 3 is given to massive polyps that cover the nasal cavity.

The follow-up period ranged from 6 to 24 months. In none of the cases were there any complications or side effects of local application of Bioparox.

A good result was scored 0-6 points, a satisfactory result - 7-10 points, and an unsatisfactory result - 11-14 points.

The results of treatment determined that a good result, corresponding to 0-6 points, was observed in 160 patients (80%), satisfactory, corresponding to 7-10 points - in 36 (18%), unsatisfactory, corresponding to 11-14 points - 4 patients (2%).

From the total number of patients with difficulty in nasal breathing caused by various etiological factors, we selected patients and performed surgical intervention to eliminate them.

In doing so, we were guided by the severity of myocarditis, the age of the patients, complaints of difficulty in nasal breathing and clinical laboratory data. However, in the presence of serious concomitant

pathology, especially in elderly patients, surgical intervention was initially limited to consultation methods or minimally invasive treatment methods.

Thus, analysis of the data obtained before and after treatment allows us to conclude that the use of endoscopy meets the requirements of modern otorhinolaryngology, is timely and indispensable in the diagnosis and treatment of chronic inflammatory diseases of the nose and paranasal sinuses. The use of endoscopic methods in the treatment of patients with chronic inflammatory diseases of the nose and paranasal sinuses allows us to reduce the number of relapses, which has a beneficial effect on the quality of life of our patients.

## References

1. Khasanov U. S., Juraev Zh. A., Shaumarov A. Z. RESULTS OF ANALYSIS OF FREQUENCY DISTRIBUTION OF POLYMORPHISM RS1800895 592C> A IN THE IL10 GENE AMONG PATIENTS WITH CPRS: dis. – 2023.
2. Khasanov U.S. et al. Bosh va buyinning tugma anomalyalarini davolashda innovation yondosuvlar. – 2022.
3. Rakhimov A. A., Khasanov U. S., Juraev Zh. A. FEATURES OF THE MICROBIOLOGICAL LANDSCAPE OF THE NASAL MUCOSA AFTER SIMULTANEOUS SURGICAL INTERVENTIONS IN THE NASAL CAVITY // Scientific research in higher education: new ideas, problems of implementation, search for solutions. – 2022. – P. 142-144.
4. DZHURAEV Z. A., KHASANOV U. S. SURUNKALI POLIPOSIS RHINOSINUSITIS BILAN KASALLANGANLAR ORASIDA IL4 GENID C589T RS2243250 POLYMORPHISMS TARKALISH FREQUENCY TAGLIL KILISH NATIGHALARI //BIOMEDICINE VA AMA LIET MAGAZINES. – P. 77.
5. Juraev J. \_A. \_ Yuz-jag'sohasinig deformatsiyalarini bartaraf etish lipofiling usuli. – 2022.
6. Khojanov Sh. Kh. et al. Clinical and morphological characteristics of anthrochanal polyps //Uzbek medical journal. – 2020. – T. 6. – No. 1.
7. Khamdamovich K. Y., Juraev Zh. A., Yusupov Sh. – 2022.
8. Khasanov U.S. et al. Birlamchi va revizion rinoplastika. – 2022.
9. Khasanov US, Abdullaev UP, Djuraev JA TURLI GENEZLI OTKIR SENSONEVRAL ASHITISH PASTLIGIDA AUDIOLOGIC TEKSHIRuv NATIZHALARI //Oriental Journal of Medicine and Pharmacology. – 2022. – T. 2. – No. 1. – pp. 24-50.
10. Zulunov BS et al. Surunkali polyposis rhinosinusitis Davolashda geneticist omillarning ahamiyati //Eurasian Journal of Otorhinolaryngology-Head and Neck Surgery. – 2023. – T. 2. – S. 71-75.
11. Khasanov US et al. results analysis frequencies distribution polymorphism rs1800895 592c>a in IL10 gene among sick With CPRS //Eurasian Journal of Otorhinolaryngology-Head and Neck Surgery. – 2023. – T. 2. – S. 104-108.
12. Khasanov US et al. RESULTS OF AUDIOMETRICAL INDICATORS OF COCHLEVESTIBULAR DISORDERS IN PATIENTS WITH ARTERIAL HYPERTENSION DISEASE //Oriental Journal of Medicine and Pharmacology. – 2023. – T. 3. – No. 02. – pp. 26-36.
13. Khasanov US, Abdullaev UP, Djuraev JA RESULTS OF AUDIOLOGICAL EXAMINATION IN ACUTE SENSORINEURAL HEARING LOSS OF VARIOUS GENESIS //Oriental Journal of Medicine and Pharmacology. – 2022. – T. 2. – No. 01. – pp. 24-50.
14. Khasanov US et al. Surunkali polyposis rhinosinusitis Bilan kasallanganlar orasida IL 12b geni a 1188c rs3212227 polymorphisms tarkalish frequency tagolili Natizhalari //Eurasian Journal of

- Otorhinolaryngology-Head and Neck Surgery. – 2023. – T. 2. – S. 109-115.
15. Boymuradov SA et al. KONNING HEMORHEOLOGIST KHUSUSYATLARINI HISOBGA OLGAN HOLDA SW SKELETON SUYAKLARI QYSHMA ZHAROHATLARINI TASHKHISLASH KHUSUSYATLARI //Oriental Journal of Medicine and Pharmacology. – 2022. – T. 2. – No. 1. – pp. 51-63.
16. Khasanov US et al. METHOD FOR THE TREATMENT OF EXUDATIVE OTITIS MEDIA IN CHILDREN //Oriental Journal of Medicine and Pharmacology. – 2022. – T. 2. – No. 01. – pp. 64-81.
17. Khakimov AM, Khodzhaev A.I., Akhundzhanov N.A. State of vestibular function in patients with pre-stroke forms of cerebrovascular disorders against the background of arterial hypertension // Russian Otorhinolaryngology. – 2002. – No. 3. – P. 62.
18. Akhundzhanov N. The state of hearing acuity in patients with hypertension during antihypertensive therapy //Stomatologiya. – 2015. – T. 1. – No. 3 (61). – P. 47-50.
19. Makhsitaliev M. et al. The Functional State Of The Mucous Membrane Of The Nasal Cavity And Paranasal Sinuses After Radical And Minimally Invasive Surgical Interventions //The American Journal of Medical Sciences and Pharmaceutical Research. – 2021. – T. 3. – No. 01. – pp. 31-40.
20. Khasanov US et al. A COMPLEX APPROACH TO THE TREATMENT OF ACUTE SENSONEURAL HEARING LOSS OF DIFFERENT GENES //Oriental Journal of Medicine and Pharmacology. – 2023. – T. 3. – No. 02. – pp. 14-25.
21. Khasanov US et al. VESTIBULAR ANALYZATOR TEST RESULT INDICATORS OF COCHLEOVESTIBULAR DISORDERS ON THE BACKGROUND OF ARTERIAL HYPERTENSION //Oriental Journal of Medicine and Pharmacology. – 2023. – T. 3. – No. 02. – pp. 37-44.
22. Khasanov US, Akhundjanov NA, Djuraev JA DYNAMICS OF HEARING DISORDERS IN PATIENTS WITH ARTERIAL HYPERTENSION UNDER THE INFLUENCE OF HYPOTENSIVE THERAPY //International Journal of Medical Sciences And Clinical Research. – 2022. – T. 2. – No. 10. – pp. 16-20.
23. Khasanov US, Akhundjanov NA, Djuraev JA INFLUENCE OF ANTIHYPERTENSIVE THERAPY ON VESTIBULAR FUNCTION IN PATIENTS WITH ARTERIAL HYPERTENSION //International Scientific and Current Research Conferences. – 2022. – S. 117-119.
24. Djuraev JA, Sh K., Akhundjanov NA A MODERN LOOK AT DIAGNOSTICS AND TREATMENT OF OBSTRUCTIVE APNEA SYNDROME IN SLEEP: dis. – Fan va texnologiyalar nashriyot-matbaa uyi, 2022.
25. Akhundzhanov N. The state of hearing acuity in patients with hypertension during antihypertensive therapy //Stomatologiya. – 2015. – T. 1. – No. 3 (61). – P. 47-50.