


Human Craniovertebral Alignment as a “Tertiary Curvature”



Corresponding Author

Jae Taek Hong

E-mail: jatagi15@gmail.com

 <https://orcid.org/0000-0001-6453-0439>

Department of Neurosurgery, Eunpyeong
St. Mary's Hospital, The Catholic
University of Korea, 1021 Tongil-ro,
Eunpyeong-gu, Seoul 03312, Korea



This is an Open Access article distributed under the terms of the Creative Commons Attribution Non-Commercial License (<http://creativecommons.org/licenses/by-nc/4.0/>) which permits unrestricted non-commercial use, distribution, and reproduction in any medium, provided the original work is properly cited.

Copyright © 2019 by the Korean Spinal Neurosurgery Society

Understanding the normal craniovertebral junction (CVJ) alignment and segmental motion in human is paramount to better understand CVJ deformity and to decide on a more appropriate surgical strategy according to the pathologies of CVJ.

During fetal development, the spine assumes the shape of the letter “C,” with the curved side facing toward the back, while the open side faces the front of the fetus. This C-shaped curve is the primary curve of the spine and is well-suited to the cramped confines of the womb. Newborn infants retain this primary curve and, with growth and maturity, develop secondary curves, first in the neck and later in the lower back. Of the 2 secondary spinal curves, the cervical curve in the neck region develops first. This curve develops in the opposite direction from the primary spinal curvature and allows the infant to have visual access to his surroundings.^{1,2} This secondary cervical curvature is also found in quadrupedal animals as well as in humans. However, there is a significant difference between humans and animals with respect to this curvature: the upper cervical alignment compared to the cranium. It is because the location of the human foramen magnum is quite different from any other kind of animals.

In humans, the foramen magnum is anteriorly positioned and is inferiorly oriented (opening directly downward). Contrastingly, in apes, the foramen magnum is more posteriorly positioned, the foramen magnum in apes is more vertically oriented (opening backwards and downwards, rather than directly downwards).³⁻⁵

Positional difference of the foramen magnum causes a difference of CVJ alignment between humans and other quadrupeds with respect to the C0–1 segment.

When humans are at rest in standing position, the C0–1 articulation is held rather flexibly, whereas the C1–2 joints are held slightly in an extended position. This is because the human cervical spine is located inferior to the foramen magnum, and these characteristics ensure an energy-saving balance of the head and neck when at rest, allowing humans to maintain horizontal vision effectively without significant effort of the neck extensor muscle. However, quadrupeds with posteriorly positioned foramina magna require well-developed nuchal musculature and ligaments to bear the weight of the head to maintain horizontal gaze. Therefore, the demands on the neck musculature differ between humans and quadrupedal mammals (Fig. 1).

Radiographically, the C1 slope is backwardly slanted and kyphotic angulation of the C0–1 segment allows some degree of freedom for neck extension as the space between the occiput and C1 posterior arch allows for upper cervical extension (Fig. 2).

Although asymptomatic population may have different types of cervical alignment, such as “straight” or “kyphotic” cervical spines ranging from 7% to 40% (Fig. 2), it has been well accepted that a large percentage (about 75%–80%) of cervical lordosis is localized to the C1–2 segment, only a small percentage (15%) of cervical lordosis exists in the lower cervi-

cal levels and the C0-1 segment is kyphotic.^{6,7}

When patients have kyphotic deformity in the cervical spine or thoracolumbar spine, C0-1 segment can hold up the head to compensate for distal kyphosis, maintaining the sagittal balance and horizontal gaze (Fig. 3). Therefore, a normal kyphotic angulation of C0-1 segment could be referred to as a “tertiary curvature” to characterize human CVJ alignment, to differentiate between upper cervical spine alignment and primary/secondary curvature of the human spine as well as differentiate between the cervical spine curvature of humans and that of quadrupeds including apes.

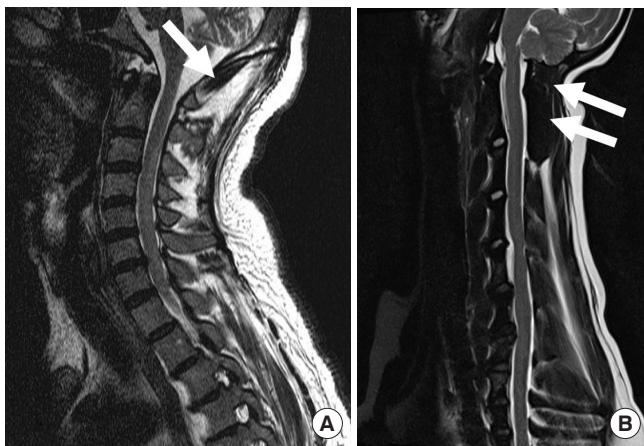

Fig. 1. Magnetic resonance sagittal images show that relative volume of the rectus capitis muscle (white arrows) is quite different between humans (A) and quadrupeds (B).

The loss of subaxial lordosis has been reported in CVJ fixation in which excessive hyperlordosis is created at the C0-2 segment. Moreover, craniometrics studies revealed that an excessive CVJ kyphosis can cause subaxial compensatory lordosis.^{8,9}

The anatomy of the cervicothoracic junction (CTJ) has been shown to be as the main determining factor for cervical lordosis.¹⁰ However, the angle of CVJ has also been shown to significantly be related to the angle of subaxial cervical spine.¹¹ These findings suggest that reciprocal interaction may likely affect not only global balance, but also regional balance.

Another interesting finding is that neck flexion and extension movement are initiated primarily by motions between the head and C1.^{12,13} As the head approaches full flexion and extension, contributions from the upper cervical segments decreases, whereas contribution from the lower cervical segments increases.¹⁴

In addition, our previous studies showed that C0-1 segment is dominant segment for compensatory motion to prevent post-operative dysphagia caused by upper cervical fixation and the C0-1 segmental motion with or without occipital fixation is associated with subaxial kyphotic change after upper cervical fixation.¹⁵⁻¹⁷

So, it is important not to include occipital fixation as much as possible not only to preserve C0-1 segmental motion to prevent postoperative dysphagia but also to avoid abnormal kyphotic alignment of the subaxial cervical spine after surgery.

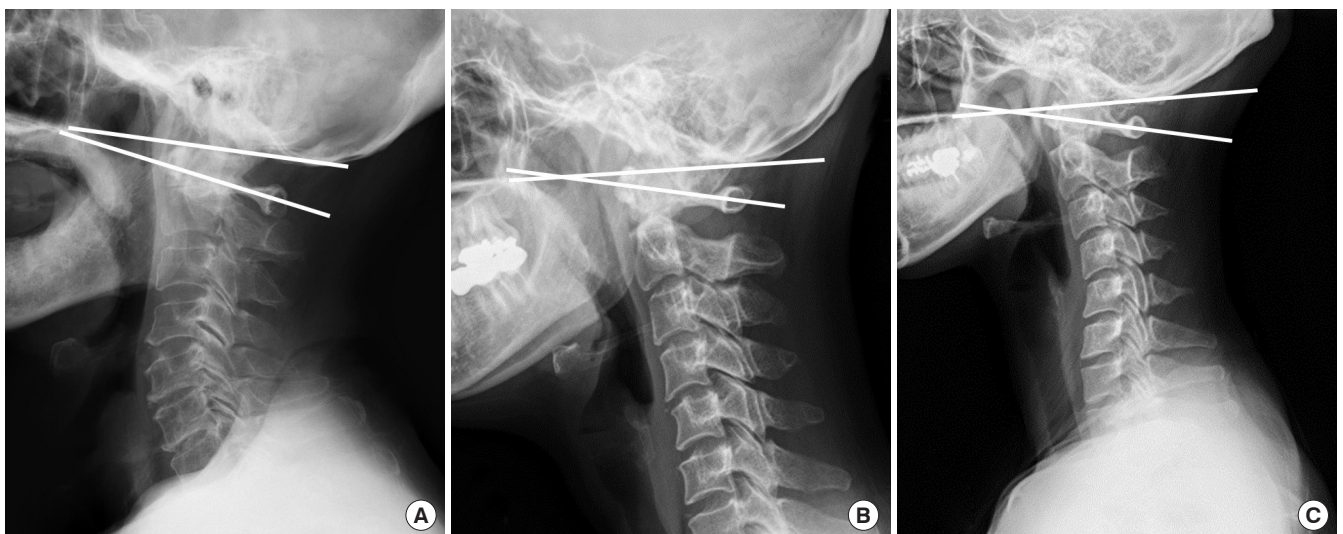


Fig. 2. Lateral X-rays show various alignment of the cervical spine. In most occasions, cervical lordosis occurs at the C1-2 segment. C0-1 segment is kyphotic and C1 slope is always posteriorly slanted not only in lordotic cervical spine (A), but also in straight (B) and kyphotic cervical spine (C).

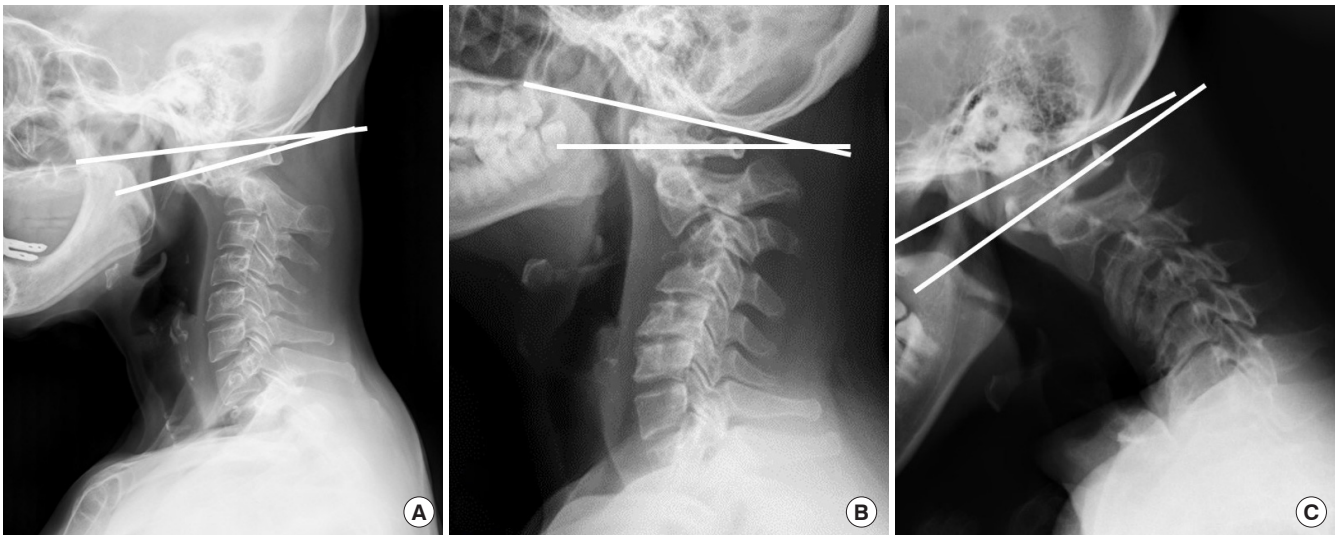


Fig. 3. Lateral X-rays show various kinds of the cervical deformities. Posttraumatic craniovertebral junction (CVJ) deformity patient shows a kyphotic CVJ alignment and hyperlordotic compensation in the C0–1 segment (reversed C1 slope) and subaxial cervical spine (A). C1 slope is reversely slanted and C0–1 segment is hyperlordotic to maintain horizontal gaze even in subaxial cervical kyphotic deformity patients caused by infectious spondylitis (B) and cerebral palsy (C).

CVJ malalignment is a rare and challenging pathology that can result in progressive deformity, myelopathy, severe neck pain, and functional disability, such as difficulty swallowing. The most common causes of CVJ deformity include rheumatoid arthritis, trauma, neoplasm, infection, and congenital bony malformation. This deformity may alter the quality of life because of the neck pain, disabling headache, dysphagia, and myelopathy.

Surgical management of CVJ pathology could be complex for various reasons; given the sensitive relationships involved in the surrounding neurovascular structures and intricate biomechanical issues, access to this region is relatively difficult and there are many risks involved.^{16,18-23}

Recently, there have been tremendous advances in CVJ surgery. However, understanding normal alignment, segmental motion, compensatory reaction and anatomical variation around CVJ is critical not only to decide optimal surgical option but also to prevent complications and improve surgical outcomes.

REFERENCES

1. Been E, Gómez-Olivencia A, Shefi S, et al. Evolution of spinopelvic alignment in hominins. *Anat Rec (Hoboken)* 2017; 300:900-11.
2. Cil A, Yazici M, Uzumcugil A, et al. The evolution of sagittal segmental alignment of the spine during childhood. *Spine (Phila Pa 1976)* 2005;30:93-100.
3. Russo GA, Kirk EC. Foramen magnum position in bipedal mammals. *J Hum Evol* 2013;65:656-70.
4. Richards GD, Jabbour RS. Foramen magnum ontogeny in *Homo sapiens*: a functional matrix perspective. *Anat Rec (Hoboken)* 2011;294:199-216.
5. Penin X, Berge C, Baylac M. Ontogenetic study of the skull in modern humans and the common chimpanzees: neotenic hypothesis reconsidered with a tridimensional Procrustes analysis. *Am J Phys Anthropol* 2002;118:50-62.
6. Abelin-Genevois K, Idjerouidene A, Roussouly P, et al. Cervical spine alignment in the pediatric population: a radiographic normative study of 150 asymptomatic patients. *Eur Spine J* 2014;23:1442-8.
7. Diebo BG, Challier V, Henry JK, et al. Predicting cervical alignment required to maintain horizontal gaze based on global spinal alignment. *Spine (Phila Pa 1976)* 2016;41:1795-800.
8. Passias PG, Wang S, Zhao D, et al. The reversibility of swan neck deformity in chronic atlantoaxial dislocations. *Spine (Phila Pa 1976)* 2013;38:E379-85.
9. Smith JS, Klineberg E, Shaffrey CI, et al. Assessment of surgical treatment strategies for moderate to severe cervical spinal deformity reveals marked variation in approaches, osteotomies, and fusion levels. *World Neurosurg* 2016;91: 228-37.

10. Knott PT, Mardjetko SM, Tschy F. The use of the T1 sagittal angle in predicting overall sagittal balance of the spine. *Spine J* 2010;10:994-8.
11. Kim JT, Lee HJ, Choi DY, et al. Sequential alignment change of the cervical spine after anterior cervical discectomy and fusion in the lower cervical spine. *Eur Spine J* 2016;25:2223-32.
12. Anderst WJ, Donaldson WF 3rd, Lee JY, et al. Continuous cervical spine kinematics during in vivo dynamic flexion-extension. *Spine J* 2014;14:1221-7.
13. Anderst WJ, Donaldson WF 3rd, Lee JY, et al. Cervical motion segment contributions to head motion during flexion\ extension, lateral bending, and axial rotation. *Spine J* 2015; 15:2538-43.
14. Takeshima T, Omokawa S, Takaoka T, et al. Sagittal alignment of cervical flexion and extension: lateral radiographic analysis. *Spine (Phila Pa 1976)* 2002;27:E348-55.
15. Kim JY, Hong JT, Oh JS, et al. Influence of neck postural changes on cervical spine motion and angle during swallowing. *Medicine (Baltimore)* 2017;96:e8566.
16. Yi HJ, Hong JT, Lee JB, et al. Analysis of risk factors for posterior C1 screw-related complication: a retrospective study of 358 posterior C1 screws. *Oper Neurosurg (Hagerstown)* 2019 May 6 [Epub]. pii: opz068. <https://doi.org/10.1093/ons/opz068>.
17. Kim HS, Lee JB, Park JH, et al. Risk factor analysis of post-operative kyphotic change in subaxial cervical alignment after upper cervical fixation. *J Neurosurg Spine* 2019 Apr 26: 1-6 [Epub]. <https://doi.org/10.3171/2019.2.SPINE18982>.
18. Hong JT, Kim IS, Kim JY, et al. Risk factor analysis and decision-making of surgical strategy for V3 segment anomaly: significance of preoperative CT angiography for posterior C1 instrumentation. *Spine J* 2016;16:1055-61.
19. Takigawa T, Simon P, Espinoza Orías AA, et al. Biomechanical comparison of occiput-C1-C2 fixation techniques: C0-C1 transarticular screw and direct occiput condyle screw. *Spine (Phila Pa 1976)* 2012;37:E696-701.
20. Hong JT, Takigawa T, Udayakumar R, et al. Biomechanical effect of the C2 laminar decortication on the stability of C2 intralaminar screw construct and biomechanical comparison of C2 intralaminar screw and C2 pars screw. *Neurosurgery* 2011;69(1 Suppl Operative):ons1-6.
21. Hong JT, Takigawa T, Sugisaki K, et al. Biomechanical and morphometric evaluation of occipital condyle for occipito-cervical segmental fixation. *Neurol Med Chir (Tokyo)* 2011; 51:701-6.
22. Hong JT, Kim TH, Kim IS, et al. The effect of patient age on the internal carotid artery location around the atlas. *J Neurosurg Spine* 2010;12:613-8.
23. Hong JT, Lee SW, Son BC, et al. Analysis of anatomical variations of bone and vascular structures around the posterior atlantal arch using three-dimensional computed tomography angiography. *J Neurosurg Spine* 2008;8:230-6.



Title: Head of a woman (Olga Picasso)

Artist: Pablo Picasso

Year: 1935

Picasso really believed her to be his love forever. The evidence was a marriage settlement where all his paintings were to be divided equally between them. Having settled in Paris, Olga furnished the house in a glamorous and luxurious manner, in the high of fashion. They had a car with a driver, an art studio that occupied the entire second floor, highbred dogs; they threw receptions, dinner parties and social functions. Olga liked expensive clothes, caviar and champagne. Pablo also was not averse to ordering a suit at a high-end couturier. He had golden watch in a vest pocket. He was proud of his wife, of her manner to behave in a high society, of her unconventional beauty and fine demeanor, and humored her in her wish to live in grand style.

More information: <https://www.pablo-ruiz-picasso.net/theme-olga.php>

© 2019 - Succession Pablo Picasso - SACK (Korea)