

# Effect of Topical 5-Fluorouracil Alone versus Its Combination with Erbium:YAG (2940 nm) Laser in Treatment of Vitiligo


This article was published in the following Dove Press journal:  
*Clinical, Cosmetic and Investigational Dermatology*

Mahetab Abdelwahab<sup>1</sup>  
Manal Salah<sup>2</sup>  
Nevien Samy<sup>2</sup>  
Ahmad Rabie<sup>1</sup>  
Abdelrazik Farrag<sup>3</sup>

<sup>1</sup>Department of Dermatology and Venereology, Medical Division, National Research Centre, Cairo, Egypt;

<sup>2</sup>Department of Medical Applications of Lasers (MAL), National Institute of Laser Enhanced Sciences, Cairo University, Giza, Egypt; <sup>3</sup>Department of Pathology, Medical Division, National Research Centre, Cairo, Egypt

→ Video abstract



Point your SmartPhone at the code above. If you have a QR code reader the video abstract will appear. Or use:  
<https://youtu.be/RNPmAGPkfGo>

**Purpose:** To compare the efficacy of topical 5-FU as monotherapy to combined therapy of topical 5-FU and Er:YAG (2940 nm) laser in the treatment of non-segmental vitiligo (NSV).

**Methods:** This is a prospective randomized comparative study. Thirty patients diagnosed with NSV were recruited from the dermatology outpatient clinics of the Medical Research Centre of Excellence, the National Research Centre and the National Institute of Laser Enhanced Sciences. Our study group was divided into two subgroups, Group 1 was subjected to ablative Er:YAG and 5-FU cream and Group 2 applied topical 5-FU cream. Three treatment sessions were repeated every 4 to 6 weeks and patients were followed up to 9 months. Repigmentation was assessed by digital photography and subsequent computer based image analysis.

**Results:** Repigmentation of Group 1 patients ranged from 0 to 70% (mean 12±7%) whilst in Group 2 this ranged from 0 to 5% (mean 1.4±0.8%). In Group 1 repigmentation was mild in 22/30 (73.3%) and moderate to severe in 3/30 (10%) starting after 3 months and persisted or increased during the period of follow up to 9 months. Groups 1 and 2 were subdivided into A and B, vitiligo involving non-resistant and resistant areas respectively. Group 1A showed more repigmentation (mean 13.8±8.5%) than Group 1B (mean 9.8±4.5%) and Group 2A showed more repigmentation (mean 1.5±1%) than Group 2B (mean 1.3±0.5%).

**Conclusion:** The combination of Er:YAG with 5-FU is safe and effective in treating and improving outcome in vitiligo especially of non-resistant areas. Computer based image analysis of vitiliginous lesions and assessing post-therapy response is an easy, quick, and reliable method.

**Keywords:** 5-fluorouracil, ablative, Er:YAG, vitiligo, image analysis, resistant

## Introduction

Vitiligo is an acquired disease with a variable course. It is considered the most common depigmentation disorder affecting approximately 0.5 to 2% of the population.<sup>1</sup> Vitiligo continues to be a major dermatologic challenge in spite of the availability of many therapeutic modalities.<sup>2</sup> No single therapy for vitiligo leads to satisfactory results in all patients but the combination of surgical modalities and medical treatment might lead to faster improvement and better pigmentation.<sup>3</sup> Amongst these new promising treatment modalities is 5-fluorouracil (5-FU), which can improve vitiliginous lesions and decrease treatment duration with better patient compliance.<sup>4</sup> It was postulated that 5-FU could exert repigmentation in vitiligo by direct stimulation of melanocytes and an increase in the number of melanosomes in the keratinocytes.<sup>5</sup> Several studies applied 5-FU after mechanical dermabrasion to vitiliginous lesions with successful results.<sup>6,7</sup> Erbium-YAG (Er:YAG) is considered superior to ordinary dermabrasion because of its

Correspondence: Mahetab Abdelwahab  
Tel +20 101 465 7840  
Email mahysmr@gmail.com

optimum bleeding effect at recipient ablated sites, and precise ablation of the epidermis. Its use as a method of delivery of 5-FU achieved 50 to 75% repigmentation in 33.3% of Egyptian vitiligo patients followed for 15 months.<sup>8</sup>

So, the aim of our study is to compare the efficacy of topical 5-FU as monotherapy to combined therapy of topical 5-FU and Er:YAG laser in the treatment of non-segmental vitiligo (NSV) in a cohort of Egyptian patients.

## Patients and Methods

### Ethics

The study was approved by the Dermatology Department ethical committee, National Research Centre (NRC). Patients gave their written informed consent to participate in the study, and to be photographed. The nature of the treatment including potential benefits, risks, and side effects was explained to each patient.

### Patients

Thirty patients diagnosed with non-segmental vitiligo were recruited from the Dermatology outpatient clinics of the Medical Research Centre of Excellence (MRCE), the National Research Centre (NRC) and the National Institute of Laser Enhanced Sciences (NILES).

Patients included both genders, aged  $\geq 18$  years, Fitzpatrick skin types II to IV. Patients were enrolled in the study if they had stable (showing no progression of old lesions and/or development of new lesions, as well as absence of Koebner phenomenon) multiple vitiliginous lesions 1 year before enrolment in the study. Inclusion criteria also included the patient not receiving systemic and/or topical treatment for the vitiliginous lesions 3 months and 2 weeks before enrolment in the study respectively.

Patients were excluded if they had co-morbidities as other autoimmune disorders, hepatic or renal dysfunction, bleeding disorders, were receiving aspirin for a medical cause, had burns, Koebner's phenomenon/Keloid at the site of the vitiliginous area, and were pregnant and/or lactating women.

The vitiliginous site(s) chosen to conduct the study were randomly selected.

### Methods

This a prospective randomized comparative study. All patients were subjected to thorough history taking including family history and clinical assessment. Lesions were divided into two groups according to the treatment received. Each patient was subjected to ablative Er:YAG and 5-FU cream at

one vitiliginous lesion (Group 1) and topical 5-FU cream was applied to a different vitiliginous lesion (Group 2) as comparative arms of the study.

## Group 1 Procedure

The affected skin area was sterilized with Betadine antiseptic solution and then lidocaine hydrochloride (Pridocaine) cream was applied for 30 to 45 mins for local anaesthesia under occlusion.

The laser used was Er:YAG 2940 nm (Fotona Medical Lasers) with a surgical handpiece of spot size 4 mm and a fluence of 60 J/cm<sup>2</sup> and 2–3 passes with pinpoint bleeding as an endpoint. After each pass, skin was rehydrated with moist saline-soaked gauzes. Tissue debris was removed with gentle rubbing and wiping the treated area using dry gauze. Fluorouracil cream (5-FU) was then added once daily for 2 weeks under occlusion. Topical antibiotic (fusidic acid 2% cream) covered by gauze was applied for another 2 weeks. Patients conducted 3 treatment sessions, a session was every 4 to 6 weeks and they were followed up to 9 months to assess the response.

## Clinical Assessment

Patients were assessed initially at the first visit before starting therapy clinically and lesions were documented by photography. Patients were evaluated thereafter 3 and 6 months after their third session to assess their response to therapy using digital photography with subsequent computer based image analysis. Patients underwent liver function tests [serum glutamic-oxaloacetic transaminase (SGOT), serum glutamic pyruvic transaminase (SGPT), bilirubin] and complete blood picture before enrolment in the study and at the start of each session to detect any laboratory side effects of 5-FU. Patients were assessed for local side effects as erythema, post-inflammatory hyperpigmentation, pain, and itching during the follow-up visits and at the end of the study.

## Group 2

5-FU cream was applied as a monotherapy once daily for 2 weeks to another vitiliginous lesion in the same patient. Both sites in the same patient were compared.

## Assessment of Response to Therapy

### Digital Photography

This was conducted using a Sony digital camera with standardized distance and lighting conditions (magnification  $\times 1$  at

a distance of 20 and 30 cm). A set of standardized photographs was taken initially and at 3 and 6 months after the third session of treatment focusing on the lesion and documenting any changes, whether repigmentation and/or erythema, crust formation, oozing, and post-inflammatory hyperpigmentation. Photographs were obtained using identical camera settings, lighting, background, and patient positioning to ensure the consistency of images. The images were stored in a file format of JPG.

### Image Analysis (Morphometric Measurement)

The photographs were sent for computerized digital image analysis. Morphometric measurements were done using a Leica Quin500 Image Analyzer (LEICA Imaging Systems Ltd, Cambridge, London), Pathology Department, National Research Centre, Cairo. The area of lesions was measured in  $\mu\text{m}^2$  at baseline and then compared with the area after treatment to assess if they varied and the degree of repigmentation was calculated as a percentage. The data were copied to Excel sheets and statistically analyzed.

Repigmentation response was divided according to Njoo et al. into mild (<25%), moderate (26–75%), and marked (>75%).<sup>9</sup> Patients' response to therapy was divided according to the site into response of flat/non-resistant/hairy areas and non-flat/resistant/non-hairy areas and both were compared.

### Histopathological Assessment Technique

Punch biopsies of 4 mm in size were taken from the lesion sites at baseline, and post therapy. Samples were then fixed in 10% saline for 24 hrs. Afterwards, samples were washed in tap water, dehydrated in ascending grades of ethanol, cleaned in xylene, and embedded in paraffin wax (melting point 55–60°C). Sections of 6  $\mu\text{m}$  thickness were stained with haematoxylin and eosin (H & E, Drury and Wallington, 1980) showing the cytoplasm as shades of pink and red with blue nuclei. In both arms of the study, Group 1 (conducted ablative ER:YAG followed by 5-FU cream) and Group 2 (applied topical 5-FU cream), prominent melanin pigmentation and expression of HMB45 (Human Melanoma Black 45) were assessed. The sections were examined under light microscope (Leica Q500iW, Leica DMLB) photomicroscope with position captors, and CDD video camera module N50 (JVC TK-C1380). Images were captured with 100 $\times$  and 400 $\times$  magnification.

## Results

Thirty patients with non-segmental vitiligo (NSV) not responding to treatment with topical and/or oral

corticosteroids, tacrolimus, phototherapy, and psoralen plus ultraviolet A light were enrolled in this study. Our studied cohort included 12 (40%) males and 18 (60%) females. Their age ranged from 15 to 59 years (mean 34.7  $\pm$  12.6 years). The disease duration ranged from 2 to 33 (mean 12.6 $\pm$ 8.2) years.

The skin type, family history of autoimmune disease, previously received treatment, and type of NSV of 30 patients diagnosed with vitiligo is shown in Table 1.

### Repigmentation Assessed by Image Analysis

We divided our patient cohort diagnosed with NSV into 2 subgroups according to the site involved with vitiliginous

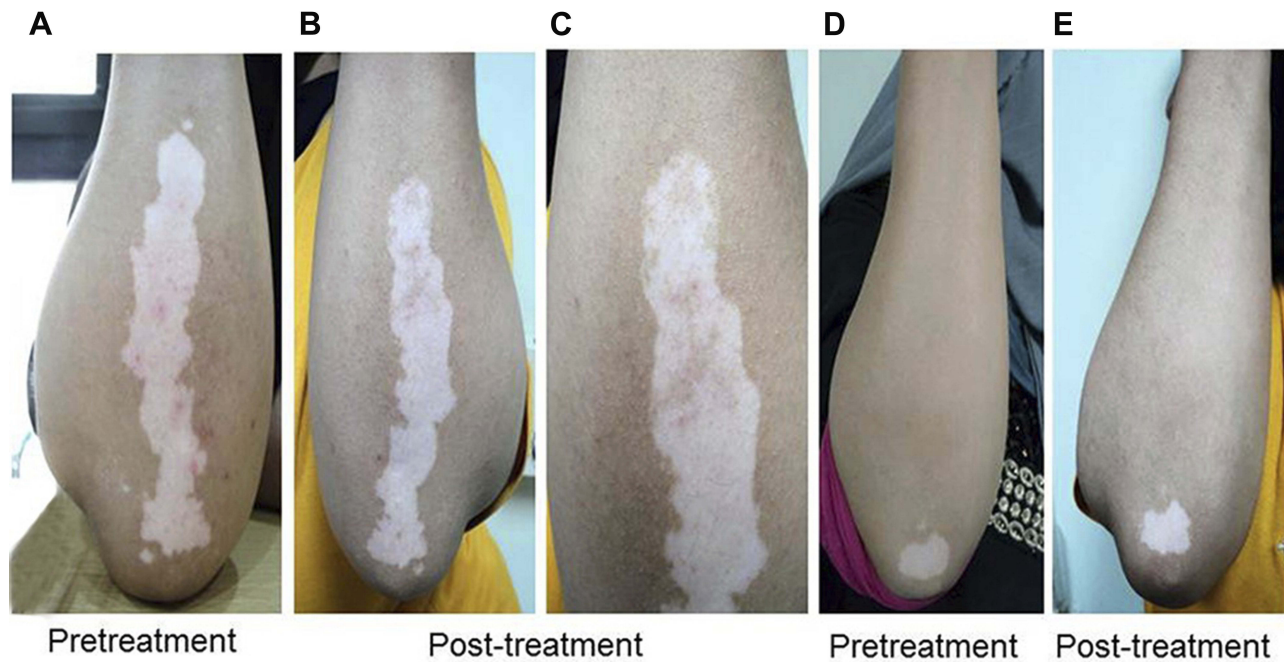
**Table 1** Skin Type, Family History of Autoimmune Disease, Previously Received Treatment, and Type of NSV of Our Studied Cohort (N=30)

Item	Description	Number	Percentage
Skin Type	III	14	46.7%
	IV	16	53.3%
Family history of autoimmune disease	Yes	19	63.3%
	No	11	36.7%
Treatment received – Steroid	Yes	23	76.7%
	No	7	23.3%
Tacrolimus	Yes	12	40.0%
	No	18	60.0%
Ezaline	Yes	16	53.3%
	No	14	46.7%
NB-UVB	Yes	17	56.7%
	No	13	43.3%
Type of vitiligo	Acrofacial/acral	2	6.7%
	Universalis	1	3.3%
	Vulgaris	27	90.0%

**Abbreviation:** NB-UVB, narrow band ultraviolet radiation B.

**Table 2** Repigmentation of Group 1 (Received Er:YAG Followed by 5-FU Cream) Patients and Group 2 (received 5-FU cream) patients and Subgroups A (Flat) and B (Non-flat)

Repigmentation	Group 1	Group 2
Range	0–70%	0–5%
Mean $\pm$ SD	12 $\pm$ 7%	1.4 $\pm$ 0.8%
Subgroups (Mean $\pm$ SD)		
A Flat, n=16	13.8 $\pm$ 8.5%	1.5 $\pm$ 1%
B Non-flat, n=14	9.8 $\pm$ 4.5%	1.3 $\pm$ 0.5%



**Figure 1** A 35 year old female with NSV of the left forearm before treatment (A); and after treatment with Er:YAG laser and 5-FU cream (B); and showing repigmentation (C). Right forearm of the same patient before treatment (D); and after treatment with 5-FU cream (E).

lesions and/or its response to therapy (repigmentation); vitiligo involving flat (F)/non-resistant/hairy areas, not involving joints (Group A, n=16), and vitiligo involving non-flat (NF)/resistant/non-hairy areas, those involving and/or surrounding joints (Group B, n=14). Group A included patients with vitiligo involving the nape of the neck (n=2, 12.5%), the hands (n=3, 18.8%), the axilla (n=1, 6.3%), the trunk (n=3, 18.8%), the forearm (n=2, 12.5%), the lower limbs (n=4, 25%), and the back (n=1, 6.3%). Group B included patients with vitiligo involving the wrists (n=3, 21.4%), the elbows (n=7, 50%), the knuckles (n=1, 7.1%), and the knees (n=3, 21.4%). In females vitiligo is usually vulgaris (94.4%) and involving resistant areas, 10/14 (71.4%) are Group B patients.

The repigmentation of Group 1 (received Er:YAG followed by 5-FU cream) patients and Group 2 (received 5-FU cream) patients as well as subgroups A (vitiligo involving flat (F)/non-resistant/hairy areas, not involving joints) and B (vitiligo involving non-flat (NF)/resistant/non-hairy areas, those involving and/or surrounding joints) is shown in Table 2.

In Group 1 patients, repigmentation was mild in 22/30 (73.3%) and moderate/severe in 3/30 (10%). The repigmentation started after 3 months and persisted/increased during the period of follow up of 9 months. It is important to note that amongst flat areas, the nape of the neck and the abdomen showed the most significant improvement.

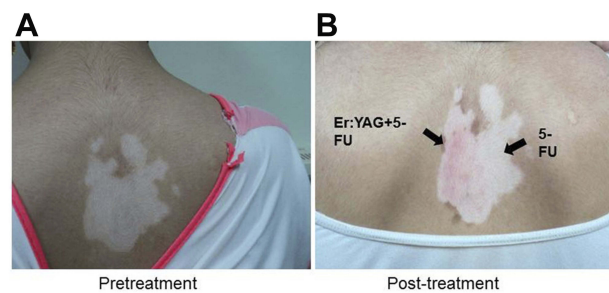
Figures 1 and 2 show repigmentation of the forearm and nape of the neck in a 35 and an 18 year old patient with NSV, respectively.

Repigmentation is usually at the periphery and perifollicular, and then moves to the centre.

#### Histopathological Results Before and After Therapy

Histopathological examination of vitiliginous sections stained with H

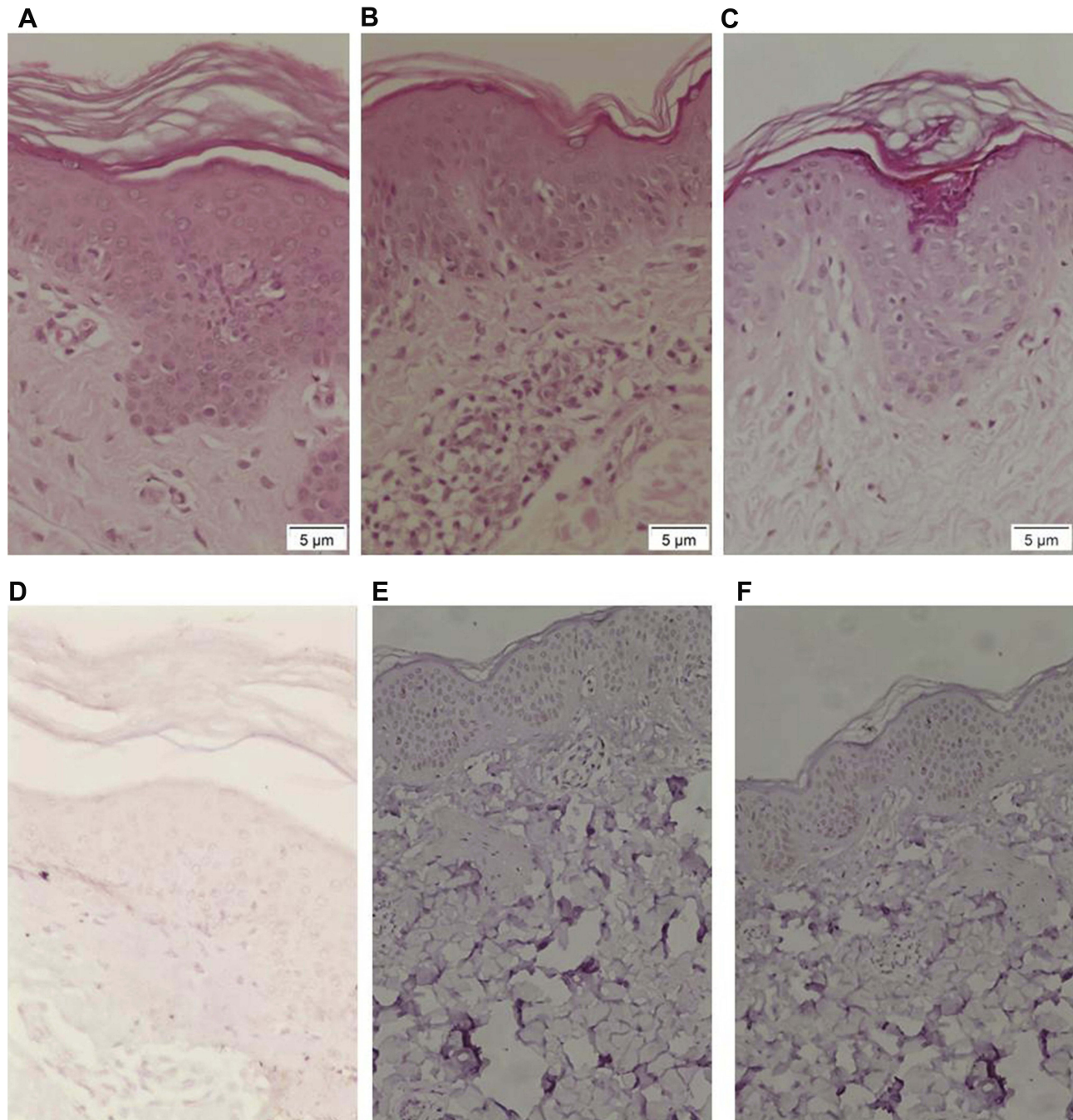
& E before treatment showed a complete absence of melanin pigmentation. The dermis revealed a decreased number of adnexal structures and mild predominantly lymphocytic inflammatory infiltrate. Apoptotic melanocytes and single mononuclear cells in the papillary dermis



**Figure 2** An 18 year old female with NSV of the nape of the neck before treatment (A). (B) Same patient after treatment, right half with Er:YAG laser and 5-FU cream while left half treated with 5-FU only.

moving towards the epidermis were also found (Figures 3A, 4A). After treatment with combined therapy of Er:YAG followed by 5-FU cream (Group 1) or 5-FU monotherapy (Group 2), examination of histopathological sections showed significant improvement, repigmentation in

the form of the presence of melanocytes in the basal layer of epidermis and reduction of mononuclear cells in the papillary dermis. Improvement was more pronounced on using combined therapy (Figures 3C, 4B) as opposed to monotherapy with 5-FU (Figures 3B, 4C).



**Figure 3** An 18 year old female with NSV of the nape of the neck (A) before treatment showing apoptotic melanocyte, single mononuclear cells in the papillary dermis moving towards the epidermis (H & E stain, scale bar = 5  $\mu$ m). (B) After treatment with 5-FU cream alone showing marked hyperkeratosis, elastosis, and apoptotic melanocyte in the basal area of epidermis. Mononuclear cells in the papillary dermis are found either in clumps or as single cells moving towards the epidermis (H & E stain, scale bar = 5  $\mu$ m). (C) After treatment with 5-FU cream and Er:YAG showing a huge number of melanocytes in the basal layer of the epidermis. Mononuclear cells in the dermis are found in clumps (H & E stain, scale bar = 5  $\mu$ m). (D) Before treatment weak melanin expression of HMB45 (HMB45 stain). (E) After treatment with 5-FU cream alone showing mild expression of HMB45. In some areas no expression was found (HMB45 stain). (F) After treatment with 5-FU and Er:YAG showing marked expression of HMB45. In some areas no expression was found (HMB45 stain).

### Immunohistochemistry (HMB45)

Immunohistochemical study of vitiliginous sections before treatment showed negative expression of HMB45 (Figures 3D, 4D). After applying 5-FU monotherapy to the vitiliginous lesion there was mild expression of HMB45 (Figures 3E, 4F) whilst the vitiliginous lesions showed marked expression of HMB45 when using combined therapy of Er:YAG followed by 5-FU cream (Figures 3F, 4E).

### Side Effects of Treatment Received and Procedure Conducted

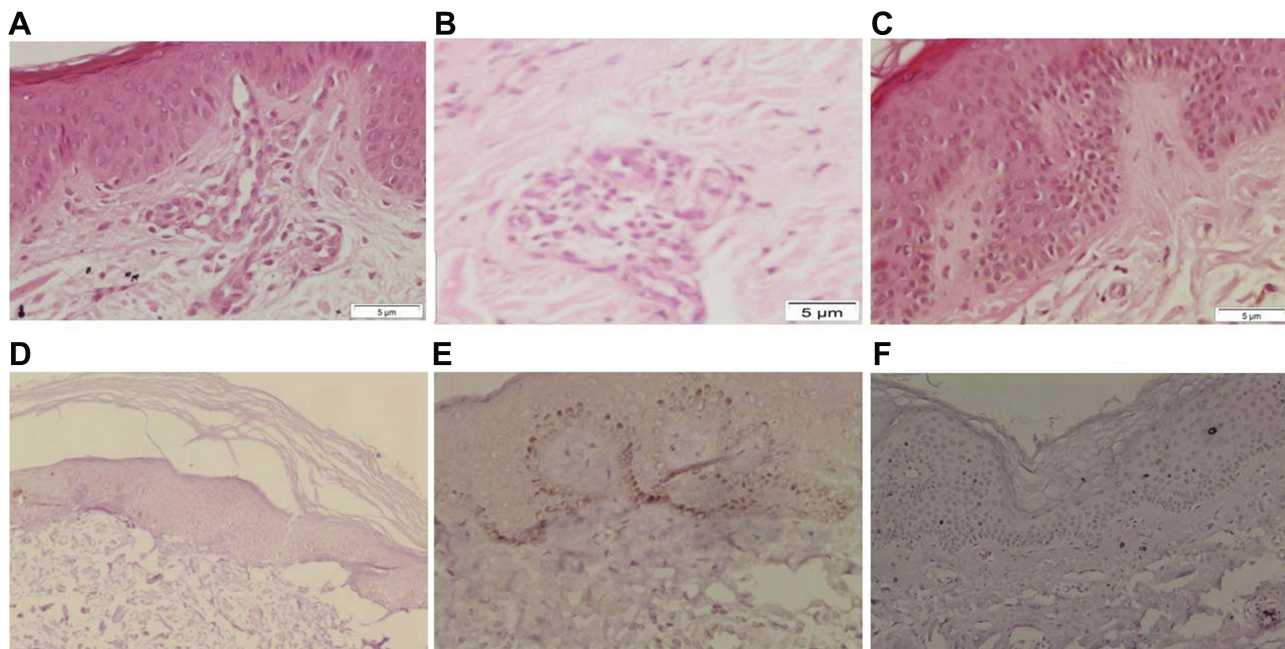
All patients complained of pain at the sites of application of 5-FU; itching, and burning pain from laser application. The burning pain of laser and 5-FU was significant enough that a few patients wanted to discontinue treatment. Post-inflammatory hyperpigmentation was also noted after the procedure.

However, none of our patients experienced any systemic side effects. Their serum SGOT, SGPT, BUN, CBC, bilirubin, and urine analyses were normal throughout the study.

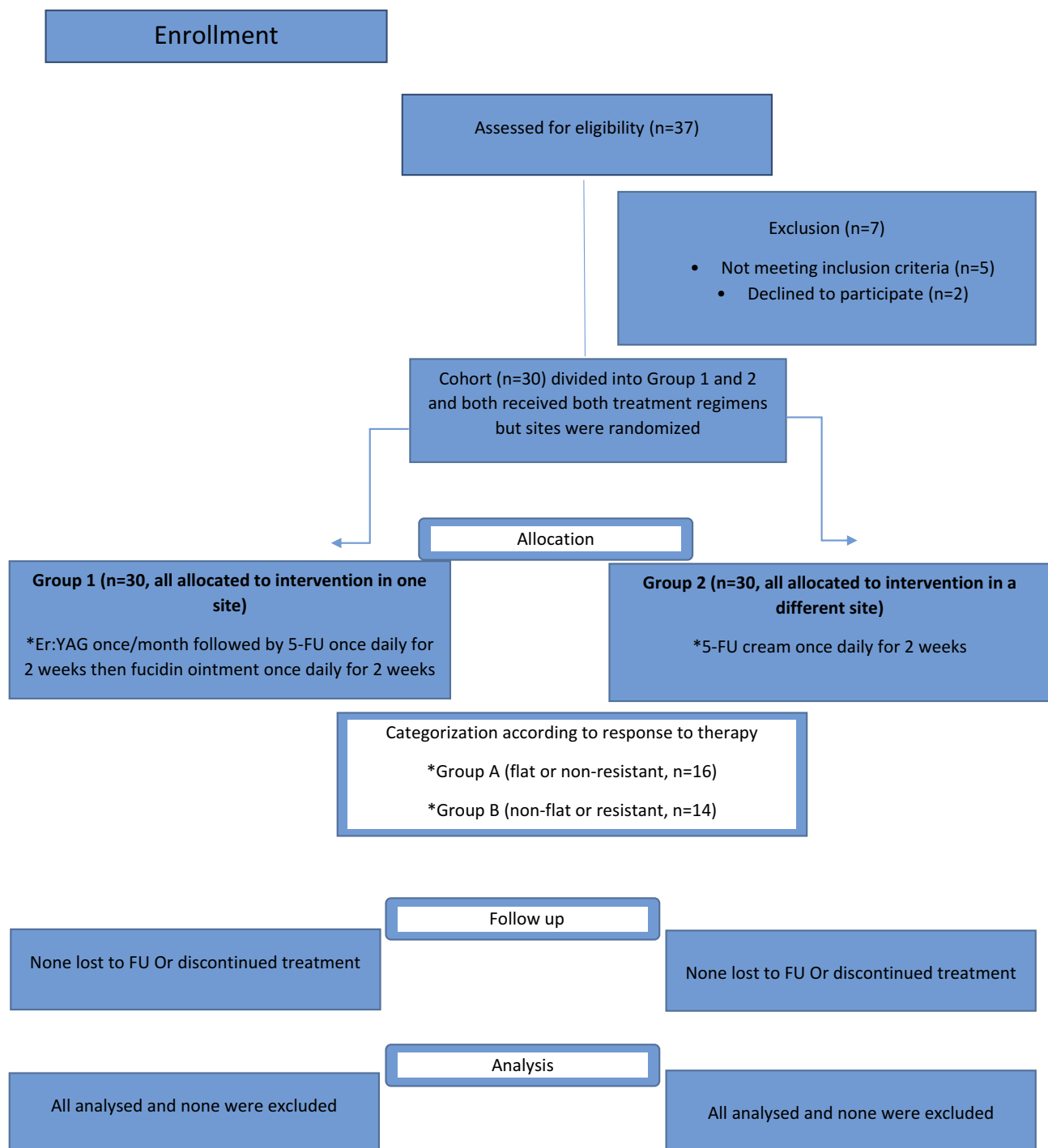
A consort flow chart of the clinical study is shown in Figure 5.

### Discussion

Treatment of vitiligo has undergone an evolutionary change in the past era. However, there is no single effective treatment modality, hence our study applying Er:YAG laser resurfacing followed by 5-FU cream to patients with NSV. This led to repigmentation in up to 70% (mean  $12\pm 7\%$ ) as compared to repigmentation in up to 5% (mean  $1.4\pm 0.8\%$ ) in monotherapy with 5-FU cream. So our results confirm the role of Er:YAG as a mode of transepidermal drug delivery. This agrees with other studies conducted on Egyptian patients and achieving 50 to 75% repigmentation when combining CO<sub>2</sub> laser and 5-FU or Er:YAG and 5-FU,<sup>8,10</sup> respectively. In our studied cohort, Group 1 patients (received Er:YAG followed by 5-FU cream) showed mild (<25%) repigmentation in 73.3% and moderate (50–75%) repigmentation in 10%. However, other studies showed 75% repigmentation in 49.8% of their vitiliginous lesions that were treated with CO<sub>2</sub> laser followed by 5-FU and 50 to 75% repigmentation in 33.3% and 66.7% of their studied cohorts that received combined therapy of Er:YAG plus 5-FU, and Er:YAG 5-FU followed by short term narrow band ultraviolet B, respectively.<sup>4,8,10</sup> The higher percentage of repigmentation in these studies can be attributed to several



**Figure 4** A 35 year old female patient with NSV of the forearm before treatment (A). There is an absence of melanocytes and melanin in the basal cell layer. The dermis reveals mild predominantly lymphocytic inflammatory infiltrate (H & E stain, scale bar = 5  $\mu$ m). (B) After treatment with 5-FU and Er:YAG showing a large number of the melanocytes in the basal layer of the epidermis. Mononuclear cells in the dermis are found in clumps (H & E stain, scale bar = 5  $\mu$ m). (C) After treatment with 5-FU cream alone showing a small number of melanocytes in the basal layer of epidermis. Mononuclear cells in the dermis found as single cells moving towards the epidermis (H & E stain, scale bar = 5  $\mu$ m). (D) Before treatment showing weak expression of HMB45 (HMB45 stain). (E) After treatment with 5-FU and Er:YAG showing marked expression of HMB45 (HMB45 stain). (F) After treatment with 5-FU cream alone showing mild expression of HMB45 (HMB45 stain).



**Figure 5** Consort flow chart of clinical study Group 1 and Group 2.

factors; the number of laser sessions, pulses, or the use of a third line of therapy as narrow band ultraviolet B (NB-UVB) in the study by Anbar et al.<sup>4</sup> Repigmentation in our cohort started after 3 months and persisted and/or increased during the period of follow up that lasted up to 9 months in some patients. The pattern of repigmentation was perifollicular starting from the margins and spreading centripetally which

agrees with other studies.<sup>10,11</sup> After epidermal abrasion 5-FU is absorbed easily, penetrates deeply, and stimulates the amelanotic (inactive) melanocytes present at the outer root sheath of the lower portion of the hair follicle which proliferate and migrate upward and start to actively synthesize melanin at the infundibulum and from there they migrate upward until they reach the surface of the skin. This appears clinically as

perifollicular pigmentation which gradually enlarges to cover the whole depigmented area.<sup>12</sup>

In our study, flat, non-resistant hairy areas showed more repigmentation (mean 13.8±8.5%) as compared to non-flat, resistant, non-hairy areas (mean 9.8±4.5%). This is contrary to Mina et al,<sup>13</sup> who reported that 40% of acral vitiliginous patches showed good to excellent repigmentation mainly diffuse but the pattern was perifollicular as shown in our study.

5-FU has antimetabolic activity, so it is surprising that it would be implicated in the vitiligo repigmentation process which obviously needs melanocyte proliferation. Successively, it was postulated that direct overstimulation of melanocyte proliferation increases the number of melanosomes in the keratinocytes. Moreover, inhibition of agents or cells able to destroy pigment cells, and finally immunomodulation stabilizing the vitiliginous lesions, may stimulate the reservoir of the follicular melanocytes or the persistent DOPA-negative melanocytes in the depigmented epidermis.<sup>5</sup>

All our patients complained of pain at the site of application of 5-FU but we reported post-inflammatory hyperpigmentation in only 6.6% whereas none reported systemic side effects. In the study by Anbar et al,<sup>4</sup> the authors reported pain in all their patients, and a higher prevalence of hyperpigmentation in 30%. Interestingly in the study using microneedling with 5-FU,<sup>13</sup> although they reported the procedure to be well tolerated, patients developed hyperpigmentation in 16%, inflammation in 12%, and ulceration in 4% of patients, all more severe side effects than what is reported in our study.

Our studied cohort was assessed by digital photography on enrolment and follow up which is a simple, practical, and accurate way of assessing patients and documenting their response to therapy. Moreover, assessment of vitiliginous lesions by image analysis in our study has shown to be a reliable, easy, and quick method in evaluating treatment response in patients with NSV. The image analysis also detected improvement with therapeutic intervention and was able to measure marginal and perifollicular repigmentation which is in agreement with other studies.<sup>14,15</sup>

## Conclusion

The combination of ablative Er:YAG with 5-fluorouracil is safe and effective in treating and improving outcome in vitiligo with flat, hairy areas showing more repigmentation as compared to non-flat, non-hairy, resistant areas. Computer based image analysis of vitiliginous lesions and assessing post-therapy response is an easy, quick, and reliable method.

We followed our patients for 9 months, a reasonable period as compared to other studies, yet we recommend a longer follow up period due to the nature of the disease affected by many factors. The longer follow up period together with a larger sample size will assess the long term efficacy, possible side effects of 5-fluorouracil, as well as its underlying mechanism of action. More sophisticated methods of image analysis with automated scores can be designed for easy accurate calculation of depigmentation and repigmentation in vitiligo and comparing different treatment modalities. Also a pain scoring system can be an objective method to assess the magnitude and tolerability of pain.

## Acknowledgment

Special thanks to all the patients who participated in the study.

## Disclosure

The authors report no conflicts of interest in this work.

## References

- Ezzedine K, Lim HW, Suzuki T, et al. Revised classification/nomenclature of vitiligo and related issues: the vitiligo global issues consensus conference. *Pigment Cell Melanoma Res.* 2012;25(3):E1–E13.
- Bacigalupi RM, Postolova AM, Davis RS. Evidence -based, non-surgical treatments for vitiligo: a review. *Am J Clin Dermatol.* 2012;13(4):217–237. doi:10.2165/11630540-000000000-00000
- Garg T, Chander R, Jain A. Combination of Microdermabrasion and 5-fluorouracil to induce repigmentation in vitiligo: an observational study. *Dermatol Surg.* 2011;37(12):1763–1766. doi:10.1111/j.1524-4725.2011.02127.x
- Anbar T, Westerhof W, Abdel-Rahman A, et al. Effect of one session of ER: YAG laser ablation plus topical 5-fluorouracil on the outcome of short-term NB-UVB phototherapy in the treatment of non-segmental vitiligo: a left-right comparative study. *Photodermatol Photoimmunol Photomed.* 2008;24(6):322–329. doi:10.1111/j.1600-0781.2008.00385.x
- Gauthier Y, Anbar T, Lepreux S, et al. Possible mechanisms by which topical 5-fluorouracil and dermabrasion could induce pigment spread in vitiligo skin: an experimental study. *ISRN Dermatol.* 2013;8:49–52.
- Tsuji T, Hamada T. Topically administered fluorouracil in vitiligo. *Arch Dermatol.* 1983;119(9):722–727. doi:10.1001/archderm.1983.01650330014006
- Sethi S, Mahajan B, Gupta R, et al. Comparative evaluation of the therapeutic efficacy of dermabrasion, dermabrasion combined with topical 5% 5-fluorouracil cream, and dermabrasion combined with topical placentex gel in localized stable vitiligo. *Int J Dermatol.* 2007;46(8):875–879. doi:10.1111/j.1365-4632.2007.03226.x
- Anbar T, Westerhof W, Abdel-Rahman A, et al. Treatment of peri-ungual vitiligo with erbium-YAG-laser plus 5-fluorouracil: a left to right comparative study. *J Cosmet Dermatol.* 2006;5(2):135–139. doi:10.1111/j.1473-2165.2006.00240.x
- Nojoo MD, Bos JD, Westerhof W. Treatment of generalized vitiligo in children with narrow-band(TL- 01) UVB radiation therapy. *J Am Acad Dermatol.* 2000;42(2Pt 1):245–253. doi:10.1016/S0190-9622(00)90133-6
- Mohamed H, Mohammed G, Gomaa A, et al. Carbon dioxide laser plus topical 5-fluorouracil: a new combination therapeutic modality for acral vitiligo. *J Cosmet Laser Ther.* 2015;17(4):216–223. doi:10.3109/14764172.2014.1003241



11. Ortonne JP, MacDonald DM, Micoud A, et al. PUVA induced repigmentation of vitiligo: a histochemical (split-DOPA) and ultrastructural study. *Br J Dermatol.* 1979;101(1):1–12. doi:10.1111/bjd.1979.101.issue-1
12. Cui J, Shen L, Wang G. Role of hair follicles in the repigmentation of vitiligo. *J Invest Dermatol.* 1991;97(3):410–416. doi:10.1111/1523-1747.ep12480997
13. Mina M, Elgarhy L, Al-saeid H, et al. Comparison between the efficacy of microneedling combined with 5-fluorouracil vs microneedling with tacrolimus in the treatment of vitiligo. *J Cosmet Dermatol.* 2018;17(5):744–751. doi:10.1111/jocd.12440
14. Alghamdi KM, Kumar A, Taieb A, et al. Assessment methods for the evaluation of vitiligo. *J Eur Acad Dermatol Venereol.* 2012;26(12):1463–1471. doi:10.1111/j.1468-3083.2012.04505.x
15. Sheth VM, Rithe R, Pandya AG, et al. A pilot study to determine vitiligo target size using a computer-based image analysis program. *J Am Acad Dermatol.* 2015;73(2):342–345. doi:10.1016/j.jaad.2015.04.035

## Clinical, Cosmetic and Investigational Dermatology

Dovepress

### Publish your work in this journal

Clinical, Cosmetic and Investigational Dermatology is an international, peer-reviewed, open access, online journal that focuses on the latest clinical and experimental research in all aspects of skin disease and cosmetic interventions. This journal is indexed on CAS.

The manuscript management system is completely online and includes a very quick and fair peer-review system, which is all easy to use. Visit <http://www.dovepress.com/testimonials.php> to read real quotes from published authors.

Submit your manuscript here: <https://www.dovepress.com/clinical-cosmetic-and-investigational-dermatology-journal>