

Effectiveness of Aloe Vera Gel compared with 1% silver sulphadiazine cream as burn wound dressing in second degree burns

Muhammad Naveed Shahzad, Naheed Ahmed

Abstract

Objective: To assess the efficacy of Aloe Vera gel compared with 1% silver sulfadiazine cream as a burn dressing for the treatment of superficial and partial thickness burns.

Methods: This Interventional Comparative study was carried out at the Burn unit and Plastic surgery department, Nishtar Hospital Multan, Pakistan from July 2008 to December 2010. A total of 50 patients with superficial and partial thickness burns were divided into two equal groups randomly by consecutive sampling method, one group was dressed with Aloe Vera gel while the other was treated with 1% silversulphadiazine cream, and the results regarding duration of wound epithelialization, pain relief and cost of treatment were compared.

Results: In patients treated with Aloe Vera gel, healing of burn wounds were remarkably early than those patients treated with 1% silver sulfadiazine. All the patients of Aloe Vera group were relieved of pain earlier than those patients who were treated with SSD.

Conclusion: Thermal burns patients dressed with Aloe Vera gel showed advantage compared to those dressed with SSD regarding early wound epithelialization, earlier pain relief and cost-effectiveness.

Keywords: Aloe Vera gel, Second degree burns, Aloe Vera gel vs. 1% Silver sulphadiazine cream. (JPMA 63: 225; 2013)

Introduction

Burn injuries are among the most devastating of all injuries and a major global public health crisis.^{1,2} Burns are the fourth most common type of trauma worldwide, following traffic accidents, falls, and interpersonal violence.³ Approximately 90 percent of burns occur in low to middle income countries, regions that generally lack the necessary infrastructure to reduce the incidence and severity of burns.⁴ Despite recent advances in antimicrobial chemotherapy and wound management, infection continues to be an important problem in the treatment of burns. One of the most effective means to achieve a microbial balance in a colonized or infected wound is the proper use of prophylactic topical agents. Maintaining wounds at low colonization levels diminishes the frequency and duration of septic episodes caused by wound flora.⁵ The introduction of topical antimicrobial agents has resulted in a significant reduction in burn mortality to date.^{6,7} Recent studies have demonstrated that some agents used in the past are no longer effective in inhibiting bacterial growth in vitro.⁸

The most common topical antimicrobial agent used is 1% silver sulfadiazine (SSD) cream.⁹ Its side effects are delayed wound healing,¹⁰ resistance to 1% silver sulfadiazine (SSD) cream, renal toxicity, and leukopenia:

.....
Department of Plastic Surgery, Nishtar Hospital, Multan.

Correspondence: Muhammad Naveed Shahzad.

Email: drmuhammaad@gmail.com

several studies confirmed that this topical cream should not be used for long periods on extensive wounds.^{11,12}

Aloe Vera (family: Liliaceae) has a long association with herbal medicine.^{13,14} Aloe Vera gel, obtained by breaking or slicing a leaf, contains nutrients, vitamins, antioxidants and has wound healing and immunomodulating effects.¹⁵⁻¹⁹ Although burn wound healing is one of major indications of Aloe Vera gel use in several animal and clinical studies, few studies have compared the efficacy of this gel with SSD in the treatment of burns.¹⁶

The purpose of the present study was to compare the efficacy of SSD and Aloe Vera dressing for treatment of partial thickness burn wounds.

Patients and Methods

In our study we used Aloe Vera gel (AloeTone JelR). This product consists of the 98 % of unrefined gel from inner leaf of the plant.

This international comparative study was conducted in the burn unit/plastic surgery department, Nishtar Hospital Multan during the period from July, 2008 to December, 2010.

After approval of the study protocol from the Institutional Ethical Committee, 50 patients who had second degree burns were enrolled. Patients with second degree burns who presented within 24 hours and had total burn surface area (TBSA) < 25 % involved were included. Patients who had corrosive, electrical and chemical burns and history of

diabetes, hypertension, epilepsy, kidney disease or pregnancy were excluded.

All burn patients were received in A & E department of Nishtar Hospital Multan where the fluid resuscitation was done and every effort was made to eliminate shock. After that patients were admitted in the burns unit. Wounds were cleaned with pyodine scrub and normal saline and the topical agent either aloe vera gel or 1% SSD cream was applied to the wound. Treatment with topical agents was continued until the burns were fully healed and re-epithelialized. Empirically, 3rd generation cephalosporins were started in all patients. Wound swab cultures from three different sites from all patients were taken, at the time of admission and then at every seventh day and then antibiotics were initiated according to the results of bacteriological examination.

Relevant data of patients regarding their registration, history, site of burn, TBSA affected degree of burn, depth of burn, presence or absence of slough in the wound, medical report, operative notes, pre- and postoperative photographs, duration of hospital stay and outcome were filed individually. During their stay in the ward, strict monitoring of intake/ output was done. Where indicated, patients were supported with blood products. In all the patients, great care was given to nutrition. Almost all the patients were given oral feed with occasional intravenous support in the form of amino acid infusion in a few patients.

Fifty patients with second degree burns were randomized (consecutive sampling method) into 2 groups and were given burn wound treatment with SSD (25 patients) or aloe vera (25 patients). Both groups were compared with regard to patient demographics including age, sex, type of burn, TBSA burn (%), time elapsed after burns to reach the hospital. Patients were also reviewed for documentation of efficacy of treatment including time required for healing (epithelialization), pain scores, type of cultured organisms, wound colonization and infection, cost of treatment and mortality between both groups.

Wound dressing was done twice a day until healing was complete. Before dressing we washed wounds with pyodine scrub and then either aloe vera soaked gauzes or 1% Silver sulphadiazine dressing was done. At the time of change of dressing details regarding the condition of the wound such as signs of wound infection, condition of surrounding unburned tissues, discharge, smell, necrotic tissue and state of epithelialisation was noted by on every 3rd day. Subjective factors such as pain and local irritation were recorded regularly. Allergies or other side effects were noted in both groups. The patients and attendants were given information regarding the Aloe Vera gel and

SSDe cream.

Tape method was used to measure length and width of the wound and then these measurements were multiplied i.e. Area (in centimetre square) = length x width.

The wound progression was measured by calculating percentage rate of change by a simple statistical calculation by using the following formula:

$$\text{Wound area an admission day} - \text{Area on 2nd time} \times 100\% \\ \text{Baseline wound area an admission day.}$$

Pain relief was noted by visual analogue scoring system (1-10). Pain was considered as severe for score 6-10, moderate 3-5, and mild less than 3. Pain was considered relieved if patient scored 0-1.

Final outcome was measured after 2 months of follow-up, in terms of complete and incomplete recovery. Complete recovery included complete healing without scar or contracture. Formation of soft scar, hypertrophic scar and/or contracture was taken as incomplete recovery.

Statistical analysis was done using SPSS 11 software. Two-Tailed Unpaired Student T-Test was used to analyse predictors between two groups. P value of less than 0.05 was considered to indicate statistical significance.

Results

Demographic characteristics and other parameters of the patients are summarized in Table-1. All patients in the present study survived.

The authors found no significant differences in age, total body surface area, type of burn injury, time elapsed after burns to reach the hospital. Of fifty patients, 26 were male and 24 were female (age range 15-65 years). In Aloe group, epithelialization begun at 5th day, and in all patients healing was complete by 40th day (Mean= 11 4.18), whereas in SSD group healing was prolonged (Mean= 24.24 11.16).

Thirty eight patients (76%) developed wound colonization, sixteen (64%) in the Aloe group and twenty-two (88%) in the 1% SSD group. There were no differences in wound infection between both groups (seven patients developed wound infection; three in the Aloe group and four in the 1% SSD group, $p > 0.0$). All of the patients who developed wound infection responded well to targeted topical and systemic antibiotic treatment.

In Aloe group, 9 patients (36%) had complete relief of pain by 5th day; another 9 patients (36%) were relieved by 12th day. Pain relief was slow in SSD group and it took 26 days for all patients to be pain free in SSD group.

Table: Demographics of patients in both groups & Comparison of results in both groups.

Patient Characteristics	Aloe group		SSD group		
	No of cases(n=25)	%age	No of cases(n=25)	%age	
Gender of patient	Male	17	68%	09	36%
	Female	8	32%	16	64%
Type of burn injury in both group	Flame	16	64%	11	44%
	Scald	9	36%	14	56%
Age of patient	11-20	4	16%	5	20%
	21-30	16	64%	10	40%
	31-40	4	16%	6	24%
	41-50	3	12%	3	12%
	>50 YEARS	2	8%	1	4%
	Minimum age =15 years. Maximum age =65 years				
	Mean = 30.18±12.06				
Total body surface area	P value = 0.6691 [not statistically significant]				
	5 - 10%	2	8%	3	12%
	11-15%	17	68%	15	40%
	16-20%	4	16%	4	16%
	21-25%	2	8%	3	12%
	Minimum (TBSA)=6%. Maximum(TBSA)=25%				
Time elapsed after burns to reach the hospital	Mean = 13.64±4.68				
	P value = 0.1323[not statistically significant]				
	<1 hour	3	12%	4	16%
	1-8 hours	12	48%	14	56%
	9-16 hours	6	24%	3	12%
Time required for healing (epithelialization)	17-24 hours	4	16%	4	16%
	5 - 10 days	14	56%	3	12%
	11 - 15 days	6	24%	2	8%
	16 - 20 days	3	12%	7	28%
	21 - 30 days	1	4%	8	32%
	31 - 40 days	1	4.0%	3	12%
	41 - 50 days	0	0%	1	4%
	51 - 60 days	0	0%	1	4%
	Aloe group				
	◆ Minimum days for epithelialization =5 days				
	◆ Maximum days for epithelialization =20 days				
	◆ Mean =11±4.18				
	Silversulphadiazine Group				
◆ Minimum days for epithelialization =9 days					
◆ Maximum days for epithelialization =56 days					
◆ Mean = 24.24±11.16					
P value = < 0.0001[extremely statistically significant].					
Type of cultured wound organisms between 2 treatment groups	MRSA	6	24%	7	28%
	Pseudomonas spp.	8	32%	9	36%
	Acinetobacter spp	4	16%	2	8%
	Enterobacter	4	16%	2	8%
	Staph.				
	Coagulase ne	2	8%	3	12%
	E coli	1	4%	2	8%
Time taken for pain relief (days)	Up to 5	9	(36.0%)	1	4.0%
	6 - 12	9	36%	11	44%
	13 - 21	7	28%	11	44%
	22 - 26	0	0%	2	8%
	Silversulphadiazine Group				
	◆ Time taken for Complete pain relief = 26 days				
Aloe group					
◆ Time taken for Complete pain relief = 21 days					
p-value = 0.01 between the two groups is statistically significant					

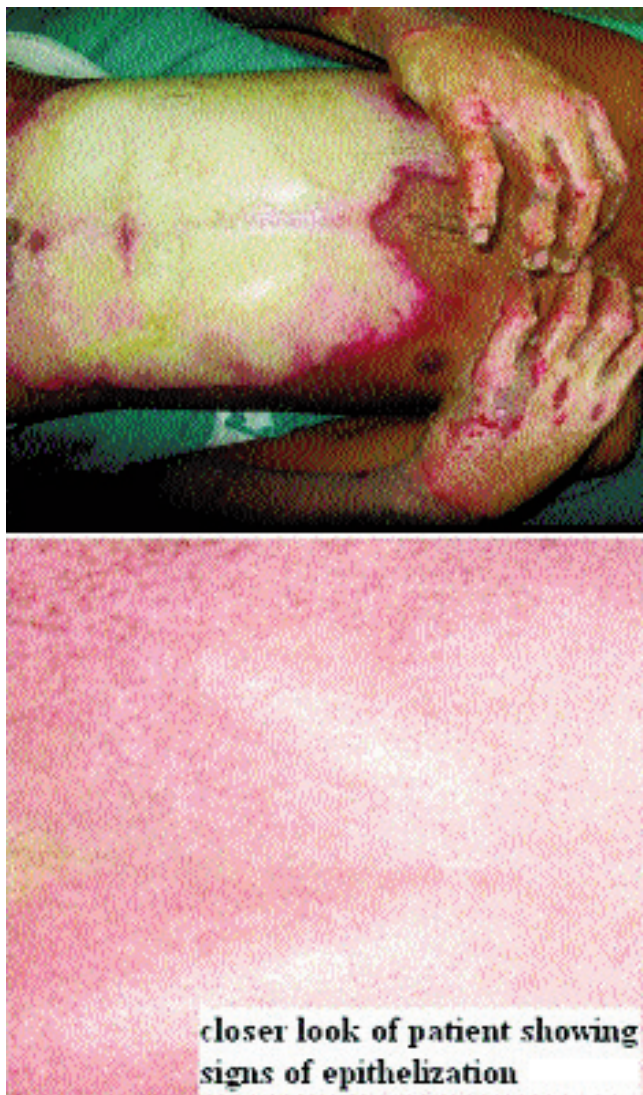


Figure-1: A young patient of 22 years had a flame burn (TBSA = 20%), Aloe Vera dressing was done. (a)= Second degree burn after wound wash at the time of admission. (b)= At 5th day epithelisation started and was complete at 11th day.

The price of 1000ml of Aloe gel was Rs.480, whereas the price of 250gm of Silver sulphadiazine was Rs.617. The cost of Dressing per percent body surface burnt per dressing of silver sulfadiazine was Rs.4.92 for 2grams of ointment and Rs.2.40 for 5ml of Aloe gel.

Among 25 patients treated with Aloe dressing, 24 patients had complete recovery while 1 had incomplete. In the SSD group, out of 25 patients, 19 patients had complete recovery and 6 had hypertrophic scar formation or the development of contractures. These differences were statistically significant.

Figure-1 and 2 show the results of aloe vera dressing.

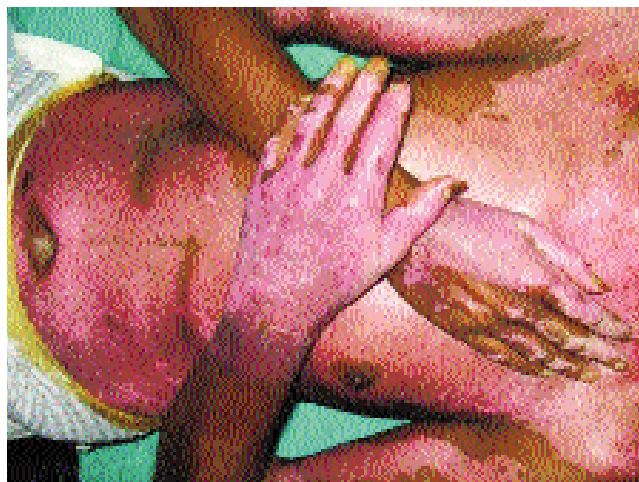

Figure-2: A male patient 42 year of age had a flame burn treated with Aloe Vera Dressing. Wound showing epithelisation at the time of discharge at 14th day post burn.

Discussion

Aloe Vera has been used for medicinal purposes in several cultures for millennia: Greece, Egypt, India, Mexico, Japan and China.¹⁸ Egyptian queens Nefertiti and Cleopatra used it as part of their regular beauty regimes. Alexander the Great, and Christopher Columbus used it to treat soldiers' wounds. The first reference to Aloe vera in English was a translation by John Goodyew in A.D. 1655 of Dioscorides' Medical treatise *De Materia Medica*.¹⁹ By the early 1800s, Aloe Vera was in use as a laxative in the United States, but in the mid-1930s, a turning point occurred when it was successfully used to treat chronic and severe radiation dermatitis.²⁰

Aloe Vera contains 75 potentially active constituents: vitamins (vitamins A, C and E, vitamin B12, folic acid, and choline), enzymes (alkaline phosphatase, amylase, bradykinase, carboxypeptidase, catalase, cellulase, lipase, and peroxidase), minerals (calcium, chromium, copper, selenium, magnesium, manganese, potassium, sodium and zinc), sugars (monosaccharides and polysaccharides), lignin, saponins, salicylic acids and amino acids.²¹⁻²³ Salicylic acid in Aloe Vera gel possesses anti-inflammatory properties. Lignin, enhances penetrative effect of the other ingredients into the skin. Saponins that are the soapy substances form about 3% of the gel and have cleansing and antiseptic properties.

The normal wound repair process is coordinated and predictable series of cellular and biochemical events. Glucomannan, a mannose-rich polysaccharide, and gibberellin, a growth hormone, interacts with growth factor receptors on the fibroblast, thereby stimulating its activity and proliferation, which in turn significantly

increases collagen synthesis after topical and oral Aloe Vera.²⁴ Aloe gel not only increased collagen content of the wound but also changed collagen composition (more type III) and increased the degree of collagen cross linking. Due to this, it accelerated wound contraction and increased the breaking strength of resulting scar tissue.²⁵ An increased synthesis of hyaluronic acid and dermatan sulfate in the granulation tissue of a healing wound following oral or topical treatment has been reported.²⁶ Aloe Vera contains 6 antiseptic agents: Lupeol, salicylic acid, urea nitrogen, cinnamonic acid, phenols and sulfur. They all have inhibitory action on fungi, bacteria and viruses. Aloe vera inhibits the cyclooxygenase pathway and reduces prostaglandin E2 production from arachidonic acid. Recently, the novel anti-inflammatory compound called C-glucosyl chromone was isolated from gel extracts.²⁷

The antimicrobial effect of silver sulfadiazine is the only mechanism justifying its continued use in burn injury. However, resistance has been demonstrated. Hepatic or renal toxicity and leukopenia may be caused by the topical application of SSD. In fact, these side effects have been observed in the treatment of large wounds.¹⁰⁻¹²

The findings of this clinical study showed that aloe vera gel promoted burn wound healing more effectively than SSD. Existing evidence demonstrates that aloe vera used in a variety of forms might be effective in shortening the duration of wound healing in first to second degree burns, and it tended to increase rate of success to healing and rate of epithelialization. Aloe gel have been found to be effective for burn wound healing in animal models^{32,33} and humans.^{28,31-34} Thamlikitkul et al.²⁸ used Aloe fresh mucilage in 38 patients and found accelerated healing. Visuthikosol et al.²⁹ reported a study on 27 patients with partial thickness burn wounds treated either with gauze dressings saturated with Aloe vera gel. They observed significantly reduced wound healing time in the aloe-treated patients (11.19 days vs 11.89 days). Akhtar et al.³⁰ also observed significantly reduced wound healing time in the aloe-treated patients 18 18.9 days. Better Rate of epithelialization was also appreciated by Sun Ji Hai et al.³¹ In One Iranian study,³⁴ time taken for partial thickness burns to heal was 15.9 2 days. But, one clinical report³⁵ suggests that aloe can actually impair the healing of severe wounds. Schmidt et al,³⁵ evaluated the time interval required for wound healing using a standard wound management protocol with and without aloe vera gel in a randomized controlled trial. All patients had complications of wound healing. Only 21 of them completed the study. The mean

healing time in the conventional care group (53 days) was significantly shorter ($P < 0.003$) than in the aloe vera gel group (83 days).

In our study time taken for partial thickness burns to heal was significantly shorter with aloe than in those treated with SSD (11 4.18 days vs. 24.24 11.16 days). One study,³⁴ has demonstrated antimicrobial effect of aloe vera, but in our There were no differences in wound infection between both groups.

In Aloe group, patients were rendered pain free early, mean pain relief was by 12th day, while with the SSD dressing mean pain relief was in 16.8 days. Cost of treatment with Aloe came out to be significantly less than that with Silver sulphadiazine. No allergic reaction or side effect was noted in any of our patients dressed with Aloe or SSD. Only irritation, itching, discomfort, and minimal transient pain were reported. However, these events were common signs and symptoms in burns, and they were present in both the aloe and the control groups.²⁸⁻³⁰

Conclusion

In conclusion, aloe vera gel promoted wound healing in second degree burn patients better than SSD cream. The mechanism of the remarkable efficacy of aloe cream in the healing of burn injuries may be explained by its cell proliferation, and anti-inflammatory effects. It also relieves pain better than SSD and is cost effective.

Recommendations

Well-designed trials with sufficient details of the contents of aloe vera products should be carried out for determining the effectiveness of aloe vera for burn wound healing. As existing evidence lack such trails.

References

1. Forjuoh SN. Burns in low- and middle-income countries: a review of available literature on descriptive epidemiology, risk factors, treatment, and prevention. *Burns* 2006; 32:529.
2. Peck MD, Kruger GE, van der Merwe AE, Goaakumbra W, Ahuja RB. Burns and fires from non-electric domestic appliances in low and middle income countries Part I. The scope of the problem. *Burns* 2008; 34: 303-11.
3. World Health Organization. The Global Burden of Disease: 2004 Update. World Health Organization, Geneva 2008. (Online) (Cited 2010 Apr 2). Available from URL:http://www.who.int/healthinfo/global_burden_disease/GBD_report_2004update_full.pdf.
4. Murray, CJL, Lopez AD. The global burden of disease: a comprehensive assessment of mortality and disability from diseases, injuries, and risk factors in 1990 and projected to 2020. Geneva, Switzerland: World Health Organization, 2006.
5. Pruitt BA, Foley FD. The use of biopsies in burn patient care. *Surgery* 1973; 73: 887-97.
6. Robson MC. The use of topical agents to control bacteria. In: Dimick AR, ed. *The burn wound in practical approaches to burn*

- management. Deerfi eld, IL: Flint Laboratories, Travenol 1977; pp 17-9.
7. Moncrief JA. The status of topical antibacterial therapy in the treatment of burns. *Surgery* 1968; 63: 862.
 8. Kucan IO, Smoot EC. Five percent mafenide acetate solution in the treatment of thermal injuries. *J Burn Care Rehabil* 1993; 14: 158-63.
 9. Vloemans AFPM, Soesman AM, Suijker M, Kreis RW, Middelkoop E. A randomized clinical trial comparing a hydrocolloid- derived dressing and glycerol preserved allograft skin in the management of partial thickness burn. *Burns* 2003; 29: 702-10.
 10. Visuthikosol V, Chowchuen B, Sukwanarat Y, Sriurairatana S, Boonpucknavig V. Effect of aloe vera gel to healing of burn wound a clinical and histologic study. *J Med Assoc Thai* 1995; 78: 403-9.
 11. Atiyeh BS, Costagliola M, Hayek SN, Dibo S. Effect of silver on burn wound infection control and healing: review of the literature. *Burns* 2007; 33: 139-48.
 12. Klasen HJ. A historical review of the use of silver in the treatment of burns. II. Renewed interest for silver. *Burns* 2000; 26: 131-8.
 13. Marshall JM. Aloe vera gel: What is the evidence? *Pharm J* 1990; 24: 360-2.
 14. Reynolds T, Dweck AC. Aloe vera leaf gel: a review update. *J Ethnopharmacol* 1999; 68: 3-37.
 15. Hu Q, Hu Y, Xu J. Free radical-scavenging activity of Aloe vera (*Aloe barbadensis* Miller) extracts by supercritical carbon dioxide extraction. *Food Chem* 2005; 91: 85-90.
 16. Maenthaisong R, Chaiyakunapruk N, Niruntraporn S, Kongkaew C. The efficacy of aloe vera used for burn wound healing: a systematic review. *Burns* 2007; 33: 713-8.
 17. Rodriguez-Bigas M, Cruz NI, Suarez A. Comparative evaluation of aloe vera in the management of burn wounds in guinea pigs. *Plast Reconstr Surg* 1988; 81: 389-96.
 18. West DP, Zhu Yf. Evaluation of aloe vera gel gloves in the treatment of dry skin associated with occupational exposure. *Am J Infect Control* 2003; 31: 40-2.
 19. Marshall JM. Aloe vera gel: What is the evidence? *Pharma Jr* 1990; 24: 360-2.
 20. Davis RH. Aloe vera: A scientific approach. New York: Vantage Press.
 21. Tyler V. The honest herbal: A sensible guide to the use of herbs and related remedies. 3rd ed. Binghamton, New York: Pharmaceutical Products Press, 1993.
 22. Atherton P. Aloe vera revisited. *Br J Phytother* 1998; 4: 76-83.
 23. Shelton M. Aloe vera, its chemical and therapeutic properties. *Int J Dermatol* 1991; 30: 679-83.
 24. Chithra R, Sajithlal GB, Chandrakasan G. Influence of aloe vera on collagen characteristics in healing dermal wounds in rats. *Mol Cell Biochem* 1998; 181: 71-6.
 25. Heggors J, Kucukcelebi A, Listengarten D, Stabenau J, Ko F, Broemeling LD, et al. Beneficial effect of aloe on wound healing in an excisional wound model. *J Altern Complement Med* 1996; 2: 271-7.
 26. Chithra P, Sajithlal G, Chandrakasan G. Influence of aloe vera on the glycosaminoglycans in the matrix of healing dermal wounds in rats. *J Ethnopharmacol* 1998; 59: 179-86.
 27. Hutter JA, Salmon M, Stavinoha WB, Satsangi N, Williams RF, Streeper RT, et al. Anti-inflammatory C-glucosyl chromone from *Aloe barbadensis*. *J Nat Prod* 1996; 59: 541-3.
 28. Thamlikitkul V, Bunyapraphatsara N, Riewpaiboon W, Theerapong S, Chantrakul C, Thanaveerasuwan T, et al. Clinical trial of aloe vera Linn. for treatment of minor burns. *Siriraj Hosp Gaz* 1991; 43: 313-6.
 29. Visuthikosol V, Sukwanarat Y, Chowchuen B, Sriurairatana S, Boonpucknavig V. Effect of aloe vera gel to healing of burn wound a clinical and histologic study. *J Med Assoc Thai* 1995; 78: 403-8.
 30. Akhtar MA, Hatwar SK. Efficacy of aloe vera extract cream in management of burn wound. *J Clin Epidemiol* 1996; 49(Suppl-1): 24.
 31. Sun JH, Chen XG, Jin RT, Li TN, Bian YX. People's Liberation Army medicine information. *Med J Chin Army* 1994; 8: 191-2.
 32. Rodriguez-Bigas M, Cruz NI, Suarez A. Comparative evaluation of aloe vera in the management of burn wounds in guinea pigs. *Plast Reconstr Surg* 1988; 81: 389-96.
 33. Somboonwong J, Thanamitramanee S, Jariyapongskul A, Patumraj S. Therapeutic effects of Aloe vera on cutaneous microcirculation and wound healing in second degree burn model in rats. *J Med Assoc Thai* 2000; 83: 417-25.
 34. Khorasani G, Hosseinimehr SJ, Azadbakht M, Zamani A, Mahdavi MR. Aloe versus silver sulfadiazine creams for second-degree burns: a randomized controlled study. *Surg Today* 2009; 39: 587-91.
 35. Schmidt JM, Greenspoon JS. Aloe vera dermal wound gel is associated with a delay in wound healing. *Obstet Gynecol* 1991; 78: 115-7.