

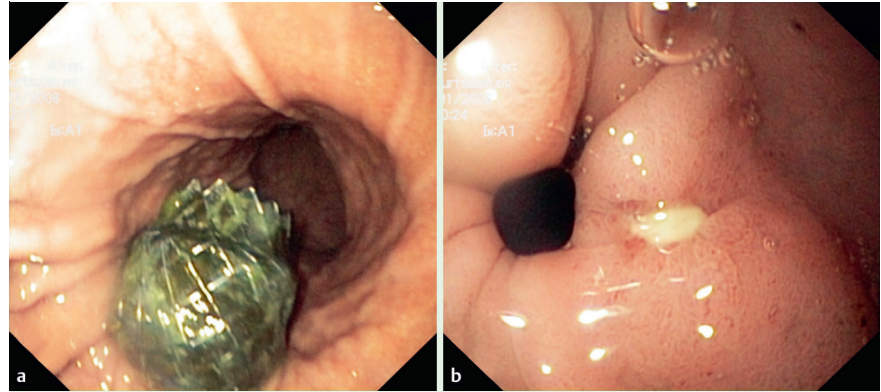
## Fracture of a covered self-expanding antireflux stent in two patients with distal esophageal carcinoma

Endoscopic insertion of esophageal self-expandable antireflux metal stents is a widely used procedure. The implantation is usually regarded as safe, with a low rate of complications. Here we report two cases of spontaneous fracture of Hanaro (M. I. Tech Co., Ltd., Seoul, South Korea) antireflux stents.

A 69-year-old patient with metastasized stenosing Barrett's carcinoma received a Hanaro stent (ref HEV-18-160-070; lot no. 07061422) at the University Hospital of Leipzig in August 2007. In January 2008, upper gastrointestinal endoscopy revealed complete fracture of the distal third of the stent and dislocation of the distal part of the stent into the antrum, which had caused a prepyloric ulcer (▶ Fig. 1). Both fragments of the stent were removed immediately by endoscopy (▶ Fig. 2). Eight days later, a replacement stent (ref HEVT-22-120-070; lot no. 07081314) was implanted without further complications.

A similar stent (ref 1-ECF-22120-Z070; lot no. 08021228) was implanted in a 72-year-old patient with metastasized distal esophageal carcinoma at St Mary's Hospital, Berlin, in May 2008. Peritrast swallow showed regular placement of the stent (▶ Fig. 3). Two months later, a contrast-enhanced computed tomography (CT) scan was taken at the University Hospital Charité, Campus Benjamin Franklin, Berlin. The scan showed an incomplete fracture in the proximal third of the stent (▶ Fig. 4). Both fragments of the stent were removed immediately by endoscopy.

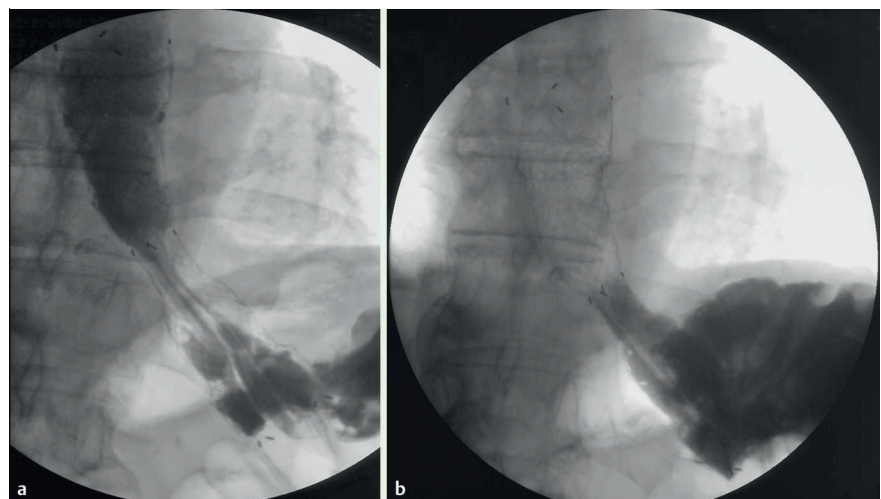
Fracture of an esophageal stent is a rare event. A Medline search revealed only five reports of six patients. The authors of these reports suggested that the fractures were caused by thermal overstrain induced by laser application [1] or defective material [1,2], or that they were spontaneous [3–5]. All the stents used in the above reports were self-expandable metal stents without an antireflux valve and were constructed from different materials (mostly nitinol) and obtained from different companies. To our knowledge, we report the first two incidents of frac-



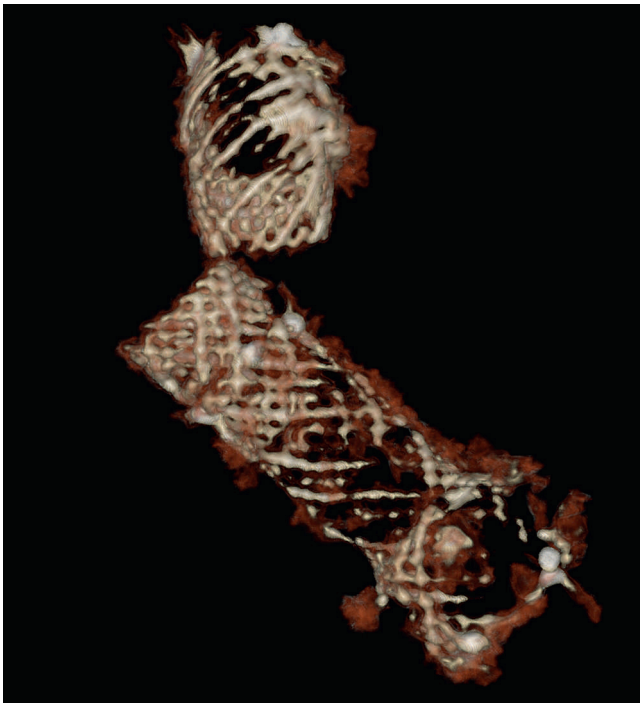
**Fig. 1** Endoscopic view of: **a** the distal fragment of the fractured stent; and **b** an ulcer in the prepyloric antrum.



**Fig. 2** Distally fractured stent after removal.



**Fig. 3** Peritrast swallow after placement of the antireflux stent. **a** Regular passage of contrast medium. **b** Functional antireflux valve.



**Fig. 4** Three-dimensional computed tomography (CT) reconstruction of the proximally fractured stent.

tured antireflux esophageal stents. We recommend including stent fracture as potential complication in patient consent forms.

Endoscopy\_UCTN\_Code\_CPL\_1AH\_2AD

**M. Wiedmann<sup>1,2</sup>, F. Heller<sup>3</sup>, M. Zeitz<sup>3</sup>, J. Mössner<sup>1</sup>**

<sup>1</sup> Division of Gastroenterology, Department of Internal Medicine, University of Leipzig, Germany

<sup>2</sup> Department of Internal Medicine I, St Mary's Hospital Berlin, Germany

<sup>3</sup> Department of Gastroenterology, Infectious Diseases, and Rheumatology, Charité, Campus Benjamin Franklin, Berlin, Germany

## References

- 1 Schoefl R, Winkelbauer F, Haefner M et al. Two cases of fractured esophageal nitinol stents. *Endoscopy* 1996; 28: 518–520
- 2 Grimley CE, Bowling TE. Esophageal metallic stent dysfunction: first reported case of stent fracture and separation. *Endoscopy* 1999; 31: S45
- 3 Reddy AV, Alwair H, Trewby PN. Fractured esophageal nitinol stent: report of two fractures in the same patient. *Gastrointest Endosc* 2003; 57: 138–139
- 4 Chhetri SK, Selinger CP, Greer S. Fracture of an esophageal stent: a rare but significant complication. *Endoscopy* 2008; 40 (Suppl 2): E199
- 5 Dogan UB, Egilmez E. Broken stent in oesophageal malignancy: a rare complication. *Acta Gastroenterol Belg* 2005; 68: 264–266

## Bibliography

**DOI** 10.1055/s-0029-1214661

*Endoscopy* 2009; 41: E129–E130

© Georg Thieme Verlag KG Stuttgart · New York · ISSN 0013-726X

## Corresponding author

**M. Wiedmann, MD**

Department of Internal Medicine I

St Mary's Hospital

Gallwitzallee 123–143

12249 Berlin

Germany

Fax: +49-30-76783425

Wiedmann@marienkrankenhaus-berlin.de