

Case reports

Inheritance was dominant and therefore unlike the present family.

Moynahan¹ reported male sibs with mental subnormality, epilepsy (onset at 2 to 3 years), and alopecia which involved the scalp only. The hair later regrew. The mode of inheritance in this family is difficult to ascertain as the boy's father only grew hair at the age of 2 years and the boy's mother's sister was bald until the age of 4 years. The regrowth of the hair, the restriction of the baldness to the scalp, and the epilepsy differentiate Moynahan syndrome from the one described here. A similar condition in two sibs whose parents were consanguineous was reported by Perniola *et al.*³ Deafness occurred in both. There are at least three other syndromes in which hair loss is associated with mental retardation. Menkes disease can be excluded as the hair is kinky and not totally absent. Prognosis for life is poor and seizures are frequent. Inheritance is X linked recessive. In Monilethrix the hair is normal at birth but is then lost within the first few months. Red pustular lesions on the scalp may be present. Alopecia is seldom total and through the pustules brittle hairs which break easily emerge. The nails and teeth are abnormal and mental retardation is only occasionally a feature. In the Hair-Brain syndrome (Amish brittle hair syndrome) those affected had short stature and relatively mild mental retardation. All the affected had hair but it was brittle and broke easily. Total alopecia was not a feature and inheritance was recessive.

In the condition described in this paper, the alopecia was total and involved all areas of normal hair growth. It probably represents a distinct entity.

M BARAITSER, C O CARTER, AND E M BRETT*

*Clinical Genetics Unit and *Department of Neurology, The Hospital for Sick Children, Great Ormond Street, London WC1N 3JH.*

References

- 1 Moynahan EJ. Familial congenital alopecia, mental retardation with unusual electroencephalograms. *Proc R Soc Med* 1962;**55**:411-2.
- 2 Shokeir MHK. Universal permanent alopecia, psychomotor epilepsy, pyorrhoea and mental subnormality. *Clin Genet* 1977;**11**:13-17.
- 3 Perniola T, Krajewska G, Carnevale F, Lospalluti M. Congenital alopecia, psychomotor retardation, convulsions in two sibs of a consanguineous marriage. *J Inher Met Dis* 1980;**3**:49-53.

Requests for reprints to Dr M Baraitser, Clinical Genetics Unit, The Hospital for Sick Children, Great Ormond Street, London WC1N 3JH.

A female infant with features of Mohr and Majewski syndromes: variable expression, a genetic compound, or a distinct entity?

SUMMARY A female child, the offspring of a consanguineous mating, had a cleft palate, tongue tumours, hypoplastic tibiae, and polysyndactyly. The relationship to the Mohr and Majewski syndromes is discussed.

Variable expression is a common problem encountered by those who seek to define syndromes. The best method to determine the extent of the phenotypic expression of a gene defect is to study the variability within sibships, but in rare disorders this is not always possible. It is then necessary to depend on somewhat arbitrary definitions. The Mohr and Majewski syndromes each behave as a probable autosomal recessive disorder^{1,2} with a relatively distinct phenotype. Temtamy and McKusick³ reported two subjects whose clinical features fulfilled the definition of both syndromes. We report a female infant, the second child of consanguineous parents, in whom combined features of both syndromes were seen.

Case report

The patient was born on 9.9.81 at 33 weeks' gestation weighing 1520 g. She was the second child of first cousin Pakistani Moslem parents. The mother and father were 19 and 21 years old, respectively. A sib was normal and there was no relevant family history.

The child (fig 1) was noted to have low set ears, micrognathia, and shallow orbits causing mild proptosis. There was a high arched palate with a posterior cleft and fleshy tumours were present on the underside of the tongue. Bilateral postaxial polysyndactyly was noted in the hands with polysyndactyly, severe talipes equinovarus, and distal shortening of both lower limbs.

At 6 months her weight of 4.2 kg was well below the 3rd centile. She fed poorly and had frequent chest infections. Her development was slightly delayed. Radiological examination revealed severe bilateral tibial dysplasia (fig 2), whereas the chest x-ray did not show significant rib shortening. There was a normal 46,XX karyotype.

Received for publication 23 July 1982.

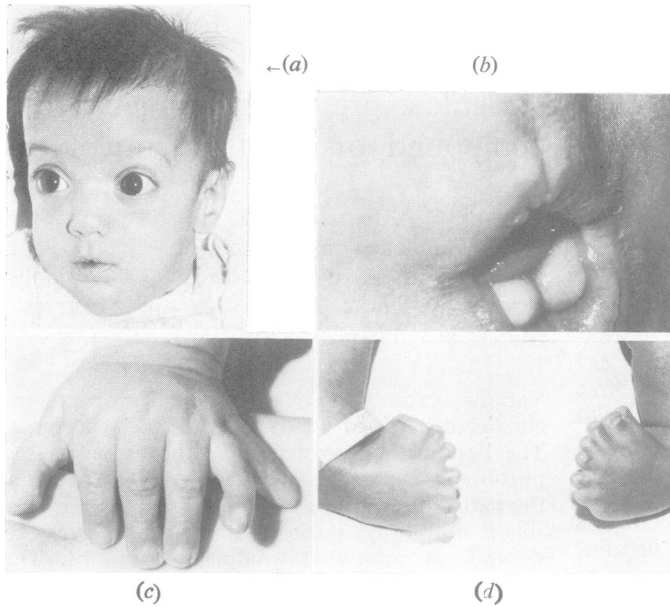


FIG 1 (a) Facial appearance of proband. Note flat nasal bridge and prominent eyes. (b) Sublingual fleshy tumours. (c) Postaxial polydactyly of hands. (d) Pre- and postaxial polydactyly and severe talipes affecting both feet.

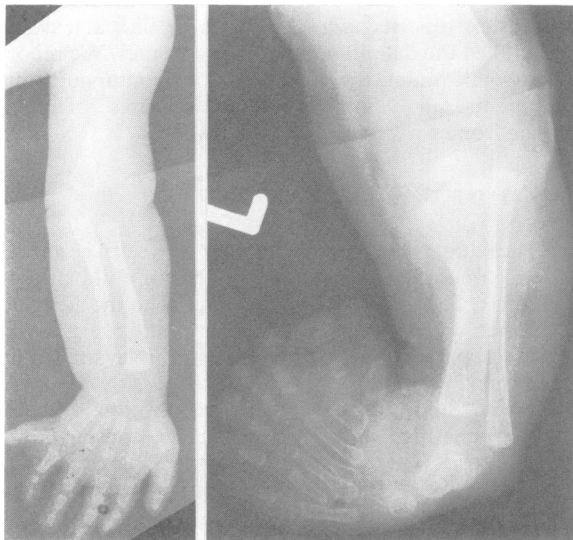

FIG 2 X-ray appearance of limbs. Note hypoplasia of tibia.

Discussion

The similarities between the orofacial digital syndrome type II (Mohr syndrome) and the short rib polydactyly syndrome type II (Majewski syndrome) are shown in the table.

It is apparent that mid-facial flattening, hypertelorism, tongue tumours, and multiple frenulae may occur in both syndromes. The Majewski syndrome is distinguishable by the presence of short

ribs, probably a major factor in the invariable neonatal death, and hypoplasia of the tibiae. In Mohr syndrome, survival is the rule and the tibiae are not hypoplastic. Possible exceptions have occurred. Spranger *et al*⁴ gave a brief report of a patient with features of Majewski syndrome whose sib might have been similarly affected and survived for 40 minutes. Rimoin and Edgerton⁵ reported a family in which a brother and sister had the typical features of Mohr syndrome, whereas a third sib who

TABLE Comparison of clinical features in the present patient with those of Mohr and Majewski syndromes.

	Majewski syndrome	Mohr syndrome	Present patient
Oral manifestations	Median cleft, or pseudo-cleft of upper lip	Pseudo-cleft tongue tumours, exaggerated multiple frenulae	Tongue tumours, exaggerated multiple frenulae
Deafness	?	+	?
Nose	Broad and flat	Broad and flat	Broad and flat
Eyes	Hypertelorism	Hypertelorism	Hypertelorism
Hand	Postaxial polydactyly	Pre- and postaxial polydactyly	Postaxial polydactyly
Foot	Postaxial polydactyly	Pre-axial polydactyly	Postaxial polydactyly
Tibia	Hypoplastic	Normal	Hypoplastic
Thorax	Narrow	Normal	Normal
Perinatal death	+	—	—
Inheritance	AR	AR	?AR (parental consanguinity)

was stillborn had the digital malformations and a cleft lip and palate, identical to those seen in the surviving sibs. X-rays of the lower limbs of the surviving sibs showed the proximal metaphysis of the tibiae and fibulae to be wide and misshapen. The proximal epiphysis of the tibiae and the distal epiphysis of the fibulae were flattened. The x-rays of the sib who died were not available.

Temtamy and McKusick³ reported two patients who combined the features of the two syndromes. In the first, there was a median pseudo-cleft of the upper lip, multiple frenulae, a normal tongue with a single yellow nodule on the lateral border, polydactyly, and syndactyly; the infant died at 7½ weeks following an aspiration. This was probably related to a hypoplastic epiglottis thought to be characteristic of the Majewski syndrome. X-rays of the tibiae were not shown. The second case had a small thorax, but survived despite respiratory problems in infancy. The limbs were short, particularly the tibiae which had rounded upper metaphyses. The facial features were compatible with either syndrome.

The present case represents, perhaps, the best illustration to date of a patient falling midway between the two conditions. The normal thorax and prolonged survival are against the diagnosis of Majewski syndrome, while the severe hypoplasia of the tibiae is against the diagnosis of Mohr syndrome. The child may be regarded as either a mild example of Majewski syndrome or an unusually severe example of Mohr syndrome. The general tendency of these syndromes to 'breed true' is somewhat against an explanation that suggests the two syndromes are not distinct. A third possibility is that the child represents a compound heterozygote for separate recessive alleles. The consanguinity in the parents is more in favour of homozygosity for a single abnormal allele within the family.

A fourth possibility is that this child is homozygous for a distinct recessive gene defect, possibly disturbing a similar developmental pathway to that involved in the other syndromes. The consanguinity of the parents provides support for this possibility,

though in view of the high level of inbreeding in the population from which this family originates, cousin marriage in the parents is of less significance.

In each of these four explanations, it is implied that children with the features described in the present report have a recessive condition and that the parents face a 1 in 4 risk of recurrence.

M BARAITSER*, J BURN†, AND J FIXSEN*

*The Hospital for Sick Children,
Great Ormond Street,
London WC1N 3JH; and
†MRC Clinical Genetics Unit,
Institute of Child Health,
30 Guilford Street,
London WC1N 1EH.

References

- Gorlin RJ, Pindborg JJ, Cohen MM. *Syndromes of the head and neck*. 2nd ed. New York: McGraw-Hill, 1976: 568-70.
- Black IL, Fitzsimmons J, Fitzsimmons E, Thomas AJ. Parental consanguinity and the Majewski syndrome. *J Med Genet* 1982;19:141-57.
- Temtamy S, McKusick V. The genetics of hand malformations. *Birth Defects* 1978;XIV:No 3.
- Spranger J, Grimm B, Weller M, et al. Short rib-polydactyly (SRP) syndromes, types Majewski and Saldino-Noonan. *Z Kinderheilkd* 1974;116:73-94.
- Rimoin DL, Edgerton MT. Genetic and clinical heterogeneity in the oral-facial-digital syndromes. *J Pediatr* 1967;71:94.

Requests for reprints to Dr M Baraitser, Clinical Genetics Unit, The Hospital for Sick Children, Great Ormond Street, London WC1N 3JH.

Addendum

Since the submission of this report for publication, a second affected child has been born to these parents. The infant has the same clinical and radiological features, details of which will be provided in a future report. This development adds weight to the view that this syndrome results from a distinct autosomal recessive gene defect.