

### Case reports

and large, low set ears with a well formed helix. The lenses and fundi were normal. Systemic examination showed marked failure to thrive, hypotonia, mental retardation, unilateral undescended testis, and small penis (fig 1). Both arms were normal in length. There was loose skin over the dorsal aspect of the metacarpophalangeal joints and an increase in fine palmar creases.

Dermatoglyphic examination showed bilateral simian creases, two arches, one radial loop, and two ulnar loops on each hand. His palms appeared to be longer than usual because of syndactyly of the skin between all fingers. All joints were hyperextensible. His mental age was around 9 months.

### LABORATORY STUDIES

Routine haematological, biochemical, and urinary studies were normal. His bone age was within normal limits.

Fifty metaphases, obtained by standard leucocyte culture techniques and stained with Giemsa, were analysed. Twelve of the metaphases had 45 chromosomes. Each of these cells lacked one chromosome 22: 45,XY,-22 (fig 2). In 38 other metaphases the chromosomal complement showed a normal 46,XY pattern. The chromosomal pattern of the mother was normal.

### Discussion

Despite the fact that banding techniques have been in use for almost a decade now, only one case of monosomy 22 without mosaicism has been described.<sup>4</sup> Our patient is the first case of mosaicism for monosomy 22, the majority of cells (38 of 50; 76%) having a normal 46,XY karyotype.

Patients with partial deletion of G group chromosomes have two different clinical syndromes: G<sub>1</sub> (antimongolism) and G<sub>2</sub> (involving chromosome 22). The patient of DeCicco *et al*<sup>4</sup> with monosomy 22 did not correspond to either of these. In patients with ring chromosome 22, as reported by Hunter *et al*,<sup>5</sup> mental retardation, microcephaly, growth failure, and hypotonia were found, as in other deletion 22 syndromes. In our patient, minor anomalies such as flat occiput, epicanthus, full eyebrows, dental malocclusion, and cutaneous syndactyly were also present, as in r(22) patients. More cases will have to be documented in detail, however, before a specific monosomy 22 syndrome can be delineated.

M S MOGHE, Z M PATEL, J J PETER,  
AND L M AMBANI  
*Unit of Medical Genetics, Institute for  
Research in Reproduction, Jehangir Merwanji  
Street, Parel, Bombay 400 012, India*

### References

- 1 Al-Aish MS, De La Cruz F, Goldsmith LA, Volpe J, Mella G, Robinson JC. Autosomal monosomy in man. *N Engl J Med* 1967;277:777-84.
- 2 Dhadiyal RK. Monosomy for G-autosome. *Arch Dis Child* 1969;44:113.
- 3 Warren RJ, Rimoin DL, Summitt RL. Identification by fluorescent microscopy of abnormal chromosomes, associated with G deletion syndrome. *Am J Hum Genet* 1973;25:77-81.
- 4 DeCicco F, Steele MW, Pan S, Parck SC. Monosomy of chromosome No 22. A case report. *J Pediatr* 1973;830: 836-8.
- 5 Hunter AGW, Ray M, Wang HS, Thompson DR. Phenotypic correlations in patients with ring chromosome 22. *Clin Genet* 1977;12:239-49.

Requests for reprints to Professor L M Ambani, Unit of Medical Genetics, Institute for Research in Reproduction, Jehangir Merwanji Street, Parel, Bombay 400 012, India.

## Variable expression in Pfeiffer syndrome

**SUMMARY** A female infant with Pfeiffer syndrome (acrocephalosyndactyly V) is presented. Her mother has no limb malformations, but has craniofacial features which strongly suggest that she is also affected, although more mildly.

This family indicates that wide intrafamilial variation of Pfeiffer syndrome is possible and suggests that without detailed investigation mildly affected subjects can remain undiagnosed, which may lead to erroneous genetic counselling.

In 1964, Pfeiffer<sup>1</sup> described a family in which eight subjects in three generations had a syndrome consisting of craniosynostosis, broad thumbs and big toes, and partial soft tissue syndactyly of the hands and feet. Vertical transmission of the trait, and the fact that males and females were equally affected, supported an autosomal dominant mode of inheritance. Because of the close phenotypic similarity to the Apert syndrome, Pfeiffer reported this family as having a mild form of that syndrome. However, in pedigree studies, no transition from one type to the other was observed. The syndromes are recognised by most investigators as separate entities,<sup>2</sup> although recent reports<sup>3 4</sup> have cast doubt on this conclusion.

We report a girl with typical Pfeiffer syndrome whose mother has abnormalities limited to the cranium and face, suggesting she is mildly affected.

Received for publication 4 April 1980

### Case report

The proband was examined by us when she was 3 years 4 months old. She was the product of an uneventful pregnancy and the second child of non-consanguineous parents who were 34 years old at her birth. At birth, anomalies of cranium, face, and extremities were noted. Because of coronal and sagittal suture synostosis, she was operated on at 3 months of age and again two and a half years later.

Physical examination (fig 1) showed acrocephaly, high forehead, hypertelorism, proptosis, malar hypoplasia, flattened face, short philtrum, open mouth, high palate, relative prognathism, and short neck. Her thumbs were broad and there was almost right angle deviation of the distal phalanx, rigidity of the second finger without flexion creases, and hyperconvex nails (fig 2). Both halluces were broad, there was soft tissue syndactyly between the second and third toes, and the nails were hyperconvex (fig 3). Her weight was on the 50th centile and

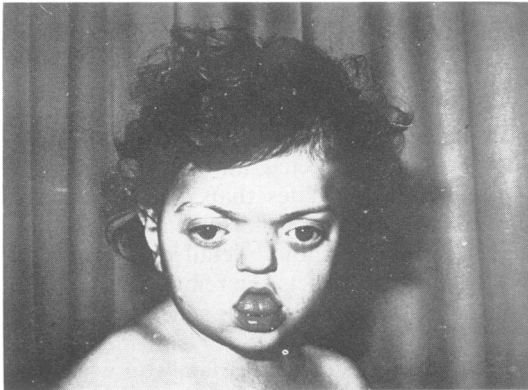

FIG 1 Face of proband.

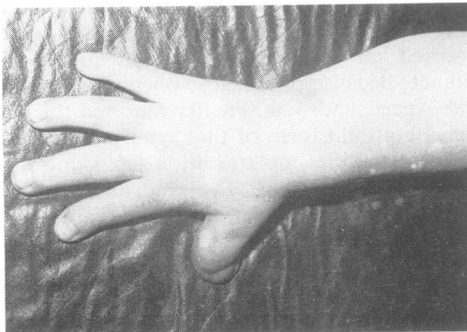


FIG 2 Hand of proband showing the typical shape of the thumb in Pfeiffer syndrome.

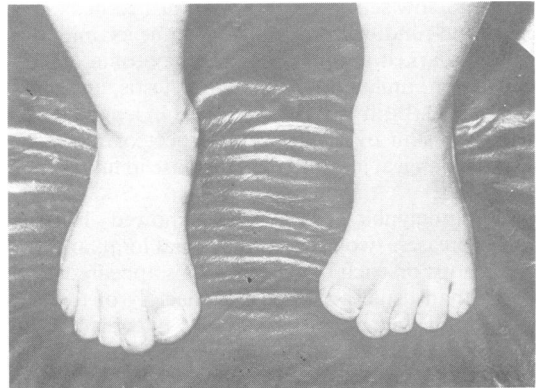


FIG 3 Feet of proband showing broad halluces and partial syndactyly between second and third toes.

height on the 25th centile. Radiographic evaluation showed: shortening of the anteroposterior diameter of the cranium and increase of its length in the vertical plane; craniosynostosis of all sutures, except the lambdoid; dysplasia of the thumbs with triangular shaped distal phalanges, and bilateral synostosis between the proximal and middle phalanges of the second fingers. The first metatarsals were wide and dysplastic.

Her mother (fig 4) had a high forehead, acrobrachycephalic cranium, left external strabismus,

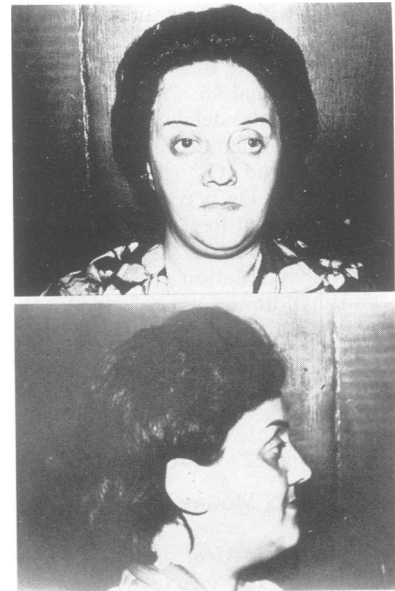

FIG 4 Mother of proband.

## Case reports

proptosis, malar hypoplasia, and relative prognathism. On physical and radiological examination, her hands and feet were normal. Metacarpophalangeal pattern profile (MCP) analysis<sup>5</sup> on photographs of the hands and feet of the mother by Dr Victor Escobar (University of Louisville) did not support the hypothesis that she was affected.

The proband's older brother and her mother's half sister were examined by us and found normal. No information could be obtained about the proband's grandparents. Chromosomal analysis using conventional and G banding techniques was normal: 46,XX.

## Discussion

The association of facial anomalies and craniosynostosis, with or without anomalies of the hands and feet, is common to the acrocephalosyndactylies and Crouzon syndrome. Blank<sup>6</sup> was one of the first to classify the acrocephalosyndactyly (ACS) syndromes by dividing them into two groups: typical (Apert syndrome) and several atypical forms, each the result of different mutations. This theory was based on the observation that only one type had been detected in the same family. Pfeiffer<sup>1</sup> in his original paper believed that this syndrome could represent a mild form of the Apert syndrome. However, Cohen<sup>2</sup> disagreed since no transition from one form to another in a single family has been observed. On the other hand, Jackson *et al*<sup>3</sup> reported, in a large Amish kindred, 88 patients with ACS; an additional 50 relatives were also reliably reported to be affected. They observed considerable phenotypic variation, and with the exception of the Apert syndrome, all forms of ACS were represented, including one patient with polysyndactyly of the feet. These observations suggest that there is considerable variation in the ACS syndromes.

Escobar and Bixler<sup>4</sup> recently described a family in which both Pfeiffer and Apert syndromes were present, while seven other subjects had an unusual head shape and face but without abnormalities of the hands or feet, resembling the Crouzon syndrome. These authors suggested that the classification of

ACS syndromes should be reviewed to determine whether Apert, Pfeiffer, Saethre-Chotzen, and Crouzon syndromes are not, in reality, the same disorder. Despite the lack of confirmation by MCP analysis that the proband's mother is affected, we believe that her craniofacial features are sufficiently demonstrative to support our hypothesis. In the family reported, wide variation in expression appears to exist in Pfeiffer syndrome, suggesting that relatives of affected subjects should be carefully examined for minor stigmata of this disorder before providing genetic counselling.

We are very grateful to Dr William Nyham of the Department of Pediatrics, School of Medicine, University of California, San Diego, and to Dr L Stefan Levin of the Department of Otolaryngology, Johns Hopkins Hospital, Baltimore, for their editorial advice.

JOSE MARIA SANCHEZ AND  
TERESA CIACCI DE NEGROTTI  
*Fundacion de Genetica Humana,  
Salta 661/667, Buenos Aires 1074, Argentina*

## References

- 1 Pfeiffer RA. Dominant Erbliche Akrocephalosyndactylie. *Z Kinderheilkd* 1964;**90**:301-20.
- 2 Cohen MM. An etiologic and nosology overview of craniosynostosis syndromes. *Birth Defects* 1975;**11**, No 2:137-89.
- 3 Jackson CE, Weiss L, Reynolds WA, Forman TR, Peterson JA. Craniosynostosis, midfacial hypoplasia and foot abnormalities: an autosomal dominant phenotype in a large Amish kindred. *J Pediatr* 1976;**88**:963-8.
- 4 Escobar V, Bixler D. On the classification of the acrocephalosyndactyly syndromes. *Clin Genet* 1977;**12**:169-78.
- 5 Escobar V, Bixler D. The acrocephalosyndactyly syndromes: a metacarpophalangeal pattern profile analysis. *Clin Genet* 1977;**11**:295-305.
- 6 Blank CE. Apert's syndrome (a type of acrocephalosyndactyly): observations on a British series of thirty-nine cases. *Ann Hum Genet* 1960;**24**:151-64.

Requests for reprints to Dr J M Sanchez, Fundacion de Genetica Humana, Salta 661/667, Buenos Aires 1074, Argentina.